

## Incidental Ignition of a Pulsed Dye Laser Fiber During Laryngomicrosurgery : A Case Report

*Department of Otorhinolaryngology, Gangnam Severance Hospital, Yonsei University College of Medicine, Seoul, Korea*

**Yun Suk Suh, Eun Jung Lee, Min Ki Kim and Hong-Shik Choi**

### = Abstract =

Surgical fires require an ignition source, oxidizer, and fuel. The pulsed dye laser (PDL) has been shown to be effective in the treatment of hypertrophic scars and keloids in dermatology. With the increasing number of applications of CO<sub>2</sub> laser as ignition source has been associated with operating room fires in the otorhinolaryngologic field. There have been many case reports on PDL-induced fires in dermatology, but until now, there were no reports in the larynx. We describe a 57-year-old patient diagnosed with laryngeal hyperkeratosis treated by PDL-assisted laryngomicrosurgery. In this case, we experienced incidental PDL tip flaring during pulsed dye laser vaporization.

**KEY WORDS** : Lasers · Larynx · Microsurgery · Fires.

### Introduction

Operating room fires are a rare, but preventable danger in modern operating rooms, and can be life threatening. Operating room fires can occur due to problems with either the surgical team or the anesthesia team. Currently, there are a few published reports of incidental fire cases in operating rooms,<sup>1-3)</sup> including some associated with skin treatment using pulsed dye lasers (PDL) in the dermatology department.<sup>4-6)</sup> But the incidental firing by a pulsed dye laser during laryngeal surgery has not been reported. To our knowledge, this is the first fire case caused by a PDL when operating on the larynx in the literature.

### Case Report

A 57-year-old man was referred to our department in August 2010 for progressive voice changes with a breathy sound lasting 1 month. He had a history of diabetes mellitus with no smoking history, and no history of previous voice problems or voice abuse. Videolaryngostroboscopic examination showed the presence of a hyperkeratotic lesion on the mid-

portion of the true vocal fold surrounded by vascular ectasia. The patient was performed PDL-assisted laryngomicrosurgery under general anesthesia and the pathology report showed hyperkeratosis without evidence of malignancy. During regular follow-up, the patient complained of voice changes again, and videolaryngostroboscopic examination revealed hyperkeratotic changes on the right true vocal fold (Fig. 1A, B). The hyperkeratotic lesion had an irregular surface and glottis gap on contact. We planned a PDL-assisted laryngomicrosurgery to perform PDL vocal cord stripping. The endotracheal laser tube #6.0 was used via orotracheal intubation. General anesthesia was done using oxygen (FiO<sub>2</sub>=0.5 mmHg), air, remifentanyl and sevoflurane. The stripping of the hyperkeratotic lesion using a CO<sub>2</sub> laser was performed successfully. After treatment of the main lesion, sulcus vocalis was observed on the counter portion of the main lesion because of repetitive stimulus of the vocal cord during phonation (Fig. 2A). When the PDL switch was turn on near the vocal cord, the PDL tip burst into flames suddenly, but the flames went out spontaneously after a while (Fig. 2B). Fortunately, the tip flame did not develop a fire. After applying the PDL to the counter-portion of the vocal cord to create a smooth vocal cord margin, we finished the operation.

**Received:** November 20, 2015 / **Accepted:** November 27, 2015

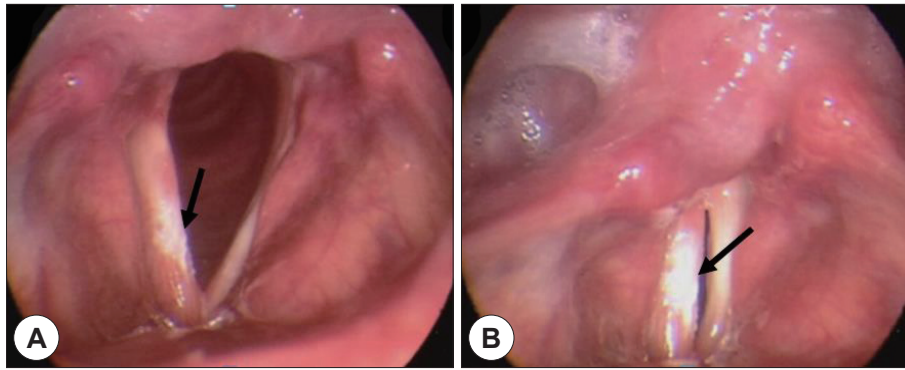
**Address for correspondence:** Hong-Shik Choi, MD, PhD, Department of Otorhinolaryngology, Gangnam Severance Hospital, Yonsei University College of Medicine, 211 Eonju-ro, Gangnam-gu, Seoul 06273, Korea

Tel: +82-2-2019-3463, Fax: +82-2-3463-4750


E-mail: hschoi@yuhs.ac

### Discussion

Researchers estimate that surgical fires occur between



**Fig. 1.** Preoperative videolaryngogastrostoscopic examination. videolaryngeal stroboscopy shows irregular hyperkeratotic lesion including right true vocal fold and left sulcus vocalis. No other abnormality was noted in larynx (Arrow : Hyperkeratotic lesion) (A : Resting, B : Phonation).



**Fig. 2.** Incidental firing of the tip of pulsed dye laser. When approaching pulsed dye laser to sulcus vocalis lesion, incidental firing of the tip of pulsed dye laser was occurred. After extinguishing fire spontaneously, removal of pulsed dye laser tip was done immediately. Firing was only occurred around the tip of pulsed dye laser. (A : Applying the PDL fiber, B : After the occurrence of the incidental firing).

550 and 650 times in the United States annually.<sup>7)</sup> Recently, anesthesiologists reviewed operating room fires and reported 103 operating room fire claims (1.9% of 5,297 surgical claims).<sup>8)</sup> Almost all operating room fires were reported by the anesthesiology department. Although some operating room fire case reports were reported by clinical departments, accurate frequencies of operating room fires have not been reported in the literature because of legal problems related to these reports.

Fires require the presence of three components, known as the “fire triad”, including an oxidizer, an ignition source, and fuel.<sup>1-3)</sup> The anesthesiology department uses oxygen or inhalation gases for anesthesia or sedation. These agents increase the chance of combustion in a dose-dependent manner.<sup>8)</sup> Replacing combustible anesthetic agents certainly make surgery safer and also reduce the potential risk of operating room fires. Electro-cauterization for bleeding control can be an ignition source, and endotracheal tubes can be a fuel source.<sup>7,9)</sup> In this case, the anesthetic components consisted of oxygen, air, remifentanyl and sevoflurane. Among them, sevoflurane with heat produced up to 3 moles of hydrogen which could easily ignited spontaneously.<sup>10)</sup> Therefore, the sevoflurane as the anesthetic component have a possibility to be the fuel source.

The 585-nm pulsed dye laser is the treatment of choice for many dermatologic vascular lesions such as port-wine

stains, initial hemangiomas, and facial telangiectasias.<sup>11-13)</sup> In addition to dermatology, lasers have begun to be used in laryngeal surgery, especially with the development and emergence of various lasers. The 585-nm pulsed dye laser was designed to target the oxyhemoglobin chromophore. By coinciding with the absorption band of oxyhemoglobin, the pulsed dye laser allows selective vascular uptake of laser energy with brief pulse duration. Anderson and Parrish developed the concept of selective photothermolysis in the treatment of dermatologic vascular malformations, which led to the 585-nm PDL.<sup>13)</sup> In “photothermolysis” laser energy is converted to heat, which results in selective destruction of dermal blood vessels and removal of cutaneous markings and minimizes surrounding tissue damage. In the past, pulsed dye laser-induced dermal fires occurred with the use of oxygen via face mask or nasal cannula.<sup>4-6)</sup> in the case of dermal fires, the use of oxygen is the oxidizer, the PDL is the ignition source, and the dermis is the fuel.

The utilization of the PDL in laryngeal surgery is on the rise, yet an incidental fire during pulsed dye laser surgery of the larynx has not been reported until now. In this case, PDL tip flaring occurred temporarily in the process of a PDL-assisted LMS. The PDL laser played the role of the ignition source, especially the PDL fiber sheath was the fuel. And vocal cord mucosa also could be the fuel but was not burned in this case because the flame around the PDL fiber sheath

was extinguished quickly.

While the time from ignition to extinguishment was very short in this case, the occurrence of fires could be explained in the process of photothermolysis with a PDL. Also, the increased partial pressure of oxygen also had a partial effect on the occurrence of the flame. When the fire occurs on PDL fiber, we have to remove the PDL fiber immediately. And then, we try to cool down the adjacent tissue with wet cotton to minimize dermal damage to tissue. Above all, there is little change of firing that we maintain a few oxygen conditions.

Laser use and applications have broadened; however, lasers can cause adjacent tissue damage and increase the risk of incidental fires. Furthermore, due to the vascular specificity of PDL, unlike CO<sub>2</sub> lasers, the use of PDL must be carefully considered.

## Conclusion

To minimize the risk of operating room fires, surgeons and anesthesiologists must familiarize themselves with the associated risk factors. Because PDL applications in laryngeal surgery have broadened, the prevention of operating room fires should be strongly considered during all procedures using PDLs.

## REFERENCES

- 1) Rapp C, Gaines R. *Fire in the operating room: A previously unreported ignition source. Am J Orthop* 2012;41(8):378-9.
- 2) Macdonald AG. *A brief historical review of non-anaesthetic causes of fires and explosions in the operating room. Br J Anaesth* 1994;73(6):847-56.
- 3) Kaddoum RN, Chidiac EJ, Zestos MM, Ahmed Z. *Electrocautery-induced fire during adenotonsillectomy: report of two cases. J Clin Anesth* 2006;18(2):129-31.
- 4) White JM, Siegfried E, Boulden M, Padda G. *Possible hazards of cryogen use with pulsed dye laser. A case report and summary. Dermatol Surg* 1999;25(3):250-3.
- 5) Fretzin S, Beeson WH, Hanke CW. *Ignition potential of the 585-nm pulsed-dye laser. Review of the literature and safety recommendations. Dermatol Surg* 1996;22(8):699-702.
- 6) Waldorf HA, Kauvar NB, Geronemus RG, Leffel DJ. *Remote fire with the pulsed dye laser: risk and prevention. J Am Acad Dermatol* 1996;34(3):503-6.
- 7) Smith LP, Roy S. *Operating room fires in otolaryngology: risk factors and prevention. Am J Otolaryngol* 2011;32(2):109-14.
- 8) Mehta SP, Bhananker SM, Posner KL, Domino KB. *Operating Room Fires: A Closed Claims Analysis. Anesthesiology* 2013;118(5):1133-9.
- 9) Hart SR, Yajnik A, Ashford J, Springer R, Harvey S. *Operating room fire safety. Ochsner J* 2011;11(1):37-42.
- 10) Marchall BD, Lynn EB, Shahbaz RA, Yanina S, Harvey JW. *Sevoflurane breakdown produces flammable concentrations of hydrogen. Anesthesiology* 2007;106:144-8.
- 11) Alster TS, Nanni CA. *Pulsed dye laser treatment of hypertrophic burn scars. Plast Reconstr Surg* 1998;102(6):2190-5.
- 12) Parrett BM, Donelan MB. *Pulsed dye laser in burn scars: Current concepts and future directions. Burns* 2010;36(4):443-9.
- 13) Brewin MP, Lister TS. *Prevention or treatment of hypertrophic burn scarring: A review of when and how to treat with the Pulsed Dye Laser. Burns* 2014;40(5):797-804.