

Clinical Article

A Morphometric Study of the Obturator Nerve around the Obturator Foramen

Se Yeong Jo, M.D., Jae Chil Chang, M.D., Ph.D., Hack Gun Bae, M.D., Ph.D., Jae-Sang Oh, M.D., Juneyoung Heo, M.D., Jae Chan Hwang, M.D.
Department of Neurosurgery, Soonchunhyang University Gumi Hospital, Gumi, Korea

Objective : Obturator neuropathy is a rare condition. Many neurosurgeons are unfamiliar with the obturator nerve anatomy. The purpose of this study was to define obturator nerve landmarks around the obturator foramen.

Methods : Fourteen cadavers were studied bilaterally to measure the distances from the nerve root to relevant anatomical landmarks near the obturator nerve, including the anterior superior iliac spine (ASIS), the pubic tubercle, the inguinal ligament, the femoral artery, and the adductor longus.

Results : The obturator nerve exits the obturator foramen and travels infero-medially between the adductors longus and brevis. The median distances from the obturator nerve exit zone (ONEZ) to the ASIS and pubic tubercle were 114 mm and 30 mm, respectively. The median horizontal and vertical distances between the pubic tubercle and the ONEZ were 17 mm and 27 mm, respectively. The shortest median distance from the ONEZ to the inguinal ligament was 19 mm. The median inguinal ligament lengths from the ASIS and the median pubic tubercle to the shortest point were 103 mm and 24 mm, respectively. The median obturator nerve lengths between the ONEZ and the adductor longus and femoral artery were 41 mm and 28 mm, respectively.

Conclusion : The obturator nerve exits the foramen 17 mm and 27 mm on the horizontal and sagittal planes, respectively, from the pubic tubercle below the pectineus muscle. The shallowest area is approximately one-fifth medially from the inguinal ligament. This study will help improve the accuracy of obturator nerve surgeries to better establish therapeutic plans and decrease complications.

Key Words : Obturator nerve · Obturator foramen · Morphometric study.

INTRODUCTION

The obturator nerve arises from the anterior division of the ventral rami of the second, third, and fourth lumbar nerves in the lumbar plexus. The branch originating from the third lumbar nerve is the largest and is distributed in the skin of the adductor muscles and thigh. It descends through the psoas major muscle forming a bundle, and enters the thigh through the upper part of the obturator foramen along the inner wall of the lesser pelvis, accompanied by the obturator artery. The obturator nerve then divides into anterior and posterior branches. The anterior branch is responsible for the sensory innervation of the hip joint and mid-thigh, as well as for the motor innervation of the superficial adductor muscles. The posterior branch provides sensory perception to the skin on the posterior side of the knee joints and motor function to the deep adductor muscles^{2,6)}.

Obturator neuropathy (obturator nerve entrapment syndrome) is caused by pressure or injury to the obturator nerve

on the upper part of the obturator foramen, which presents as pain or loss of sensation over the upper medial thigh with or without hip adduction weakness⁹⁾. If untreated, hip adductor weakness will result in a functional disorder of the hip joint¹⁴⁾. The majority of obturator neuropathy cases result from trauma, iatrogenic injuries such as orthopedic surgery (hip arthroplasty, urologic surgery, and spine surgery via the retroperitoneal cavity), sports hernias, and gynecological problems such as ectopic pregnancies^{1,12,17)}. Moreover, obturator neuropathy may also be associated with compressive lesions such as cysts, neurofibroma, and lipoma^{7,8)}.

Diagnosing and treatment of obturator neuropathy is difficult, as it is a rare condition with which many neurosurgeons are unfamiliar. Knowledge of the obturator nerve anatomy is essential for adequate surgical planning and success. With an aim to improve the accuracy of diagnosis and to prevent complications, we performed a cadaveric morphometric study to investigate the anatomical features and relationships between

• Received : November 8, 2015 • Revised : November 11, 2015 • Accepted : February 26, 2016

• Address for reprints : Jae Chan Hwang, M.D.

Department of Neurosurgery, Soonchunhyang University Gumi Hospital, 179 1Gongdan-ro, Gumi 39371, Korea
Tel : +82-2-709-9268, Fax : +82-2-792-5976, E-mail : s90846@schmc.ac.kr

• This is an Open Access article distributed under the terms of the Creative Commons Attribution Non-Commercial License (<http://creativecommons.org/licenses/by-nc/3.0>) which permits unrestricted non-commercial use, distribution, and reproduction in any medium, provided the original work is properly cited.

the obturator nerve and its surrounding anatomical landmarks.

MATERIALS AND METHODS

Twenty-eight lower limbs from fourteen (12 males and 2 females) adult cadavers with an age range of 25–95 years (mean, 61.6 years) were dissected. The cadavers were fixed with a mix-

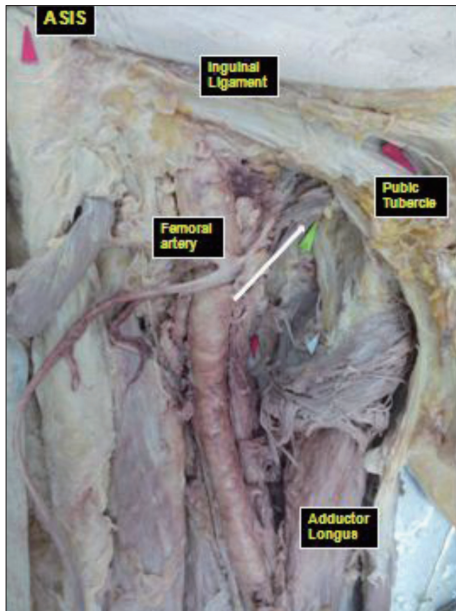


Fig. 1. Photograph of a cadaver specimen showing an anteroposterior view of the right thigh soft tissue dissection. The obturator nerve exit zone of the foramen (white arrow) was exposed after the pectineus muscle was dissected.

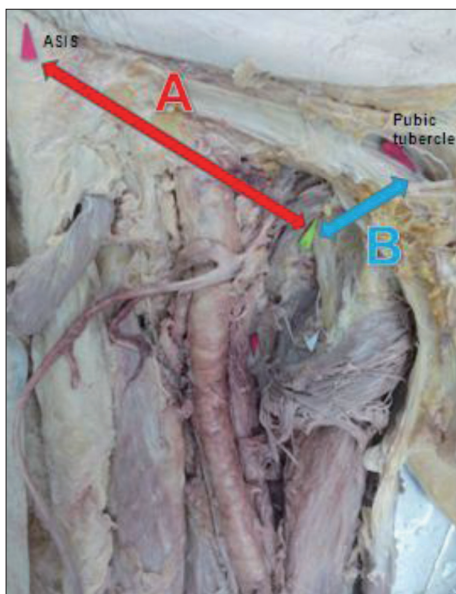


Fig. 2. Photograph of a cadaver specimen showing an anteroposterior view of the right thigh between the ASIS, the pubic tubercle, and the obturator nerve exit zone of the foramen after soft tissue dissection. A : the distance from the ASIS to the obturator nerve exit zone of the foramen, B : the distance from the pubic tubercle to the obturator nerve exit zone of the foramen. ASIS : anterior superior iliac spine.

ture of formalin, phenol, alcohol, and glycerin.

The skin was removed in the supine position to expose the pectineus muscle by carefully detaching the soft tissue from the fascia lata and the femoral artery. After the pectineus muscle was dissected, the obturator nerve was identified within the fascial layer (Fig. 1). Other adjacent tissues were left intact. Anatomically important structures used in this study include the anterior superior iliac spine (ASIS), the pubic tubercle, the inguinal ligament, the femoral artery, and the adductor longus. Different variables were measured in 28 specimens of 14 cadavers, as follows :

Point A : the distance from the ASIS to the obturator nerve exit zone of the foramen, and point B : the distance from the pubic tubercle to the obturator nerve exit zone of the foramen (Fig. 2); point C : the horizontal distance from the pubic tubercle to the obturator nerve exit zone of the foramen, and point D : the vertical distance from the pubic tubercle to the obturator nerve exit zone of the foramen (Fig. 3); point E : the shortest distance from the inguinal ligament to the obturator nerve exit zone of the foramen, point F : the length of the inguinal ligament from the ASIS to point E, point G : the length of the inguinal ligament from the pubic tubercle to point E (Fig. 4), point H : the length of the obturator nerve exposed between the obturator nerve exit zone of the foramen and the adductor longus, and point I : the shortest distance from the obturator nerve exit zone of the foramen to the femoral artery (Fig. 5).

Distances and lengths between the obturator nerve exit zone of the foramen and anatomical landmarks were measured using a standard meter and a goniometer. Measurements were made by one expert to minimize any errors.

All data were analyzed using SPSS analytical software version

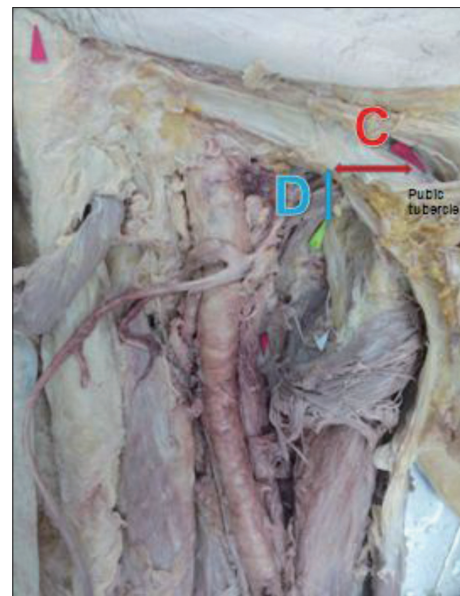


Fig. 3. Photograph of a cadaver specimen showing an anteroposterior view of the right thigh between the pubic tubercle and the obturator nerve exit zone of the foramen after soft tissue dissection. C : the horizontal distance, D : the vertical distance.

20.0 (SPSS Inc., Chicago, IL, USA) to examine the significance of different variables. All numerical parameters were compared using t-tests and cross tabulation. A level of $p < 0.05$ was considered statistically significant for all analyses.

RESULTS

Overall anatomical structure near the obturator foramen

After exiting the obturator foramen, the obturator nerve passes below the inguinal ligament and traverses the medial side of the femoral artery. To expose the obturator nerve in the supine position, it is important that the pectineus muscle is

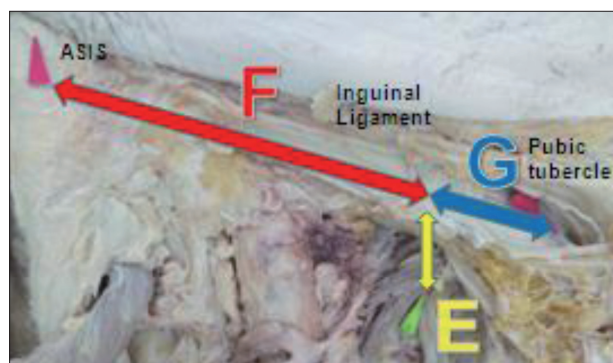


Fig. 4. Photograph of a cadaver specimen showing an anteroposterior view of the right thigh between the inguinal ligament and the obturator nerve exit zone of the foramen after soft tissue dissection. E : the shortest distance from the obturator nerve exit zone of the foramen to the inguinal ligament, F : the inguinal ligament length from the ASIS to point E, G : the inguinal ligament length from the pubic tubercle to point E. ASIS : anterior superior iliac spine.

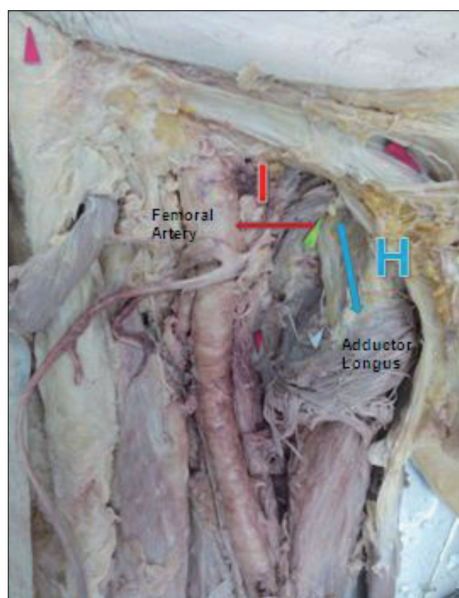


Fig. 5. Photograph of a cadaver specimen showing an anteroposterior view of the right thigh between the femoral artery and the obturator nerve exit zone of the foramen after soft tissue dissection. H : the obturator nerve length was exposed between the obturator nerve exit zone of the foramen and the adductor longus, I : the shortest distance from the obturator nerve exit zone of the foramen to the femoral artery.

identified following removal of the fascia lata and soft tissue. The obturator nerve is located beneath the pectineus muscle and runs medially and downwards between the adductor longus and adductor brevis muscles.

Distance and relationship between the ASIS/pubic tubercle and the obturator nerve

Table 1 shows the distance from the ASIS/pubic tubercle to the obturator nerve, while Table 2 shows the vertical and horizontal relationships between the obturator nerve and the pubic tubercle. The mean distance from the ASIS to the obturator nerve exit zone of the foramen was 113.4 ± 6.5 mm in the right thigh and 114.2 ± 7.4 mm in the left thigh. The mean distance from the pubic tubercle to the obturator nerve exit zone was 30.5 ± 4.4 mm in the right thigh and 30.3 ± 5.4 mm in the left thigh. The mean horizontal and vertical distances from the pubic tubercle to the obturator nerve exit were 18.2 ± 3.2 mm in the right thigh and 16.5 ± 3.0 mm in the left thigh, and 27.3 ± 2.2 mm in the right thigh and 26.3 ± 4.2 mm in the left thigh, respective-

Table 1. Variables measured between the obturator nerve exit zone of the foramen and various anatomical landmarks in 28 specimens from 14 cadavers

Parameter	Distance (mm) (mean±SD)		p-value
	Rt.	Lt.	
A	113.4±6.5	114.2±7.4	0.91
B	30.5±4.4	30.3±5.4	0.80
C	18.2±3.2	16.5±3.0	0.39
D	27.3±2.2	26.3±4.2	0.42

A : The distance from the anterior superior iliac spine to the obturator nerve exit zone of the foramen, B : The distance from the pubic tubercle to the obturator nerve exit zone of the foramen, C : The horizontal distance between the pubic tubercle and the obturator nerve exit zone of the foramen, D : The vertical distance between the pubic tubercle and the obturator nerve exit zone of the foramen

Table 2. Variables measured between the obturator nerve exit zone of the foramen and the inguinal ligament in 28 specimens from 14 cadavers

Parameter	Distance (mm) (mean±SD)		p-value
	Rt.	Lt.	
E	18.5±3.2	19.7±5.2	0.31
F	106.2±4.2	99.6±7.7	0.24
G	24.9±5.1	23.7±4.1	0.53
F/F+G	0.811	0.808	0.03

E : The shortest distance from the inguinal ligament to the obturator nerve exit zone of the foramen, F : The length of the inguinal ligament from the anterior superior iliac spine to point E, G : The length of the inguinal ligament from the pubic tubercle to point E

Table 3. Distance between the obturator nerve and the femoral artery and the length of the exposed obturator nerve in 28 specimens from 14 cadavers

Parameter	Rt. (mean±SD)	Lt. (mean±SD)	p-value
H	41.2±6.9	41.0±3.8	0.19
I	30.0±5.4	25.8±3.9	0.27

H : The obturator nerve length exposed between the obturator foramen nerve exit zone of the foramen and the adductor longus, I : The shortest distance from the obturator nerve exit zone of the foramen and the femoral artery

ly. No statistically significant differences between the measurements obtained from the right and left thighs were obtained.

Distance and relationship between the obturator nerve and the inguinal ligament

The shortest distance (point E) between the obturator nerve and the inguinal ligament as well as the relationship and distance between the inguinal ligament and the ASIS/pubis tubercle and point E are shown in Table 3. The shortest mean distance between the obturator nerve and the inguinal ligament was 18.5 ± 3.2 mm in the right thigh and 19.7 ± 5.2 mm in the left thigh. The mean length of the inguinal ligament from the ASIS to point E was 106 ± 4.2 mm in the right thigh and 99.6 ± 7.7 mm in the left thigh, while the mean length of the inguinal ligament from the pubic tubercle to point E was 24.9 ± 5.1 mm in the right thigh and 23.7 ± 4.1 mm in the left thigh. When the measurements between the ASIS and the pubic tubercle were compared based on point E from the inguinal ligament to the obturator nerve exit zone, the shallowest point of the obturator nerve was distributed approximately one-fifth from the medial inguinal ligament. No statistically significant differences between the measurements obtained from the right and left thighs were obtained.

Distance between the obturator nerve and the femoral artery, and length of the exposed obturator nerve

Table 3 shows the shortest distance between the obturator artery and the femoral artery, as well as the length of the obturator nerve exposed between the obturator foramen and the adductor longus. The mean length of the obturator nerve exposed between the obturator foramen and the adductor longus was 41.2 ± 6.9 mm in the right thigh and 41.0 ± 3.8 mm in the left thigh. The shortest mean distance between the femoral artery and the obturator nerve exit zone was 30.0 ± 5.4 mm in the right thigh and 25.8 ± 3.9 mm in the left thigh. No statistically significant differences between the measurements obtained from the right and left thighs were obtained.

DISCUSSION

Obturator nerve injuries are a direct result of nerve sectioning, stretching, crushing, electrocoagulating, or ligating. Identifying an isolated obturator nerve lesion can be difficult based on history and physical examination alone, because other nerve injuries in the lower abdomen and pelvic region also present with groin and thigh pain.

Magnetic resonance imaging (MRI) is helpful to detect atrophy of the adductor brevis and adductor longus muscles and to identify the anatomical structures of the inguinal and surrounding areas¹⁶. Electromyography is the gold standard used for obturator neuropathy diagnosis. Longer fibrillation potentials, high amplitude, and complex exercise units in the adductor brevis and adductor longus muscles are observed in patients with obturator neuropathy; however, the iliopsoas and quadri-

ceps muscles of the lower limb do not reveal any abnormal findings. Thus, obturator neuropathy should be differentiated from lumbar plexopathy, diabetic polyneuropathy, and lumbar neuropathy.

Treatment for obturator neuropathy or related nerve injuries include medication, physical therapy, massage therapy, restricted exercise, and rehabilitation. Surgical procedures may be considered depending on the severity of the injury, recovery, and response to conservative therapy. Moreover, obturator nerve block can be an efficient treatment. Several authors have reported that obturator block is effective for the relief of pelvic and thigh pain, as well as for the management of adductor muscle spasticity caused by spinal cord injury, traumatic brain injury, stroke, cerebral palsy, and multiple sclerosis^{3,5,13,15}.

Several technical methods of obturator nerve block have been introduced. The pubic approach involves the insertion of a needle perpendicular to the skin, 15 mm lateral and 15 mm inferior to the tubercle, while in the inguinal approach, the needle is inserted at the midpoint of the inguinal crease between the femoral arterial pulse and the inner border of the adductor longus tendon⁴. In our study, the median distances between the obturator foramen and the pubic tubercle, the femoral artery, and the adductor longus muscle were 17 mm, 28 mm, and 41 mm, respectively. Regarding arterial variations and postural alterations, injection points are consistent with our results. Ultrasound guidance allows for better nerve identification, and recent studies utilizing this technique for obturator nerve block have reported success rates of greater than 90%. While ultrasound guidance can be useful for diagnosis, its usefulness is limited in cases of surgical exploration.

Previous studies have investigated the anatomical features of the obturator nerve. According to Locher et al.¹¹, the median distances between the projection of the obturator nerve on the skin to the pubic tubercle and to the symphysis were 23 mm and 51 mm, respectively, based on anatomical investigation and MRI analysis of 10 cadavers. A similar value of 27 mm was obtained as the median distance between the obturator nerve and the pubic tubercle in our study. The pubic tubercle is an objective landmark and can be useful for understanding anatomical structures.

Understanding the relationships between various anatomical structures is essential for surgery. Different critical sites that risk compressing the obturator nerve include the obturator canal, the obturator membrane, and the obturator externus muscle¹⁰. Many options exist for the surgical treatment of obturator neuropathy, including transabdominal, laparoscopic, inguinal, and extraperitoneal approaches⁹. During surgical exploration, critical structures such as the femoral artery can be dissected. Anatomical apprehension of the obturator nerve can be of aid for the accurate planning and appropriate timing of surgery. The incision can be made at inguinal crease, point approximately one-fifth medially from the ASIS to the pubic tubercle and the medial inguinal ligament can be a good surface landmark of the

obturator nerve. Then, the nerve is traced proximally by dissecting to the obturator foramen. Most of obturator nerves are located in a triangle bordered by femoral artery, adductor longus muscle and inguinal ligament. So neurosurgeons should understand the anatomical relationship and the projection of the obturator nerve for saving adjacent structure.

CONCLUSION

The results of our morphometric study show that the obturator nerve is located beneath the pectineus muscle, at a distance of approximately 1.7 cm and 2.7 cm vertically and horizontally, respectively, from the pubic tubercle. Moreover, the shallowest portion of the obturator nerve is distributed approximately one-fifth from the medial inguinal ligament. The limitations of this study include its small sample size and the use of only two female cadavers. Thus, our report cannot be commonly cited to all subjects of both sexes. In addition, the supine position of cadavers may have affected the results of our study. However, knowledge concerning obturator neuropathy provided by this study will aid in more accurate diagnoses, active intervention programs, and for the minimization of complications.

• Acknowledgements

This work was supported by the Soonchunhyang University Research Fund.

References

- Ahmadian A, Abel N, Uribe JS : Functional recovery of severe obturator and femoral nerve injuries after lateral retroperitoneal transpsoas surgery. *J Neurosurg Spine* 18 : 409-414, 2013
- Anagnostopoulou S, Kostopanagiotou G, Paraskeuopoulos T, Chantzi C, Lolis E, Saranteas T : Anatomic variations of the obturator nerve in the inguinal region : implications in conventional and ultrasound regional anesthesia techniques. *Reg Anesth Pain Med* 34 : 33-39, 2009
- Choi EJ, Byun JM, Nahm FS, Lee PB : Obturator nerve block with botulinum toxin type B for patient with adductor thigh muscle spasm - a case report-. *Korean J Pain* 24 : 164-168, 2011
- Freisburger C, Nachtigall B, Wulf H : [Obturator nerve block]. *Anesthesiol Intensivmed Notfallmed Schmerzther* 45 : 314-315, 2010
- Ghai A, Sangwan SS, Hooda S, Kiran S, Garg N : Obturator neurolysis using 65% alcohol for adductor muscle spasticity. *Saudi J Anaesth* 6 : 282-284, 2012
- Hadley G : Essential clinical anatomy. *J Anat* 211 : 413, 2007
- Joniau SG, Van Baelen AA, Hsu CY, Van Poppel HP : Complications and functional results of surgery for locally advanced prostate cancer. *Adv Urol* 2012 : 706309, 2012
- Kim SH, Seok H, Lee SY, Park SW : Acetabular paralabral cyst as a rare cause of obturator neuropathy : a case report. *Ann Rehabil Med* 38 : 427-432, 2014
- Kitagawa R, Kim D, Reid N, Kline D : Surgical management of obturator nerve lesions. *Neurosurgery* 65 (4 Suppl) : A24-A28, 2009
- Kumka M : Critical sites of entrapment of the posterior division of the obturator nerve : anatomical considerations. *J Can Chiropr Assoc* 54 : 33-42, 2010
- Locher S, Burmeister H, Böhlen T, Eichenberger U, Stoupis C, Moriggl B, et al. : Obturator nerve block : a technique based on anatomical findings and MRI analysis. *Pain Med* 9 : 1012-1015, 2008
- McConaghie FA, Payne AP, Kinninmonth AW : The role of retraction in direct nerve injury in total hip replacement : an anatomical study. *Bone Joint Res* 3 : 212-216, 2014
- Park ES, Rha DW, Lee WC, Sim EG : The effect of obturator nerve block on hip lateralization in low functioning children with spastic cerebral palsy. *Yonsei Med J* 55 : 191-196, 2014
- Rigaud J, Labat JJ, Riant T, Bouchot O, Robert R : Obturator nerve entrapment : diagnosis and laparoscopic treatment : technical case report. *Neurosurgery* 61 : E175; discussion E175, 2007
- Stone J, Matchett G : Combined ultrasound and fluoroscopic guidance for radiofrequency ablation of the obturator nerve for intractable cancer-associated hip pain. *Pain Physician* 17 : E83-E87, 2014
- Tipton JS : Obturator neuropathy. *Curr Rev Musculoskelet Med* 1 : 234-237, 2008
- Zwolak P, Eysel P, William-Patrick Michael J : Femoral and obturator nerves palsy caused by pelvic cement extrusion after hip arthroplasty. *Orthop Rev (Pavia)* 3 : e6, 2011