

## Irritation Fibroma Associated with Ectopic Eruption of the Maxillary Incisor

Younwook Jeong<sup>1</sup>, Chungmin Kang<sup>1</sup>, Seunghye Kim<sup>2</sup>, Jaeho Lee<sup>1</sup>

<sup>1</sup>*Department of Pediatric Dentistry, College of Dentistry, Yonsei University*

<sup>2</sup>*Division of Pediatric Dentistry, Department of Dentistry, Ajou University School of Medicine*

### Abstract

Irritation fibroma is a common hyperplastic lesion of the oral mucosa that can occur in response to chronic irritation or trauma.

This report presents an unusual case of irritation fibroma associated with ectopic eruption of the maxillary left central incisor in a patient with Angelman syndrome. Considering the patient's medical history and cooperative ability, excisional biopsy under intramuscular sedation using midazolam was performed. The patient exhibited successful healing without lesion recurrence.

It is important to perform histopathological examination followed by excisional biopsy, because other benign or malignant tumors may mimic the clinical appearance of an irritation fibroma.

**Key words:** Irritation fibroma, Excisional biopsy, Intramuscular sedation, Midazolam, Angelman syndrome

### I . Introduction

Irritation fibroma is a common intraoral exophytic lesion of the oral cavity. Although it can occur anywhere within the oral cavity, the most common location is within the buccal mucosa along the bite line. The lateral border of the tongue, lips, gingiva and labial mucosa represent other common sites<sup>1</sup>.

Irritation fibroma can be caused by chronic irritation or trauma, including habitual lip and cheek biting, ill-fitting dentures and food impaction<sup>1,2</sup>. Furthermore, a correlation may exist between irritation fibroma and the human papilloma virus<sup>3</sup>.

Irritation fibroma lesions are localized and typically appear as dome-shaped or pedunculated nodules of the same color as the surrounding mucosa. The lesion surface may appear white as a result of hyperkeratosis due

to continued irritation. Lesion size varies from several millimeters to several centimeters in diameter. However, the majority of fibromas are 2.0 cm or less in diameter. These lesions are associated with no particular symptoms except a feeling of irritation, unless secondary traumatic ulceration of the surface has occurred<sup>4,5</sup>.

This report presents an unusual case of irritation fibroma that occurred in the labial mucosa, which was associated with ectopic eruption of the maxillary central incisor in a patient with Angelman syndrome.

### II . Case Report

A boy aged 7 years and 7 months presented to the Department of Pediatric Dentistry, Yonsei University Dental Hospital with a chief complaint of non-eruption of his front tooth. He had been diagnosed with

Corresponding author : Jaeho Lee

Department of Pediatric Dentistry, College of Dentistry, Yonsei University, 50-1, Yonsei-ro, Seodaemun-gu, Seoul, 03722, Korea

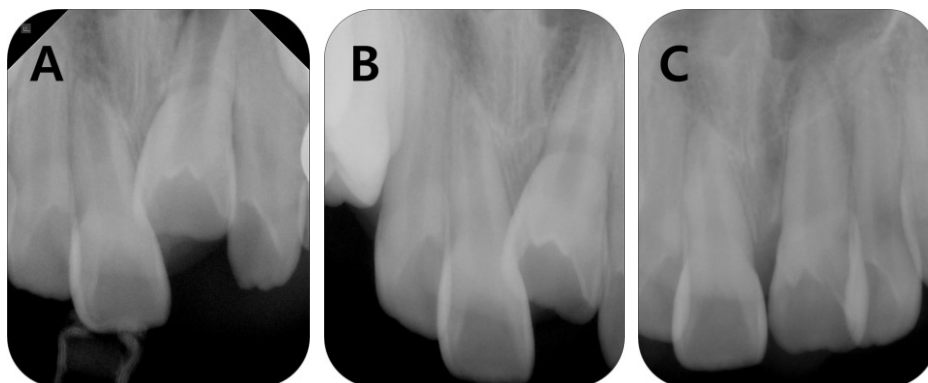
Tel: +82-2-2228-3173 / Fax: +82-2-392-7420 / E-mail: leejh@yuhs.ac

Received May 14, 2015 / Revised June 25, 2015 / Accepted June 23, 2015

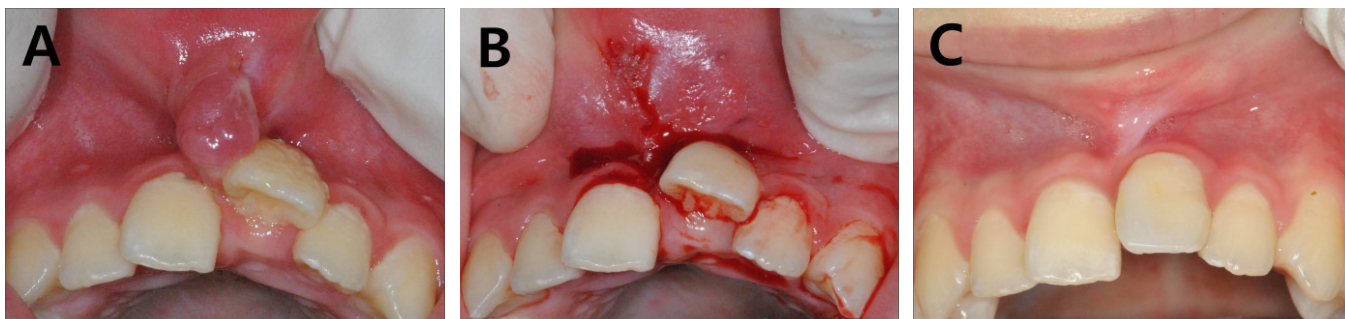Angelman syndrome and was taking anticonvulsive medication. Clinical and radiographic examination revealed delayed eruption of the maxillary left central incisor (Fig. 1A). The crown of the maxillary left central incisor was palpated at the vestibular area near the labial frenum. The patient revisited our dental hospital for follow-up at the age of 8 years and 11 months. Radiographic examination demonstrated that his maxillary left central incisor had erupted slightly (Fig. 1B). Swelling of the oral mucosa was observed around the palpated crown; ectopic eruption of the maxillary left central incisor was expected in the future. Eleven months after his second visit, at the age of 9 years and 10 months, the patient's parents brought him to our dental hospital because they had incidentally observed an unusual mass around the erupting tooth. The maxillary left central incisor was fully erupted, but it was ectopically erupted in the horizontal direction, toward the upper lip (Fig. 1C, Fig. 2A). The swelling of the oral

mucosa seen at the last visit became a pedunculated nodule measuring approximately 0.7 × 0.9 × 1.0 cm (Fig. 2A). The lesion was positioned between the labial frenum and mesial surface of the maxillary left central incisor. There was no pain on palpation, but bleeding readily occurred upon stimulation. The patient had difficulty in closing his mouth completely due to the enlarged mass (Fig. 3). Furthermore, heavy plaque was deposited on the labial surface of the maxillary left central incisor because the mass covered part of the crown. The patient's parents reported difficulty in brushing his front tooth.

Considering the patient's limited cooperative ability, excisional biopsy under intramuscular sedation using midazolam was planned. On the day of the operation, an intramuscular dose of 0.15 mg/kg of midazolam was administered into the upper outer quadrant of the gluteal area. Excisional biopsy was performed under local anesthesia (Fig. 2B). The mass was elevated with a hemostat and excised with 1 to 2 mm peripheral margins. The

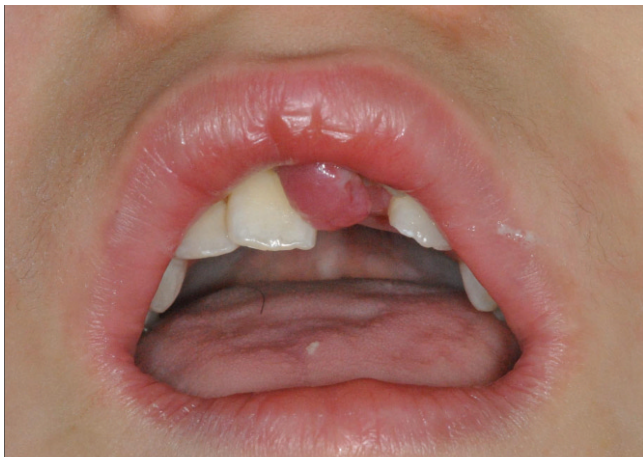

**Fig. 1.** Periapical radiographs of the patient. (A) Periapical radiograph showing delayed eruption of the maxillary left central incisor when the patient was aged 7 years and 7 months. (B) Periapical radiograph taken at 8 years and 11 months, showing that the maxillary left incisor had erupted slightly. (C) Periapical radiograph taken at 9 years and 10 months showing full eruption of the maxillary left central incisor.



**Fig. 2.** Intraoral photographs of the patient. (A) Intraoral photograph showing a pedunculated mass on the labial mucosa. (B) Intraoral photograph taken immediately after the excisional biopsy. (C) Intraoral photo taken at the 8-month check-up visit, showing improved oral hygiene status and spontaneous reduction of labial inclination of the maxillary left central incisor by the force of the upper lip and perioral muscles without recurrence of the lesion.

depth of the excision was at the level of the muscle fascia, such that the edges could be undermined for primary closure. The wound was closed with 4-0 sutures, and the biopsy specimen was immediately fixed in 10% formalin and sent for histological evaluation. Histological evaluation of the sections by light microscopy revealed a nodular mass of fibrous connective tissue covered by hyperparakeratinized stratified squamous epithelium (Fig. 4). The covering epithelium exhibited acanthosis with finger-like elongation of the rete ridges. Dense bundles of collagen fibers, arranged in a circular pattern with vascular hyperplasia and infiltration of inflammatory cells, were observed in the underlying connective tissue. On the basis of clinical and microscopic features, a final diagnosis of irritation fibroma was made.

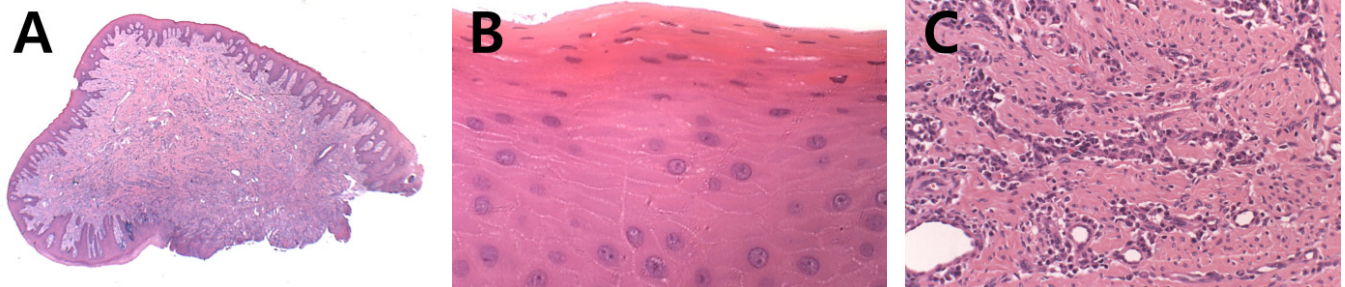


**Fig. 3.** Extraoral photograph showing an enlarged mass.

The patient was recalled for follow-ups and there were no signs of recurrence during the 8-month follow-up period (Fig. 2C). Furthermore, the amount of plaque deposited on the labial surface of the maxillary left central incisor decreased markedly commensurate with easier tooth brushing after removal of the mass. Finally, we observed that the labial inclination of the maxillary left central incisor improved spontaneously by the force of the upper lip and perioral muscles. Periodic follow-ups have been scheduled.

### III. Discussion

The patient described herein had Angelman syndrome, which is caused by a deletion on chromosome 15. The syndrome is characterized by delayed development, mental retardation, seizures, and movement or balance disorders<sup>6,7</sup>. The present patient was taking Topamax<sup>®</sup> (topiramate) to prevent seizures. Anticonvulsive drugs such as phenytoin, sodium valproate, phenobarbitone, and vigabatrin are known to be associated with gingival overgrowth<sup>8</sup>. The appearance of gingival overgrowth induced by anticonvulsants is generalized, and the marginal gingiva and interdental papilla appear to be the areas predisposed to enlargement<sup>9</sup>. However, with the introduction of a new generation of anticonvulsive drugs including topiramate, lamotrigine, gabapentin, and sulthiame, the possibility of gingival enlargement has been markedly reduced<sup>10</sup>. Therefore, it can be concluded that the irritation fibroma observed in this case was not associated with an anticonvulsive drug. Oral manifestations of Angelman syndrome include mandibular prog-



**Fig. 4.** Histopathological examination of the irritation fibroma. (A) Low-power view showing an exophytic unencapsulated mass of dense fibrous connective tissue. The covering epithelium exhibits acanthosis with finger-like elongation of rete ridges (H-E,  $\times 10$ ). (B) Hyperparakeratinized stratified squamous epithelium with residual nuclei of keratinocytes (H-E,  $\times 600$ ). (C) Dense bundles of collagen fibers arranged in a circular pattern with vascular hyperplasia and infiltration of inflammatory cells (H-E,  $\times 200$ ).

nathism, a wide mouth, diastema, and a habit of tongue thrusting<sup>11,12</sup>. However, delayed eruption or ectopic eruption of a tooth, as observed in this case, has not been reported previously.

Irritation fibroma is caused by reactive hyperplasia of fibrous connective tissue and is most common in the fourth to sixth decades of life. The male-to-female ratio is almost 1:2 among cases submitted for biopsy<sup>1,13,14</sup>, although several reports suggest no gender difference<sup>15,16</sup>. Bouquot and Gundlach<sup>15</sup> reported that of 1,453 oral exophytic lesions found among 23,616 white Americans over 35 years of age, the prevalence of irritation fibroma was 1.2%. Furthermore, irritation fibroma represented 74.5% of all fibrous exophytic lesions. Although there have been numerous epidemiologic studies on the occurrence of irritation fibroma, no studies have assessed this lesion in children and adolescents<sup>17</sup>.

It is doubtful that irritation fibroma represents a true neoplasm. True fibroma of the oral mucosa is characterized by an absence of obvious signs of chronic irritation, and sharp demarcation of the lesion from the surrounding tissues by a capsule. However, irritation fibroma occurs in response to local irritation or trauma and is not clearly demarcated from surrounding tissues<sup>18</sup>.

Rotaru *et al.*<sup>19</sup> suggested that TGF- $\alpha$  may play a key role in the fibroblastic proliferation of oral fibroma. Another study suggested that proliferation of fibroblasts and collagen synthesis, due to increased expression of TGF- $\beta$ 1 and imbalance in the expression of MMP-1 and TIMP-1, represent contributory factors to the pathogenesis of irritation fibroma<sup>20</sup>.

Previously, microscopic examination of irritation fibroma revealed a nodular mass of fibrous connective tissue covered by stratified squamous epithelium. The epithelium may exhibit hyperkeratosis or ulceration due to chronic irritation. Collagen bundles may be arranged in a radiating, circular, or haphazard fashion. Inflammatory cells, which typically comprise lymphocytes and plasma cells, are frequently observed beneath the epithelial surface<sup>1,2</sup>. As the lesion matures, inflammatory cells and blood vessels observed during the early stage are substituted by fibrous tissue: younger lesions are composed mainly of unpacked collagen, whereas older lesions contain packed, well-organized collagen<sup>21,22</sup>. In the present case, the epithelium was hyperparakeratinized due to chronic and continuous irritation by the ectopically erupting maxillary left central incisor. The epithelium was covered by parakeratin, which contains residual nu-

clei of keratinocytes. The collagen fibers of the connective tissue observed in this case were arranged in a circular pattern. Toida *et al.*<sup>23</sup> reported that collagen fibers were arranged in a circular pattern on mobile mucosa, whereas collagen fibers were arranged in a radiating pattern on fixed mucosa.

The differential diagnosis of irritation fibroma should include benign submucosal soft tissue tumors such as true fibroma, giant cell fibroma, peripheral giant cell granuloma, pyogenic granuloma, and lipoma.

Irritation fibroma should be treated by conservative surgical excision because the excessive collagen that characterizes this lesion is permanent and does not decrease spontaneously. Excisional biopsy represents the treatment of choice, and recurrence is extremely rare after removing the lesion and other causes of irritation<sup>1,2</sup>. In our case, because the labial inclination of the maxillary left central incisor improved spontaneously by the force of the upper lip and perioral muscles, it is unlikely that the lesion will recur in the future.

This case report is notable because the irritation fibroma occurred in the labial mucosa, which represents an uncommon location for this type of lesion; furthermore, it was associated with ectopic eruption of the incisor.

#### IV. Summary

Irritation fibroma is a reactive hyperplasia of fibrous connective tissue that occurs in response to local irritation or trauma and is characterized by proliferation of collagenous connective tissue and blood vessels. In the case described herein, irritation fibroma occurred in the labial mucosa associated with ectopic eruption of the maxillary left central incisor in a patient with Angelman syndrome. When soft tissue lesions occur in the oral cavity, identifying the causes and performing excisional biopsy are warranted to achieve a definitive diagnosis.

#### References

1. Neville BW, Damm DD, Bouquot JE, *et al.* : Oral and maxillofacial pathology, 3rd ed., Saunders, 507-552, 2009.
2. Sapp JP, Eversole LR, Wossocki GP : Contemporary oral and maxillofacial pathology, 2nd ed., Mosby, 164-206, 1997.
3. Gross GE, Pfister H, Mittermayer C : Papilloma virus particles in a fibroma of the tongue. *Acta Derm*

- Venereol*, 60:315-8, 1980.
4. Marx RE, Stern D : Oral and maxillofacial pathology: a rationale for diagnosis and treatment, 2nd ed., Quintessence Publishing Co, Inc., 399-466, 2012.
  5. Korean academy of orofacial pain and oral medicine (Ed.) : Oral medicine Vol. III, Shinhung International, Inc., 121-9, 2010.
  6. Pembrey M, Fennell SJ, Super M, *et al.* : The association of Angelman's syndrome with deletions within 15q11-13. *J Med Genet*, 26:73-7, 1989.
  7. Williams CA, Beaudet AL, Wagstaff J, *et al.* : Angelman syndrome 2005: updated consensus for diagnostic criteria. *Am J Med Genet A*, 140:413-8, 2006.
  8. Marshall RI, Bartold PM : A clinical review of drug-induced gingival overgrowths. *Aust Dent J*, 44:219-32, 1999.
  9. Thompson AL, Herman WW, Konzelman J, Collins MA : Treating patients with drug-induced gingival overgrowth. *J Dent Hyg*, 78:1-13, 2004.
  10. Prasad VN, Chawla HS, Singhi P, *et al.* : Folic acid and phenytoin induced gingival overgrowth-is there a preventive effect. *J Indian Soc Pedod Prev Dent*, 22:82-91, 2004.
  11. Murakami C, Nahas Pires Correa MS, Nahas Pires Correa JP, *et al.* : Dental treatment of children with Angelman syndrome: a case report. *Spec Care Dentist*, 28:8-11, 2008.
  12. Kim BS, Yeo JS, Kim SO : Anesthesia of a dental patient with Angelman syndrome-A case report-. *Korean J Anesthesiol*, 58:207-10, 2010.
  13. Bernick S : Growths of the gingiva and palate: chronic inflammatory lesions. *Oral Surg Oral Med Oral Pathol*, 1:1029-41, 1948.
  14. Maryam S, Mohammadtaghi H, Soodabeh B : Localized lesions of oral cavity: a clinicopathological study of 107 cases. *Research journal of medical sciences*, 5:67-72, 2011.
  15. Bouquot JE, Gundlach KK : Oral exophytic lesions in 23,616 white Americans over 35 years of age. *Oral Surg Oral Med Oral Pathol*, 62:284-91, 1986.
  16. Buchner A, Calderon S, Ramon Y : Localized hyperplastic lesions of the gingiva: a clinicopathological study of 302 lesions. *J Periodontol*, 48:101-4, 1977.
  17. Ntomouchtsis A, Karakinaris G, Antoniadis K, *et al.* : Benign lip lesions. A 10-year retrospective study. *Oral Maxillofac Surg*, 14:115-8, 2010.
  18. Christopoulos P, Sklavounou A, Patrikiou A : True fibroma of the oral mucosa: a case report. *Int J Oral Maxillofac Surg*, 23:98-9, 1994.
  19. Rotaru H, Choi JY, Kim SG, *et al.* : Transforming growth factor-alpha and oral fibroma: immunohistochemical and in situ hybridization study. *J Oral Maxillofac Surg*, 61:1449-54, 2003.
  20. Ryu MH, Kim BI, Kim J, *et al.* : Expression of TGF- $\beta$ 1, MMP-1 and TIMP-1 in irritation fibroma. *Kor J Oral Maxillofac Pathol*, 33:61-8, 2009.
  21. Dayan D, Bodner L, Wolman M, *et al.* : Histochemical characterization of collagen fibers in fibrous overgrowth (irritation fibroma) of the oral mucosa: effect of age and duration of lesion. *Arch Gerontol Geriatr*, 18:53-7, 1994.
  22. Mandel L, Baurmash H : Irritation fibroma. Report of a case. *NY State Dent J*, 36:344-7, 1970.
  23. Toida M, Murakami T, Tatematsu N, *et al.* : Irritation fibroma of the oral mucosa: a clinicopathological study of 129 lesions in 124 cases. *Oral Medicine and Pathology*, 6:91-4, 2001.

국문초록

## 상악 중절치의 이소맹출로 인해 발생한 자극성 섬유종

정연욱<sup>1</sup> · 강정민<sup>1</sup> · 김승혜<sup>2</sup> · 이제호<sup>1</sup>

<sup>1</sup>연세대학교 치과대학 소아치과학교실

<sup>2</sup>아주대학교병원 치과학교실 소아치과

자극성 섬유종은 만성적인 자극 또는 외상에 의해 발생하는 구강 내의 흔한 섬유증식성 병소이다. 자극성 섬유종과 유사한 형태의 다른 양성 또는 악성 연조직종양의 감별진단을 위해서는 병리조직학적 검사가 필요하다.

본 증례는 엔젤만 증후군 환자에서 상악 좌측 중절치의 이소맹출로 인해 자극성 섬유종이 발생하여 미다졸람을 이용한 근육내 진정 하에 절제생검을 시행한 뒤, 병소의 재발 없이 양호한 치유 결과를 나타내고 있기에 보고하는 바이다.

**주요어:** 자극성 섬유종, 절제생검, 근육내 진정, 미다졸람, 엔젤만 증후군