

## Rectal Injury Associated with Pelvic Fracture

Jihun Gwak, M.D., Min A Lee, M.D., Byungchul Yu, M.D., Kang Kook Choi, M.D.

*Department of Trauma Surgery, Gachon University Gil Medical Center, Incheon, Korea*

Rectal injury is seen in 1-2% of all pelvic fractures, and lower urinary tract injury occurs in up to 7%. These injuries are rare, but if missed, can lead to a severe septic response.

Rectal injury may be suspected by the presence of gross blood on digital rectal examination. However, this classic sign is not always present on physical examination. If an Antero-Posterior Compression type pelvic fracture is seen, we should consider the possibility of rectal and lower urinary tract injury. It is important to define the anatomic location of the rectal injury as it relates to the peritoneal reflection. Trauma to the intraperitoneal rectum should be managed as a colonic injury. Extraperitoneal rectal injury should be managed with fecal diversion regardless of primary repair.

We present the case of a 46-year-old man who was referred to our hospital following a major trauma to the pelvis in a pedestrian accident. [ J Trauma Inj 2016; 29: 201-203 ]

**Key Words:** Rectal injury, Extra-peritoneal, Pelvic fracture

### I. Introduction

Rectal injury is seen in 1-2% of pelvic fractures, and lower urinary tract injuries occur in up to 7%. (1-3) Rectal injury is rare, but if missed, can lead to a severe septic response. Rectal injury may be suspected by the presence of gross blood on digital rectal examination. However, this classic sign is not always present on physical examination. To share our experience, we present the case of a patient who was referred to our hospital following a major trauma to the pelvis in a pedestrian accident.

### II. Case Report

A 46-year old man was referred to our hospital after being sandwiched between trucks in an Antero-Posterior direction on his pelvis and lower abdomen.

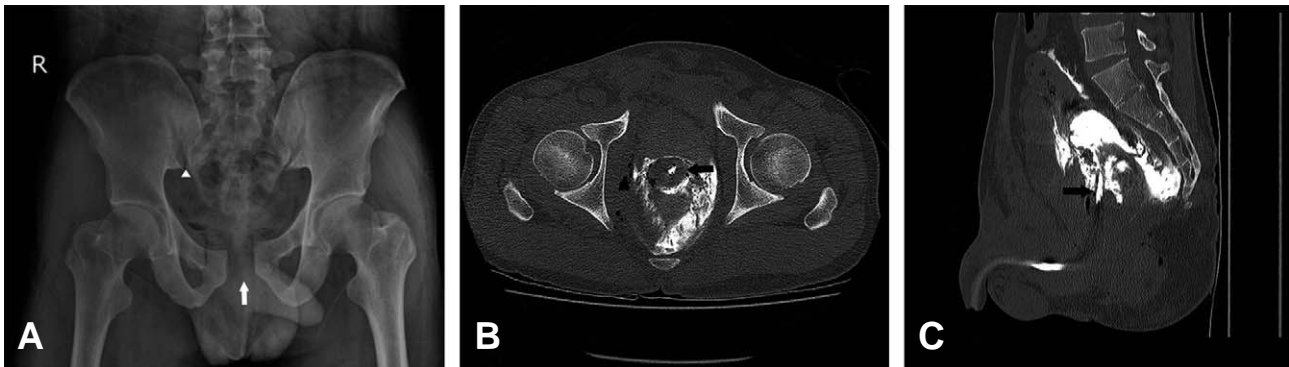
On arrival, his pulse was 79 beats per minute and blood pressure 105/67 mm Hg. There was no free fluid detected on a FAST-scan. A CT scan taken at a previous hospital showed Antero-Posterior Compression (APC) type II pelvic fracture with urethra and rectal injury (Fig. 1). A Foley catheter was placed between the bladder and rectum using a CT scan. Multifocal air-density and hematoma, contrast were seen around the rectum (Fig. 2). On rectal examination, fresh blood and a tear in the direction of 9 to 12 o'clock were detected. A urologist tried to reinsert the Foley catheter but failed. The patient was emergently taken to the surgical theater after undergoing vesicostomy and underwent a laparotomy. There was no intraperitoneal visceral injury or solid organ injury. Loop sigmoidostomy was performed for proximal diversion. After laparotomy, an external fixator was applied to stabilize the pelvic ring. The patient recovered well and

\* Address for Correspondence : **Kang Kook Choi, M.D.**

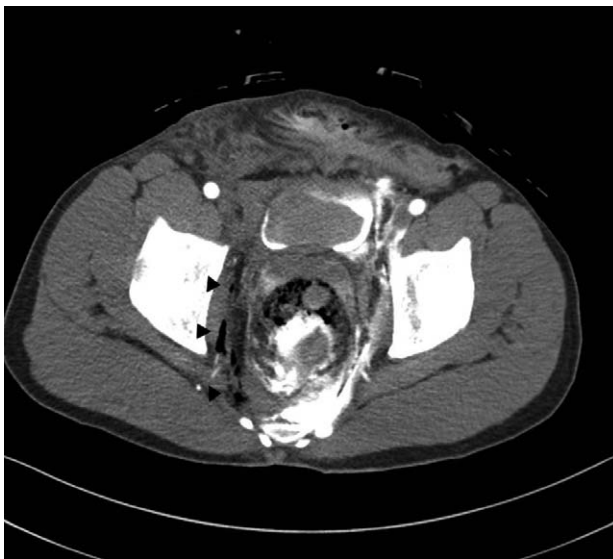Department of Trauma Surgery, Gachon University Gil Medical Center,  
783, Namdong-daero, Namdong-gu, Incheon 21556, Korea

Tel : 82-32-460-3010, Fax : 82-32-460-2372, E-mail : choikangkook@gilhospital.com

**Submitted** : December 5, 2016 **Revised** : December 10, 2016 **Accepted** : February 17, 2017



**Fig. 1.** (A) Pelvis AP scan shows widening of symphysis pubis (white arrow) and SI joint(white arrowhead). (B) Foley catheter (black arrow) was detected between bladder and rectum on pelvic CT scan. (C) Sagittal view of pelvic CT scan. foley catheter (black arrow) was seen from posterior outside of bladder.



**Fig. 2.** Multifocal air densities (black arrowhead) and hematomas around rectum were detected on abdomen CT scan. Perirectal contrast was infused through foley catheter at previous hospital.

transferred to a secondary care hospital near his home after two weeks.

### III. Discussion

Aihara et al.(2) reported that widening of the pubic symphysis is a sensitive indicator of rectal injury and lower urinary tract injury. The positive predictive value is as low as 15% to 20%, but it is necessary to examine carefully for associated injury while considering the serious consequences of missed injury. Approximately 75% of all patients with rectal injury, 72% with bladder injury, and 85% with urethral injury

had an APC mechanism.(2) If an APC type pelvic fracture was seen, we should consider the possibility of rectal and lower urinary tract injury.

It is important to define the anatomic location of the rectal injury as it relates to the peritoneal reflection. Trauma to the intraperitoneal rectum should be managed as a colonic injury. Extraperitoneal rectal injury is treated with fecal diversion, distal rectal washout, presacral drainage and rectal repair. Most reports employ a variety of treatment options based on proximal diversion with the addition of primary repair, presacral drainage, and distal wash out. Disagreement remains regarding the best regimen. Johnson and Steele concluded that when proximal diversion is performed, direct repair of the rectal injury is likely unnecessary.(4) Steel et al. reported that colorectal injuries from Operation Iraqi Freedom in which all patients were treated with proximal diversion concluded that this strategy should continue in prominent use.(5) Bcsarge et al. recommends avoiding both routine presacral drains and distal rectal washout when managing rectal injury. (6) Thus, extraperitoneal rectal injury should be managed with stoma regardless of primary repair.

### REFERENCES

- 1) Demetriades D, Karaiskakis M, Toutouzas K, Alo K, Velmahos G, Chan L. Pelvic fractures: Epidemiology and predictors of associated abdominal injuries and outcomes. *J Am Coll Surg* 2002; 195: 1-10.
- 2) Aihara R, Blansfield JS, Millham FH, LaMorte WW, Hirsch EF. Fracture locations influence the likelihood of rectal and lower urinary tract injuries in patients sustaining pelvic frac-

- tures. *J Trauma Inj Infect Crit Care* 2002; 52: 205-9.
- 3) Giannoudis P V, Grotz MRW, Tzioupis C, Dinopoulos H, Wells GE, Bouamra O, et al. Prevalence of pelvic fractures, associated injuries, and mortality: the United Kingdom perspective. *J Trauma* 2007; 63: 875-83.
  - 4) Johnson EK, Steele SR. Evidence-Based Management of Colorectal Trauma. *J Gastrointest Surg* 2013; 17: 1712-9.
  - 5) Steele SR, Wolcott KE, Mullenix PS, Martin MJ, Sebesta JA, Azarow KS, et al. Colon and rectal injuries during operation Iraqi freedom: Are there any changing trends in management or outcome? *Dis Colon Rectum* 2007; 50: 870-7.
  - 6) Bosarge PL, Como JJ, Fox N, Falck-Ytter Y, Haut ER, Dorion HA, et al. Management of penetrating extraperitoneal rectal injuries: An Eastern Association for the Surgery of Trauma practice management guideline. *J Trauma Acute Care Surg* 2016; 80: 546-51.