

Research Article



Association between dental implants in the posterior region and traumatic occlusion in the adjacent premolars: a long-term follow-up clinical and radiographic analysis

Jae-Hong Lee,¹ Helen Hye-In Kweon,² Seong-Ho Choi,³ Young-Taek Kim^{2,*}

¹Department of Periodontology, Wonkwang University Daejeon Dental Hospital, Wonkwang University College of Dentistry, Daejeon, Korea

²Department of Periodontology, National Health Insurance Service Ilsan Hospital, Goyang, Korea

³Department of Periodontology, Research Institute for Periodontal Regeneration, Yonsei University College of Dentistry, Seoul, Korea



Received: Sep 20, 2016

Accepted: Nov 2, 2016

*Correspondence to

Young-Taek Kim

Department of Periodontology, National Health Insurance Service Ilsan Hospital, 100 Ilsan-ro, Ilsandong-gu, Goyang 10444, Korea.
E-mail: youngtaek77@naver.com
Tel: +82-31-900-0625
Fax: +82-31-900-0622

Copyright © 2016 Korean Academy of Periodontology

This is an Open Access article distributed under the terms of the Creative Commons Attribution Non-Commercial License (<http://creativecommons.org/licenses/by-nc/3.0/>).

ORCID

Jae-Hong Lee
<http://orcid.org/0000-0002-2375-0141>
Helen Hye-In Kweon
<http://orcid.org/0000-0003-0125-7134>
Seong-Ho Choi
<http://orcid.org/0000-0001-6704-6124>
Young-Taek Kim
<http://orcid.org/0000-0002-5132-5783>

Funding

This study was supported by the National Health Insurance Service Ilsan Hospital in 2016.

Conflict of Interest

No potential conflict of interest relevant to this article was reported.

ABSTRACT

Purpose: The aim of this retrospective study was to determine the association between dental implants in the posterior region and traumatic occlusion in the adjacent premolars, using data collected during from 2002 to 2015.

Methods: Traumatic occlusion in the adjacent premolars was assessed by examining clinical parameters (bleeding on probing, probing pocket depth, fremitus, and tooth mobility) and radiographic parameters (loss of supporting bone and widening of the periodontal ligament space) over a mean follow-up of 5 years. Clinical factors (gender, age, implant type, maxillary or mandibular position, opposing teeth, and duration of functional loading) were evaluated statistically in order to characterize the relationship between implants in the posterior region and traumatic occlusion in the adjacent premolars.

Results: The study inclusion criteria were met by 283 patients, who had received 347 implants in the posterior region. The incidence of traumatic occlusion in the adjacent premolars was significantly higher for splinted implants ($P=0.004$), implants in the maxillary region ($P<0.001$), and when implants were present in the opposing teeth ($P<0.001$). The other clinical factors of gender, age, and duration of functional loading were not significantly associated with traumatic occlusion.

Conclusions: This study found that the risk of traumatic occlusion in the adjacent premolars increased when splinted implants were placed in the maxillary molar region and when the teeth opposing an implant also contained implants.

Keywords: Bicuspid; Dental implants; Single-tooth dental implants; Tooth mobility

INTRODUCTION

Dental implants that are in direct contact with bone through osseointegration differ from natural teeth in terms of their biological structures and biomechanical characteristics [1,2]. Since they do not possess a periodontal ligament (PDL) or periodontal mechanoreceptors,

implants display low shock absorption, a low tactile threshold, and a high stress concentration at peri-implant sites [3,4]. Therefore, the occlusal concept that applies to implants is different from the occlusal concept that applies to natural teeth in terms of the occlusal form and scheme design, including a rounded and diminished cusp tip, narrow occlusal table, smooth grooves and fossa, slight occlusal contact, and shallow or flat occlusal anatomy [5,6].

The modified occlusion applied to implants is designed to reduce the occlusal force during axial and nonaxial loading conditions, as well as the stress around the implant and supporting bone structures. In addition, this concept of occlusal morphology is considered to play a major role in increasing the likelihood of clinical survival and the success rates of implants without any mechanical, biological, or aesthetic complications [7,8]. However, due to the insufficiency of clinical studies and lack of evidence-based outcomes, the ideal occlusion for implants remains to be established [9].

Maintaining the occlusal stability of the existing dentition is a very important for avoiding traumatic occlusion [10]. In particular, the loss of the posterior teeth has the greatest influence on changes in dentition and occlusion [10-12]. Including the first permanent molar teeth, which erupt first, the maxillary and mandibular molars are highly susceptible to dental caries and periodontal disease, and thus are associated with a high incidence of early loss [13]. Several treatment options exist in case of the early loss of molars. Among these options, dental implant therapy is often selected. However, this treatment strategy can sometimes result in traumatic occlusion or overloading in the adjacent premolars [14,15].

Fremitus, thermal sensitivity, widening of the PDL space, tooth mobility, and fracture are the most common symptoms of traumatic occlusions that result from overloading of the premolars, which has been proposed to be associated with implant-protected occlusion [16]. However, few studies have been conducted of the physiological and biological effects of implants on the adjacent premolars, especially regarding traumatic occlusion. Therefore, the aim of this retrospective study was to characterize the association between implants in the posterior region and traumatic occlusion in the adjacent premolars over a mean follow-up of 5 years.

MATERIALS AND METHODS

This retrospective 14-year follow-up study assessed the associations between single or splinted implants in the molar region and traumatic occlusion in the adjacent premolars, using data collected from January 2002 to November 2015. The protocol was approved by the Institutional Review Board of the National Health Insurance Service (NHIS) Ilsan Hospital (Approval No. 2016-03-038) and was conducted in the Department of Periodontology and the Department of Prosthodontics, NHIS Ilsan Hospital.

Study design and population

Dental implant surgery and prosthesis placement were conducted by a registered and calibrated periodontist and prosthodontist, respectively, at NHIS Ilsan Hospital using internal-connection fixtures with a resorbable blasting material and a sandblasted, large-grit, acid-etched surface. Prosthetic occlusion was adjusted according to the concept of implant-protected occlusion, which was proposed for reducing the parafunctional force and

protecting the implant structure [17]. All patients were encouraged to receive maintenance care at least every 6 months and have an intraoral radiograph taken every 12 months.

The following inclusion criteria were applied: 1) age of over 20 years; 2) placement of a single implant or multiple splinted implants in the molar region of the maxilla or mandible with the presence of opposing teeth (natural or implants); and 3) adjacent first and second premolars present with only natural teeth, excluding missing teeth but including restorative prostheses.

The following exclusion criteria were applied: 1) severe or uncontrolled systemic disease posing a constant threat to life; 2) uncontrolled or severe parafunctional activity such as clenching or bruxism (diagnosed by a self-administered questionnaire); 3) moderate to advanced or untreated periodontal infection or disease; 4) at the time of implant placement, adjacent premolars showing signs of inflammation or traumatic occlusion such as gingival bleeding, deep pocket depth, fremitus, widening of the PDL space, loss of the supporting bone, or tooth mobility; 5) adjacent first and second premolars including any missing teeth or restorative prostheses; 6) opposing occlusion with full or partial removable denture prosthetics; and 7) implants with mechanical complications (i.e., screw loosening and/or fracture, fixture fracture, or ceramic fracture), biological complications (peri-implantitis), or failed osseointegration.

Clinical and radiographic analysis

Each adjacent premolar was identified by examining the patient's electronic and paper dental records, as well as periapical and panoramic radiographs. Traumatic occlusion was assessed by examining clinical parameters (bleeding on probing, probing pocket depth, thermal sensitivity, tooth mobility, and fremitus) and radiographic parameters (loss of supporting bone and widening of the PDL space) at NHIS Ilsan Hospital by 2 periodontists who were specially trained and calibrated for the evaluation (Figure 1) [18]. Tooth mobility was evaluated and classified using Miller's classification, and the probing pocket depth was measured at 6 sites (mesiobuccal, midbuccal, distobuccal, mesiolingual, midlingual, and distolingual) around each tooth using a University of North Carolina (UNC) periodontal probe (Hu-Friedy, Chicago, IL, USA) [19]. All radiographic assessments were size-calibrated and performed using a picture archiving and communication system workstation (Centricity GE Healthcare, Waukesha, WI, USA).

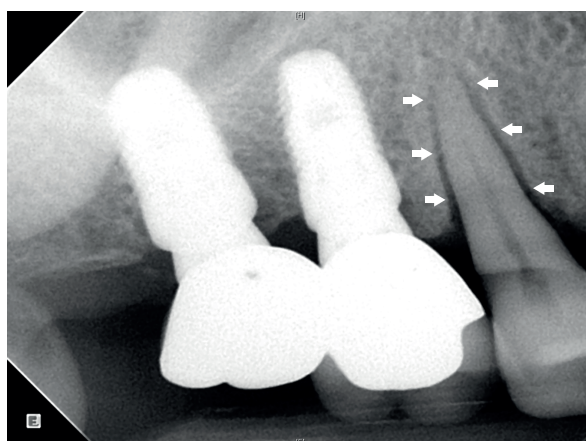


Figure 1. Radiograph of splinted dental implants in the maxillary posterior region and adjacent natural premolar tooth. The maxillary right second premolar is characterized by widening of the PDL space around the root surface (arrows) and an intact marginal bone level. PDL, periodontal ligament.

Statistical analysis

The χ^2 test, Fisher exact test, and *t*-test (2-tailed with independent samples) were performed to identify the relationship between implants in the posterior region and traumatic occlusion in the adjacent premolars using SPSS version 23 (IBM Corp., Armonk, NY, USA). Standard deviation values for the ordinary and continuous variables and the range of error at 95% confidence intervals (CIs) were calculated, and $P < 0.05$ were considered to indicate statistical significance.

RESULTS

Study population

The baseline characteristics of the patients and implants are presented in Table 1. The 283 patients who met the inclusion criteria comprised 150 males and 133 females, with a mean age of 57.1 years (range, 23–91 years). The 347 implants investigated in these patients were distributed in the posterior region as follows: Mx. first molar, $n=28$ (8.1%); maxillary second molar, $n=13$ (3.7%); maxillary splinted implant prosthesis, $n=84$ (24.2%); mandibular first molar, $n=47$ (13.5%); mandibular second molar, $n=85$ (24.5%); and mandibular splinted implant prosthesis, $n=90$ (25.9%). There were 125 implants placed in the maxilla (36.0%), and 222 were placed in the mandible (64.0%). The mean duration of functional loading was 61.9 months (range, 8–165 months).

Relationship between adjacent premolar position and severity of mobility

The severity of tooth mobility according to position in the maxilla and mandible is shown in Figure 2. Tooth mobility and widening of the PDL space occurred in 12 maxillary first premolars

Table 1. Baseline characteristics of the patients and implants included in the study

Characteristics	No.	%
Patients	283	100.0
Gender		
Male	150	53.0
Female	133	47.0
Age (yr; mean=57.1)		
20–39	16	5.7
40–59	161	56.9
60–79	104	36.7
80–99	2	0.7
Implants	347	100.0
Position ^{a)}		
Maxilla	125	36.0
First molar	28	8.1
Second molar	13	3.7
Splinted	84	24.2
Mandible	222	64.0
First molar	47	13.5
Second molar	85	24.5
Splinted	90	25.9
Duration of functional loading (yr; mean=61.9 mon)		
<3	91	26.2
3–4	55	15.9
4–5	51	14.7
5–6	37	10.7
>6	113	32.6

^{a)}Placement of a single implant or multiple splinted implants with the presence of opposing teeth (natural or implants).

(mobility [+], n=6; mobility [++], n=3; mobility [+++], n=3), 14 maxillary second premolars (mobility [+], n=8; mobility [++], n=5; mobility [+++], n=1), 1 mandibular first premolar (mobility [++], n=1), and 2 mandibular second premolars (mobility [+], n=2). No traumatic occlusion occurred at the same time in the same region in the first or second premolars.

Relationship between adjacent premolar position and duration of functional loading

Symptoms of traumatic occlusion occurred in 21 (72.4%) of 29 premolars during the first 36 months after applying functional loading. Traumatic occlusion was only observed in the maxillary premolar after 36 months. Traumatic occlusion was observed in 1 premolar adjacent to a single implant and in 7 premolars adjacent to splinted implants in the molar region (Figure 3).

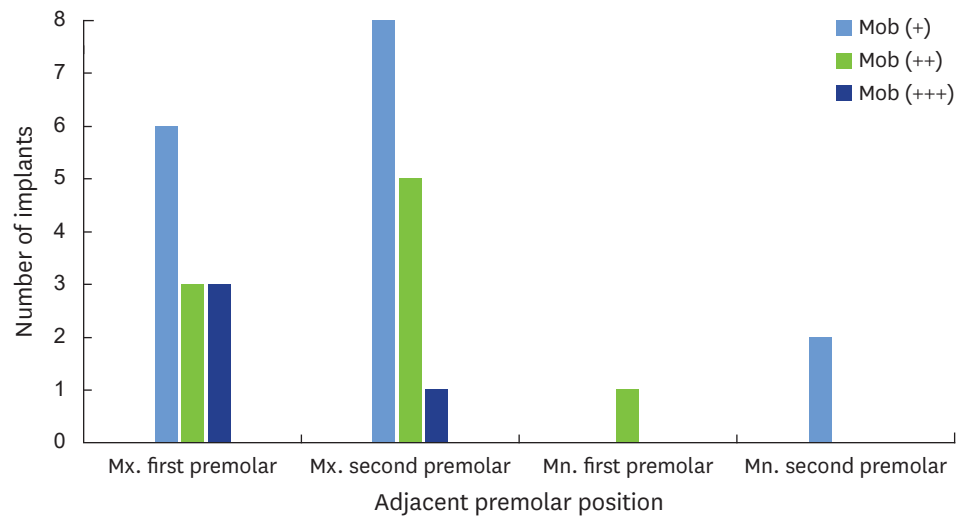


Figure 2. Severity of tooth mobility according to adjacent premolar position. Tooth mobility was evaluated and classified using Miller's classification. Mob, mobility; Mn., mandibular; Mx., maxillary.

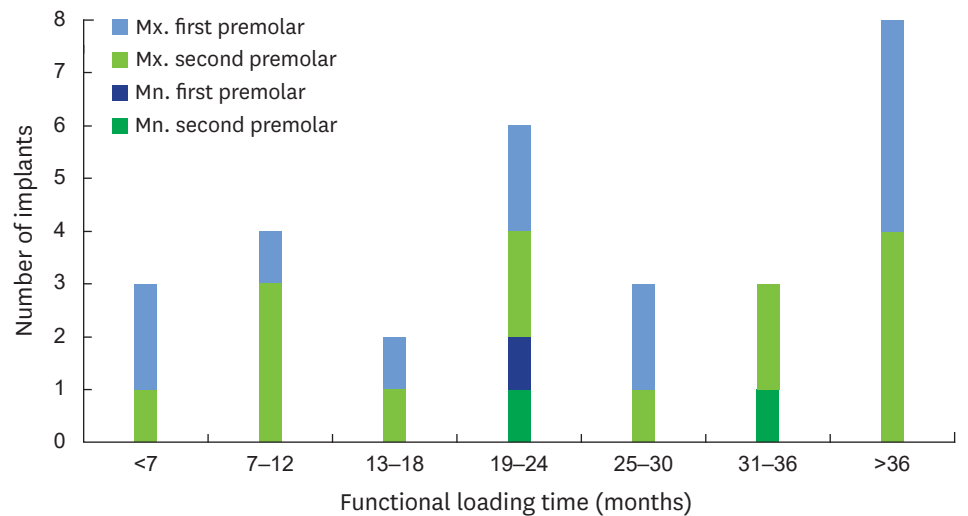


Figure 3. Incidence of traumatic occlusion in the adjacent premolar region according to the duration of functional loading. Mn., mandibular; Mx., maxillary.

Relationship between mobility in the adjacent premolar and clinical factors

The χ^2 test, Fisher exact test, and *t*-test were used to assess differences between gender, age, implant type, implant position, characteristics of the opposing teeth, and duration of functional loading with and without traumatic occlusion. As shown in Table 2, the incidence of traumatic occlusion in the adjacent premolars was significantly related to implant type ($P=0.004$), maxillary or mandibular position ($P<0.001$), and the characteristics of the opposing teeth ($P<0.001$). The other clinical factors of gender, age, and duration of functional loading were not significantly associated with traumatic occlusion.

DISCUSSION

Recent studies have found that mechanical overloading of implants did not result in either the loss of osseointegration or marginal bone loss, although this is still controversial [20,21]. A limited number of studies have been carried out to investigate excessive loading affecting the adjacent teeth. In the present study, some premolars exhibited the symptoms of traumatic occlusion, which seemed to have been due to implant overloading. Signs of fremitus, thermal sensitivity, widening of the PDL space, tooth mobility, and root resorption are clearly associated with overloading of the natural teeth [22]. In particular, widening of the PDL space and increased tooth mobility are important considerations for avoiding or at least minimizing traumatic occlusal force [23].

Traumatic occlusion was more likely to occur in maxillary premolars ($n=26$, 20.8%) than in mandibular premolars ($n=3$, 1.4%; $P<0.001$). Alveolar bone in maxillary canines and premolars has the anatomical characteristics of having the thinnest cortical bone and little cancellous bone [24]. In addition, given that the maxillary premolars are located in the anterior area among teeth with lingual cusps, they are subjected to large occlusal forces and continuous stress during forward movement of the mandible [25]. Such anatomical and physiological characteristics reduce the tolerance of these premolars to traumatic occlusion, which in turn increases the frequency of dehiscence, fenestration, widening of the PDL space, and tooth mobility [26].

Table 2. Incidence of traumatic occlusion in the adjacent premolars according to clinical factors

Characteristics	Traumatic occlusion	No traumatic occlusion	<i>P</i> ^{a)}
Patients			
Gender			0.324
Male	8 (2.8)	142 (50.2)	
Female	11 (3.9)	122 (43.1)	
Age (yr)	60.3±12.9	57.2±10.3	0.098
Implants			
Type			0.004 ^{b)}
Single crown	7 (2.0)	166 (47.8)	
Splinted crowns	22 (6.3)	152 (43.8)	
Position			<0.001 ^{b)}
Maxilla	26 (7.5)	99 (28.5)	
Mandible	3 (0.9)	219 (63.1)	
Opposing teeth ^{c)}			<0.001 ^{b)}
Natural	12 (3.5)	251 (72.3)	
Implant	17 (4.9)	67 (19.3)	
Duration of functional loading (mon)	51.6±27.8	55.1±33.5	0.583

Data are presented as number of patients (%) or mean±standard deviation.

^{a)}*P* values in this category were calculated using the χ^2 test, Fisher exact test, and *t*-test (2-tailed with independent samples); ^{b)}Statistically significant ($P<0.05$);

^{c)}Included in the implant category if at least 1 of the opposing teeth was a dental implant.

Traumatic occlusion did not occur in single implants in the second molar region. In contrast, traumatic occlusion in the adjacent premolars was present in 7 cases (4.0%) of single implants in the first molar region and in 22 cases (12.6%) of splinted implants in the molar region, and this difference was statistically significant ($P=0.004$). Based on these findings, it may be concluded that implants in the second molar region have a negligible influence on the incidence of traumatic occlusion in the adjacent premolars, while implants in the first molar region play a key role in inducing traumatic occlusion in the adjacent premolars.

The probability of traumatic occlusion in the adjacent premolars was higher for implants in occlusion with opposing teeth that include at least 1 dental implant ($n=12$, 4.6%) than when no implant was present ($n=17$, 20.2%; $P<0.001$). This is presumed to occur because the axial mobility is much smaller for opposing implants (3–5 μm) than for opposing natural teeth (25–100 μm). Greater axial mobility increases the ability of a tooth to offset overloading of the adjacent premolars [9].

A recent systematic review found that implants were associated with a 5-year cumulative survival rate of 97.2% (95% CI=96.3%–97.9%), a soft-tissue complication rate of 7.1% (95% CI=4.4%–11.3%), a mechanical complication rate of 8.8% (95% CI=5.1%–15.0%), and an aesthetic complication rate of 7.1% (95% CI=3.6%–13.6%) [27]. Various dental implant systems are currently being investigated with the aim of reducing mechanical, biological, and aesthetic complications, and this is consistent with a decreasing trend in the incidence of complications [28,29]. In the present study, the 14-year cumulative incidence of traumatic occlusion was 8.4%, which is similar to the rates of other types of complications. Of all possible etiological factors of biological and mechanical complications, traumatic occlusion is one that may be directly and actively managed at the chairside after the final prosthesis is placed [30]. We reduced the widening of the PDL space and tooth mobility and increased the stability in 27 out of 29 premolars with traumatic occlusion by performing occlusal adjustment of the implant. Additional occlusal splint therapy can be applied if it is deemed necessary to more actively prevent overloading of both the implant and the adjacent premolars [31].

Other aspects to consider when checking and adjusting implant occlusion is the mechanically locking friction fit and the patient's perceptions [32,33]. A report has indicated that the tactile threshold level, tactile function, and friction fit of the oral stimulation and occlusal force increased gradually after implant placement, although this is controversial [34,35]. It has therefore been proposed that the type of occlusion that occurs for an implantation with immediate loading may increase the risk of overloading in the early stage, which would in turn increase the frequency of traumatic occlusion of the adjacent premolars. However, future studies are needed to further evaluate this possibility.

The limitations of this study include the retrospective data collection, selection bias, absence of a control group, nonstandardized observation period, and lack of definitive confirmation of traumatic occlusion. We conducted a retrospective clinical and radiographic investigation and found that the risk of traumatic occlusion in the adjacent premolars increased when splinted implants were placed in the maxillary molar region and when implants were present in the opposing teeth. These findings indicate the importance of conducting periodic occlusion checks and addressing possible etiological factors in order to prevent overloading of the adjacent teeth. If fremitus, thermal sensitivity, widening of the PDL space, tooth mobility, or root resorption occur in the adjacent premolars, implant occlusion should be carefully considered prior to the start of periodontal treatment.

Within the limitations of this study, we found that the risk of traumatic occlusion in the adjacent premolars increased when splinted implants were placed in the maxillary molar region and when implants were present in the opposing teeth. Insufficient evidence was obtained to establish ideal guidelines for implant occlusion, and future well-designed studies are therefore required to identify how best to minimize implant occlusion.

REFERENCES

1. Schulte W. Implants and the periodontium. *Int Dent J* 1995;45:16-26.
[PUBMED](#)
2. Berglundh T, Abrahamsson I, Welander M, Lang NP, Lindhe J. Morphogenesis of the peri-implant mucosa: an experimental study in dogs. *Clin Oral Implants Res* 2007;18:1-8.
[PUBMED](#) | [CROSSREF](#)
3. Yuan JC, Sukotjo C. Occlusion for implant-supported fixed dental prostheses in partially edentulous patients: a literature review and current concepts. *J Periodontal Implant Sci* 2013;43:51-7.
[PUBMED](#) | [CROSSREF](#)
4. Koyano K, Esaki D. Occlusion on oral implants: current clinical guidelines. *J Oral Rehabil* 2015;42:153-61.
[PUBMED](#) | [CROSSREF](#)
5. Lewis MB, Klineberg I. Prosthodontic considerations designed to optimize outcomes for single-tooth implants. A review of the literature. *Aust Dent J* 2011;56:181-92.
[PUBMED](#) | [CROSSREF](#)
6. Klineberg I, Kingston D, Murray G. The bases for using a particular occlusal design in tooth and implant-borne reconstructions and complete dentures. *Clin Oral Implants Res* 2007;18 Suppl 3:151-67.
[PUBMED](#) | [CROSSREF](#)
7. Weinberg LA. Reduction of implant loading with therapeutic biomechanics. *Implant Dent* 1998;7:277-85.
[PUBMED](#) | [CROSSREF](#)
8. Morneburg TR, Pröschel PA. In vivo forces on implants influenced by occlusal scheme and food consistency. *Int J Prosthodont* 2003;16:481-6.
[PUBMED](#)
9. Kim Y, Oh TJ, Misch CE, Wang HL. Occlusal considerations in implant therapy: clinical guidelines with biomechanical rationale. *Clin Oral Implants Res* 2005;16:26-35.
[PUBMED](#) | [CROSSREF](#)
10. Craddock HL, Youngson CC, Manogue M, Blance A. Occlusal changes following posterior tooth loss in adults. Part 1: a study of clinical parameters associated with the extent and type of supraeruption in unopposed posterior teeth. *J Prosthodont* 2007;16:485-94.
[PUBMED](#) | [CROSSREF](#)
11. Craddock HL, Youngson CC, Manogue M, Blance A. Occlusal changes following posterior tooth loss in adults. Part 2. Clinical parameters associated with movement of teeth adjacent to the site of posterior tooth loss. *J Prosthodont* 2007;16:495-501.
[PUBMED](#) | [CROSSREF](#)
12. Craddock HL. Occlusal changes following posterior tooth loss in adults. Part 3. A study of clinical parameters associated with the presence of occlusal interferences following posterior tooth loss. *J Prosthodont* 2008;17:25-30.
[PUBMED](#)
13. Powell LV. Caries prediction: a review of the literature. *Community Dent Oral Epidemiol* 1998;26:361-71.
[PUBMED](#) | [CROSSREF](#)
14. Liu S, Liu Y, Xu J, Rong Q, Pan S. Influence of occlusal contact and cusp inclination on the biomechanical character of a maxillary premolar: a finite element analysis. *J Prosthet Dent* 2014;112:1238-45.
[PUBMED](#) | [CROSSREF](#)
15. Torbjörner A, Fransson B. Biomechanical aspects of prosthetic treatment of structurally compromised teeth. *Int J Prosthodont* 2004;17:135-41.
[PUBMED](#)
16. Hallmon WW, Harrel SK. Occlusal analysis, diagnosis and management in the practice of periodontics. *Periodontol* 2000 2004;34:151-64.
[PUBMED](#) | [CROSSREF](#)
17. Misch CE, Bidez MW. Implant-protected occlusion: a biomechanical rationale. *Compendium* 1994;15:1330, 1332, 1334 passim.

18. Pihlstrom BL, Anderson KA, Aeppli D, Schaffer EM. Association between signs of trauma from occlusion and periodontitis. *J Periodontol* 1986;57:1-6.
[PUBMED](#) | [CROSSREF](#)
19. Alkan A, Keskiner I, Arici S, Sato S. The effect of periodontal surgery on bite force, occlusal contact area and bite pressure. *J Am Dent Assoc* 2006;137:978-83.
[PUBMED](#) | [CROSSREF](#)
20. Heitz-Mayfield LJ, Schmid B, Weigel C, Gerber S, Bosshardt DD, Jönsson J, et al. Does excessive occlusal load affect osseointegration? An experimental study in the dog. *Clin Oral Implants Res* 2004;15:259-68.
[PUBMED](#) | [CROSSREF](#)
21. Gotfredsen K, Berglundh T, Lindhe J. Bone reactions adjacent to titanium implants subjected to static load of different duration. A study in the dog (III). *Clin Oral Implants Res* 2001;12:552-8.
[PUBMED](#) | [CROSSREF](#)
22. Wiskott HW, Cugnoni J, Scherrer SS, Ammann P, Botsis J, Belser UC. Bone reactions to controlled loading of endosseous implants: a pilot study. *Clin Oral Implants Res* 2008;19:1093-102.
[PUBMED](#) | [CROSSREF](#)
23. Okada T, Ikebe K, Inomata C, Takeshita H, Uota M, Mihara Y, et al. Association of periodontal status with occlusal force and food acceptability in 70-year-old adults: from SONIC Study. *J Oral Rehabil* 2014;41:912-9.
[PUBMED](#) | [CROSSREF](#)
24. Norton MR, Gamble C. Bone classification: an objective scale of bone density using the computerized tomography scan. *Clin Oral Implants Res* 2001;12:79-84.
[PUBMED](#) | [CROSSREF](#)
25. Ishigaki S, Kurozumi T, Morishige E, Yatani H. Occlusal interference during mastication can cause pathological tooth mobility. *J Periodontol* 2006;41:189-92.
[PUBMED](#) | [CROSSREF](#)
26. Park HS, Lee YJ, Jeong SH, Kwon TG. Density of the alveolar and basal bones of the maxilla and the mandible. *Am J Orthod Dentofacial Orthop* 2008;133:30-7.
[PUBMED](#) | [CROSSREF](#)
27. Jung RE, Zembic A, Pjetursson BE, Zwahlen M, Thoma DS. Systematic review of the survival rate and the incidence of biological, technical, and aesthetic complications of single crowns on implants reported in longitudinal studies with a mean follow-up of 5 years. *Clin Oral Implants Res* 2012;23 Suppl 6:2-21.
[PUBMED](#) | [CROSSREF](#)
28. Hermanides L. Criteria to manage the technical and biologic success of an implant abutment. *Compend Contin Educ Dent* 2014;35:463-8.
[PUBMED](#)
29. Albrektsson T, Donos N Working Group 1. Implant survival and complications. The third EAO consensus conference 2012. *Clin Oral Implants Res* 2012;23 Suppl 6:63-5.
[PUBMED](#) | [CROSSREF](#)
30. Falcón-Antenucci RM, Pellizzer EP, de Carvalho PS, Goiato MC, Noritomi PY. Influence of cusp inclination on stress distribution in implant-supported prostheses. A three-dimensional finite element analysis. *J Prosthodont* 2010;19:381-6.
[PUBMED](#) | [CROSSREF](#)
31. Hsu YT, Fu JH, Al-Hezaimi K, Wang HL. Biomechanical implant treatment complications: a systematic review of clinical studies of implants with at least 1 year of functional loading. *Int J Oral Maxillofac Implants* 2012;27:894-904.
[PUBMED](#)
32. Bhatnagar VM, Karani JT, Khanna A, Badwaik P, Pai A. Osseoperception: an implant mediated sensory motor control- a review. *J Clin Diagn Res* 2015;9:ZE18-20.
[PUBMED](#)
33. Sutter F, Weingart D, Mundwiler U, Sutter FJ, Asikainen P. ITI implants in combination with bone grafts: design and biomechanical aspects. *Clin Oral Implants Res* 1994;5:164-72.
[PUBMED](#) | [CROSSREF](#)
34. Jacobs R, Van Steenberghe D. From osseoperception to implant-mediated sensory-motor interactions and related clinical implications. *J Oral Rehabil* 2006;33:282-92.
[PUBMED](#) | [CROSSREF](#)
35. Norton MR. Assessment of cold welding properties of the internal conical interface of two commercially available implant systems. *J Prosthet Dent* 1999;81:159-66.
[PUBMED](#) | [CROSSREF](#)