

To our knowledge, this is the first report of atypical ductal hyperplasia with microcalcifications in a male patient [4]. Consequently, insufficient evidence exists to support the hypothesis that this condition is a risk factor for male breast cancer, as it is for females. This explains why no current recommendations exist for the care of these patients. In the case presented in this article, the patient was referred to a breast cancer specialist for annual follow-ups with ultrasound imaging.

Without the routine histopathological analysis of the resected specimens from gynecomastia surgery, it would have been impossible to detect this premalignant condition. This standard of practice is of the foremost importance not just for this reason, but also in order to accurately diagnose male breast cancer as early as possible in a larger number of patients.

References

1. Mathew J, Perkins GH, Stephens T, et al. Primary breast cancer in men: clinical, imaging, and pathologic findings in 57 patients. *AJR Am J Roentgenol* 2008;191:1631-9.
2. Draghi F, Tarantino CC, Madonia L, et al. Ultrasonography of the male breast. *J Ultrasound* 2011;14:122-9.
3. Cheung YC, Juan YH, Ueng SH, et al. Assessment of breast specimens with or without calcifications in diagnosing malignant and atypia for mammographic breast microcalcifications without mass: a STARD-compliant diagnostic accuracy article. *Medicine (Baltimore)* 2015;94:e1832.
4. Wells JM, Liu Y, Ginter PS, et al. Elucidating encounters of atypical ductal hyperplasia arising in gynaecomastia. *Histopathology* 2015;66:398-408.

Acute Calcific Tendinitis in the Distal Interphalangeal Joint

Jong Ho Kim¹, Jong Ho Lee¹, Ji Ung Park², Sung Tack Kwon¹

¹Department of Plastic and Reconstructive Surgery, Seoul National University College of Medicine, Seoul; ²Department of Plastic and Reconstructive Surgery, Seoul National University Boramae Medical Center, Seoul, Korea

Correspondence: Ji Ung Park
Department of Plastic and Reconstructive Surgery, Seoul National University Boramae Medical Center, Seoul National University College of Medicine, 20 Boramae-ro 5-gil, Dongjak-gu, Seoul 07061, Korea
Tel: +82-2-870-2332 Fax: +82-2-831-2826
E-mail: alfbskan@gmail.com

This material was presented at the 71st International Congress of the Korean Society of Plastic and Reconstructive Surgeons on November 1, 2013 in Seoul, Korea.

No potential conflict of interest relevant to this article was reported.

Received: 9 Jun 2015 • Revised: 7 Jul 2015 • Accepted: 14 Jul 2015
pISSN: 2234-6163 • eISSN: 2234-6171
<http://dx.doi.org/10.5999/aps.2016.43.3.301>
Arch Plast Surg 2016;43:301-303



Copyright © 2016 The Korean Society of Plastic and Reconstructive Surgeons
This is an Open Access article distributed under the terms of the Creative Commons Attribution Non-Commercial License (<http://creativecommons.org/licenses/by-nc/4.0/>) which permits unrestricted non-commercial use, distribution, and reproduction in any medium, provided the original work is properly cited.

Acute calcific tendinitis is a form of acute inflammation of the tendon, causing severe pain, swelling, and limited joint motion, and is characterized by radiologic evidence of periarticular calcification. The pathogenesis is not clear, but some

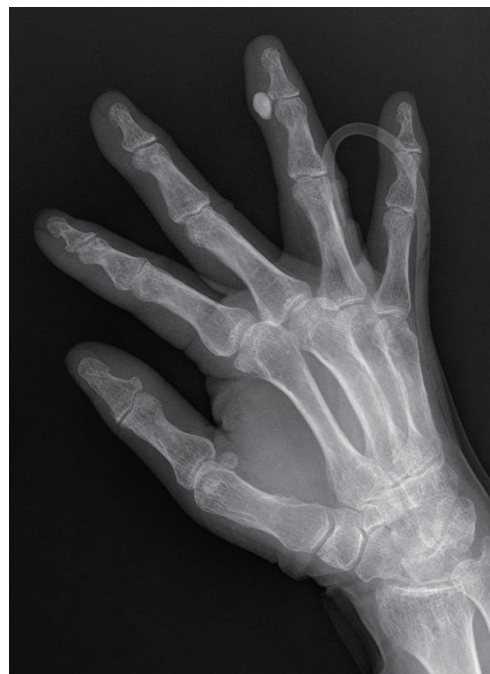

Fig. 1. The initial radiographs showed an ovoid calcification on the radial collateral ligament of the distal interphalangeal joint of the left fourth finger.

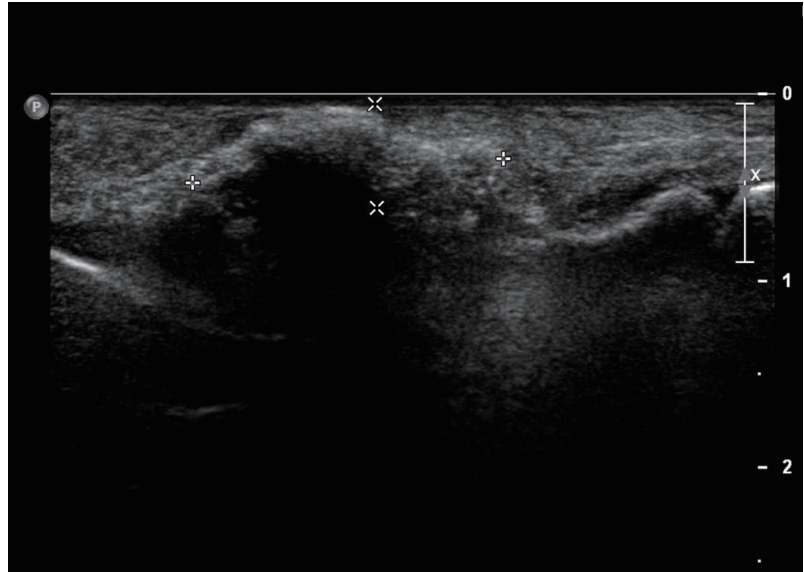


Fig. 2.
Ultrasonography revealed ovoid hyperechoic calcification.

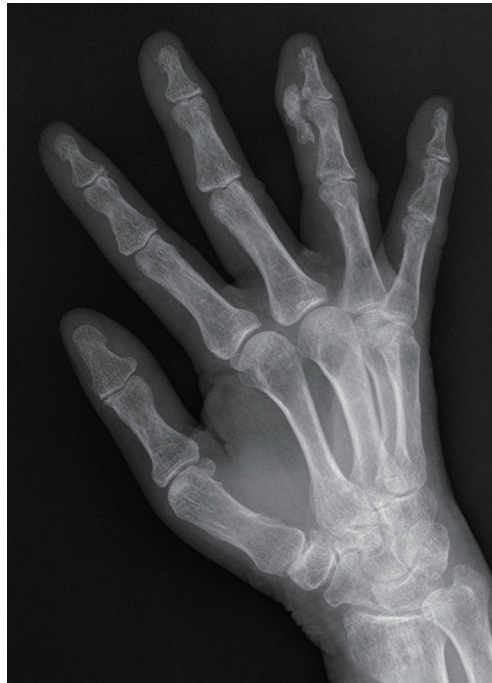

Fig. 3.
One day after conservative treatment was initiated, simple radiographic findings showed a change from an ovoid calcification to a mottled appearance, which co-occurred with the dramatic alleviation of the symptoms.

believe that calcification may result from tendon hypoxia or a traumatic event [1]. Although it is a self-limited disease, in which periarticular calcification is eventually found to be resolved in radiologic imaging, it is often misdiagnosed, which can lead to unnecessary surgical intervention. It occurs most frequently in the shoulder and wrist, and least frequently in the hand, especially the phalanx [2-4]. We encountered a rare case of acute calcific tendinitis in a postmenopausal woman in the distal interphalangeal (DIP) joint and developed an appropriate management plan based on the correct

diagnosis.

A 72-year-old female patient visited the emergency department due to severe pain in the left fourth finger that had developed three days previously. Simple radiography and ultrasonography were first performed, along with routine laboratory examinations, including C-reactive protein levels. A careful history was taken and a physical examination was then performed with the presumptive diagnosis of acute calcific tendinitis or gout, based on radiographic findings. The patient showed redness, swelling, and local heat and tenderness of the radial side of the DIP joint of the left fourth finger, but denied any history of trauma or other inflammatory disease.

The patient's history revealed that she used the DIP joint extensively because of her occupation (operating a mill). The initial radiographs showed an ovoid calcification on the radial collateral ligament of the DIP joint of the left fourth finger (Fig. 1), and ultrasonography revealed ovoid hyperechoic calcification (Fig. 2). Her C-reactive protein level was elevated. Based on previous studies of the treatment of acute calcific tendinitis of other regions, an anesthetic agent (2% lidocaine, Huons Co., Seongnam, Korea) and a corticosteroid (Triam, Shinpoong Co., Seoul, Korea) were locally injected into the lesion [3,4]. Nonsteroidal anti-inflammatory drugs (NSAIDs) were administered to the patient, and a short arm splint was applied for immobilization. One day after conservative treatment, the symptoms were dramatically alleviated and simple radiographic findings showed that the

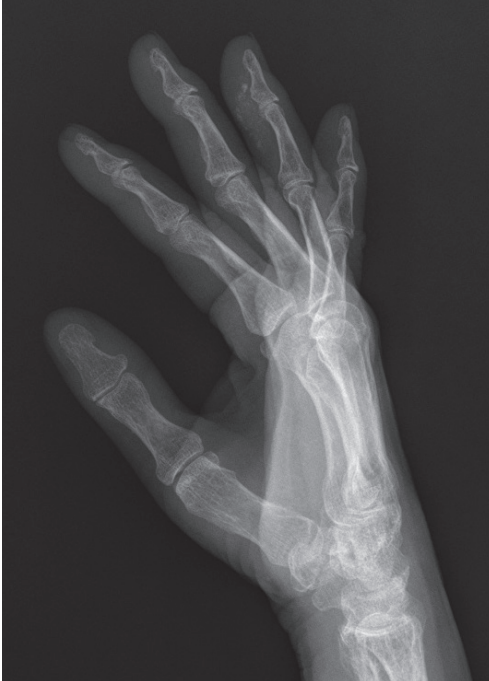

Fig. 4. Follow-up radiographic findings after two months showed the spontaneous resolution of the calcification.

appearance of the calcification had become mottled (Fig. 3), and the patient's C-reactive protein level decreased gradually. After one week of treatment, the patient experienced a complete resolution of pain and exhibited a full range of motion without difficulty. Follow-up radiographic findings after two months showed spontaneous resolution of the calcification (Fig. 4) [5].

Acute calcific tendinitis of the DIP joint is a rare condition, and, to the best of our knowledge, has not previously been reported in this anatomical location. Careful attention to the history of the patient and simple radiography helped us to diagnose this case of acute calcific tendinitis correctly. Misdiagnosis of this disease can lead to unnecessary surgical treatment and delay symptom relief. Based on reports of this condition in other regions, such as the shoulder, elbow, and wrist, conservative management with NSAIDs and a local injection of an anesthetic agent and a corticosteroid were able to relieve the symptoms dramatically in our patient. In light of our experience, acute calcific tendinitis of the hand should be considered as part of the differential diagnosis of a painful finger joint.

References

1. Dilley DF, Tonkin MA. Acute calcific tendinitis in the hand and wrist. *J Hand Surg Br* 1991;16:215-6.
2. Harris AR, McNamara TR, Brault JS, et al. An unusual presentation of acute calcific tendinitis in the hand. *Hand (N Y)* 2009;4:81-3.
3. Shields JS, Chhabra AB, Pannunzio ME. Acute calcific tendinitis of the hand: 2 case reports involving the abductor pollicis brevis. *Am J Orthop (Belle Mead NJ)* 2007;36:605-7.
4. Lee HO, Lee YH, Mun SH, et al. Calcific tendinitis of the hand and foot: a report of four cases. *J Korean Soc Magn Reson Med* 2012;16:177-83.
5. Holt PD, Keats TE. Calcific tendinitis: a review of the usual and unusual. *Skeletal Radiol* 1993;22:1-9.

Multiple Epidermal Cysts in the Volar Skin of the Thumb

Hong Jin Kim, Sung Hoon Koh, Sung Won Jung, Jihoon Yang, Hyoseob Lim

Department of Plastic and Reconstructive Surgery, Hallym University Sacred Heart Hospital, Hallym University College of Medicine, Anyang, Korea

Correspondence: Hyoseob Lim
Department of Plastic and Reconstructive Surgery, Hallym University Sacred Heart Hospital, Hallym University College of Medicine, 22 Gwanpyeong-ro 170beon-gil, Dongan-gu, Anyang 14068, Korea
Tel: +82-31-380-3781, Fax: +82-31-380-3783
E-mail: hyoseob.lim@gmail.com

No potential conflict of interest relevant to this article was reported.

Received: 27 Aug 2015 • Revised: 25 Dec 2015 • Accepted: 4 Jan 2016
pISSN: 2234-6163 • eISSN: 2234-6171
<http://dx.doi.org/10.5999/aps.2016.43.3.303>
Arch Plast Surg 2016;43:303-305

Copyright © 2016 The Korean Society of Plastic and Reconstructive Surgeons
This is an Open Access article distributed under the terms of the Creative Commons Attribution Non-Commercial License (<http://creativecommons.org/licenses/by-nc/4.0/>) which permits unrestricted non-commercial use, distribution, and reproduction in any medium, provided the original work is properly cited.

Epidermal cysts most commonly occur in hair-bearing areas, such as the scalp, face, neck, trunk, and scrotum, where many pilosebaceous glands are present [1,2]. Epidermal cysts do not commonly develop in the palmoplantar skin due to the absence of pilosebaceous glands. The etiology of epidermal cysts on the palms and soles may not involve inflammation of the hair follicle, but the traumatic implantation of epidermal elements [1,3]. In this report, we describe a case of multiple epidermal cysts