

comparing the robot-assisted technique with the laparoscopic approach for the RGE-LNF harvest, we noted that the robot-assisted intraperitoneal approach had specific advantages. The three-dimensional optics of the Da Vinci system allowed superior visualization of the anatomy. Accurate bloodless dissection was possible due to the extremely precise platform, tremor elimination, and significant motion scaling. This was particularly important since the RGE-LNF is small, and the robotic intervention allowed preservation of the lymph nodes and the fine lymphatic channels close to the vascular pedicle. In addition, it also aided in the artery and vein dissection before the final flap pedicle division.

Robot-assisted harvest of the RGE-LNF is feasible and reproducible. It represents an alternative method for flap harvest and paves the way for use of this approach for harvesting other intra-abdominal organs and tissues for reconstructive surgery. This may prove useful for patients who desire the application of the latest technology and less invasive procedures in their treatment, with the possibility of improved outcomes. It offers technical advantages over endoscopic harvesting and provides better cosmesis when compared to the open surgical technique.

Some factors may limit the use of robotic interventions, such as increased cost, a steep learning curve, and increased operating time. However, the distinct advantages of this innovative surgical approach, such as tremor elimination, motion scaling, high-resolution three-dimensional optics, and superior ergonomics, make a compelling case for the expansion of its application in problem-solving specialties, including plastic and reconstructive surgery.

## References

1. Ciudad P, Maruccia M, Socas J, et al. The laparoscopic right gastroepiploic lymph node flap transfer for upper and lower limb lymphedema: technique and outcomes. *Microsurgery* 2015 Jul 15 [Epub]. <http://dx.doi.org/10.1002/micr.22450>.
2. Nguyen AT, Suami H. Laparoscopic free omental lymphatic flap for the treatment of lymphedema. *Plast Reconstr Surg* 2015;136:114-8.
3. Selber JC, Baumann DP, Holsinger FC. Robotic latissimus dorsi muscle harvest: a case series. *Plast Reconstr Surg* 2012;129:1305-12.
4. Katz RD, Rosson GD, Taylor JA, et al. Robotics in microsurgery: use of a surgical robot to perform a free flap in a pig. *Microsurgery* 2005;25:566-9.

**Supplemental Video S1.** The supplemental digital content is an approximately two-minute video of the robotic right gastroepiploic lymph node flap harvest.

**Supplemental data can be found at:**  
<http://e-aps.org/src/sm/aps-43-210-s001.avi>

## Induced Hypothermia: Implications for Free Flap Survival

Michael W Chu<sup>1</sup>, Anita R Kulkarni<sup>2</sup>, Evan Matros<sup>3</sup>

<sup>1</sup>Division of Plastic and Reconstructive Surgery, Indiana University School of Medicine, Indianapolis, IN; <sup>2</sup>Plastic Surgery Institute of Washington, Washington, DC; <sup>3</sup>Division of Plastic and Reconstructive Surgery, Memorial Sloan-Kettering Cancer Center, New York, NY, USA

**Correspondence:** Michael W Chu  
Division of Plastic and Reconstructive Surgery, Indiana University School of Medicine, 545 Barnhill Drive Suite #232, Indianapolis, IN 46202, USA  
Tel: +1-317-217-3636, Fax: +1-317-217-3636  
E-mail: [dr.michael.chu@gmail.com](mailto:dr.michael.chu@gmail.com)

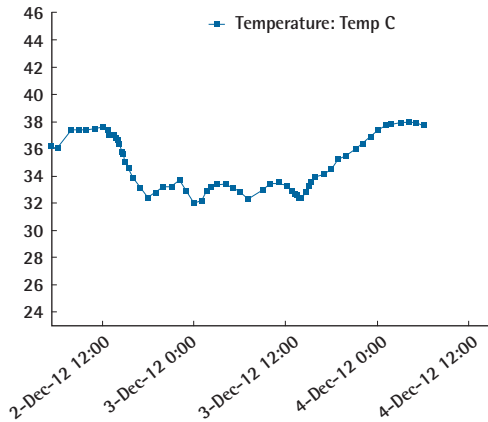
No potential conflict of interest relevant to this article was reported.

Received: 15 Oct 2015 • Accepted: 14 Dec 2015  
pISSN: 2234-6163 • eISSN: 2234-6171  
<http://dx.doi.org/10.5999/aps.2016.43.2.212>  
Arch Plast Surg 2016;43:212-214



Copyright © 2016 The Korean Society of Plastic and Reconstructive Surgeons  
This is an Open Access article distributed under the terms of the Creative Commons Attribution Non-Commercial License (<http://creativecommons.org/licenses/by-nc/4.0/>) which permits unrestricted non-commercial use, distribution, and reproduction in any medium, provided the original work is properly cited.

Plastic surgeons may not be aware that the new advanced cardiac life support (ACLS) guidelines released in 2010 include induced hypothermia as an adjuvant treatment to improve neurologic outcomes following cardiac arrest [1]. Induced hypothermia (IH) is thought to mitigate ischemic damage by lowering metabolic demand and preventing noxious byproducts of resuscitation. IH is recommended for patients who experience the return of spontaneous circulation after cardiac arrest, but remain unconscious [2]. The hypothermia protocol involves the reduction of body temperature to 32°C–34°C for 12 to 24 hours, followed by slow rewarming [1,2]. However, the use of induced hypothermia in microvascular free tissue transfer has not been studied. We present the case of a patient who underwent IH following free-flap reconstruction of a

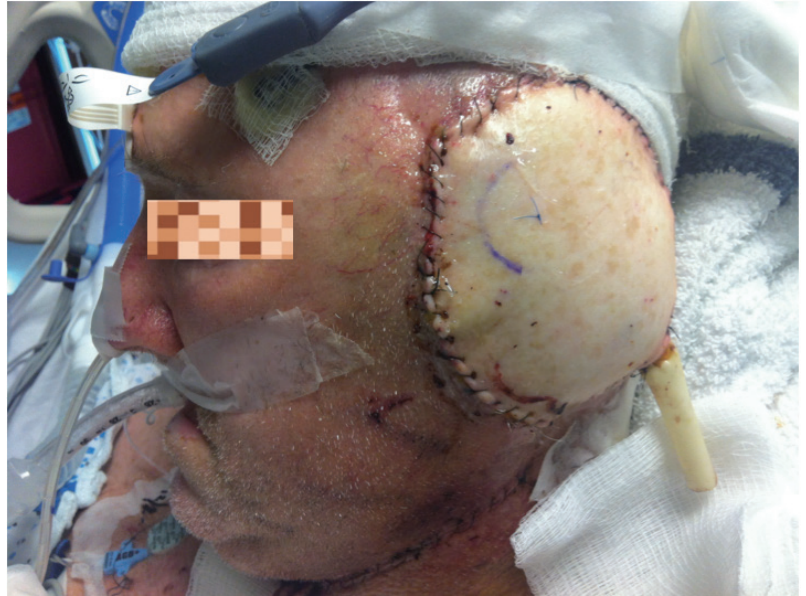

**Fig. 1.** Temperature curve showing induced hypothermia to 32°C–34°C, from postoperative day three until postoperative day five.

head and neck cancer defect.

A 69-year-old male with a history of coronary artery disease and three-vessel coronary artery bypass grafting presented with recurrent basal cell carcinoma of the left ear canal. He underwent total auriclectomy and lateral temporal bone resection, and the defect was reconstructed with a left vertical rectus abdominis myocutaneous free flap. On the second postoperative day, the patient was found unresponsive in pulseless electrical activity cardiac arrest. The ACLS protocol was initiated, including mechanical ventilation and vasopressors for hemodynamic support. The patient was successfully resuscitated but suffered a second cardiac arrest with ventricular fibrillations. He was resuscitated again but remained unresponsive. Hypothermia was induced, with the patient cooled to 32°C for 48 hours (Fig. 1). The free flap remained well perfused with an audible Doppler signal during the cardiac arrests, vasopressor therapy, hypothermic cooling, and the remainder of his hospitalization (Fig. 2). Unfortunately, the patient had no meaningful neurologic recovery and magnetic resonance imaging showed diffuse hypoxic brain injury. Therefore, the family elected to withdraw care on postoperative day 10.

The effects of systemic hypothermia on free tissue transfer are not fully understood. Limited animal and human studies have demonstrated conflicting results. Some data have suggested that hypothermia causes decreased perfusion, vasospasm, and thrombosis, while other animal experiments have shown a protective effect of mild hypothermia on free flaps [3-5]. Clotting enzymes, platelets, and leukocytes function less effectively in a hypothermic setting;



**Fig. 2.** A 69-year-old male underwent composite resection of the left auriculotemporal area and temporal bone for recurrent basal cell carcinoma, and the defect was reconstructed with a left vertical rectus abdominis myocutaneous free flap.

however, no reports have been published on the effect of severe hypothermia (< 34°C) on free flap survival in humans.

This is the first reported case of induced hypothermia after free tissue transfer. Plastic surgeons should be aware of ongoing changes to the ACLS algorithm and its impact on perioperative care. In this case, a free tissue transfer remained viable despite induced hypothermia and vasopressors, which is a single data point suggesting that free flaps can tolerate such interventions. However, further research is needed to clarify the effects of hypothermia on free tissue transfer.

## References

1. O'Connor RE, Bossaert L, Arntz HR, et al. Part 9: acute coronary syndromes: 2010 international consensus on cardiopulmonary resuscitation and emergency cardiovascular care science with treatment recommendations. *Circulation* 2010;122:S422-65.
2. Arrich J, Holzer M, Havel C, et al. Hypothermia for neuroprotection in adults after cardiopulmonary resuscitation. *Cochrane Database Syst Rev* 2012;9:CD004128.
3. Kinnunen I, Laurikainen E, Schrey A, et al. Effect of hypothermia on blood-flow responses in pedicled groin flaps in rats. *Br J Plast Surg* 2002;55:657-63.

4. Liu YJ, Hirsch BP, Shah AA, et al. Mild intraoperative hypothermia reduces free tissue transfer thrombosis. *J Reconstr Microsurg* 2011;27:121-6.
5. Thomson JG, Mine R, Shah A, et al. The effect of core temperature on the success of free tissue transfer. *J Reconstr Microsurg* 2009;25:411-6.

## Iatrogenic Calcinosis Cutis of the Upper Limb Arising from the Extravasation of Intravenous Anticancer Drugs in a Patient with Acute Lymphoblastic Leukemia

Eui Han Chung, Young Hwan Kim

*Department of Plastic and Reconstructive Surgery, Baik Hospital, Inje University School of Medicine, Busan, Korea*

**Correspondence:** Young Hwan Kim  
Department of Plastic and Reconstructive Surgery, Busan Baik Hospital, Inje University School of Medicine, 75 Bokji-ro, Busanjin-gu, Busan 47392, Korea  
Tel: +82-51-890-6136, Fax: +82-51-894-7976  
E-mail: hwanps77@hanmail.net

No potential conflict of interest relevant to this article was reported.

Received: 22 Apr 2015 • Revised: 8 Jun 2015 • Accepted: 9 Jun 2015  
pISSN: 2234-6163 • eISSN: 2234-6171  
<http://dx.doi.org/10.5999/aps.2016.43.2.214>  
*Arch Plast Surg* 2016;43:214-216



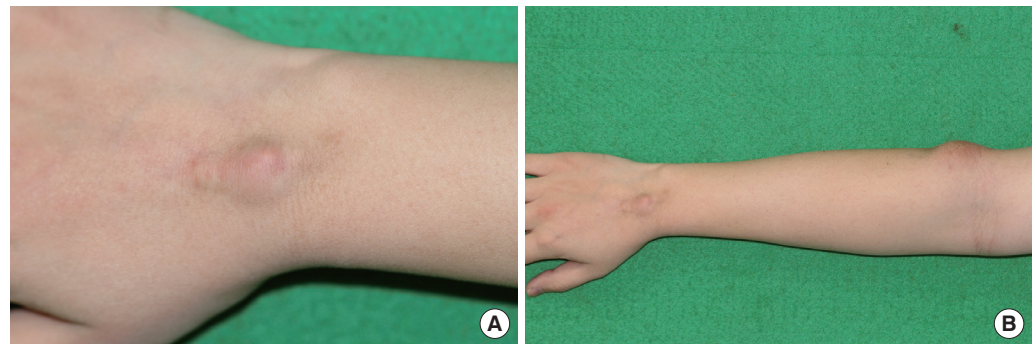
Copyright © 2016 The Korean Society of Plastic and Reconstructive Surgeons  
This is an Open Access article distributed under the terms of the Creative Commons Attribution Non-Commercial License (<http://creativecommons.org/licenses/by-nc/4.0/>) which permits unrestricted non-commercial use, distribution, and reproduction in any medium, provided the original work is properly cited.

Calcinosis cutis is a condition in which calcium salts are deposited in the skin and subcutaneous tissue due to various causes. These deposits are classified as dystrophic, metastatic, idiopathic, and iatrogenic calcifications [1]. Dystrophic calcification is characterized by damaged or abnormal local tissues without elevated serum calcium and phosphate levels.

Metastatic calcification is caused by abnormal calcium and/or phosphate metabolism. Idiopathic calcification occurs even in the absence of tissue damage or metabolic disorders. Moreover, calcification may also occur as a result of tissue damage or impaired mineral metabolism after medical interventions [2].

We experienced a case of an 18-year-old man who had been diagnosed with acute lymphoblastic leukemia (ALL) as a child and developed iatrogenic calcinosis cutis due to the extravasation of intravenous anticancer drugs. Here, we report our case with a review of the literature. In January 2015, a patient initially diagnosed with ALL in June 2001 visited us for the further evaluation and treatment of a mass. Until September 2004, the patient had been treated with methotrexate, vincristine, and cyclophosphamide at the outpatient clinic of the Department of Pediatrics. In 2002, the patient exhibited extravasation of intravenous anticancer drugs on the dorsum of the right hand. At that time, the patient presented with pain, swelling, redness, and tender inflammation. Over two weeks, the redness and inflammation had improved, but the lesion exhibited a gradual tendency towards firmness. A routine laboratory test showed calcium levels of 9.9 mg/dL and inorganic phosphate levels of 5.4 mg/dL. In February 2007, the patient experienced a relapse of ALL. Until August 2010, the patient received secondary chemotherapy using the same drugs. During this period, in 2008, the patient experienced extravasation of intravenous anticancer drugs on the elbow of the right arm. As in 2002, the patient developed a larger mass two weeks later. A routine laboratory test showed calcium levels of 9.5 mg/dL and inorganic phosphate levels of 5.3 mg/dL. Both masses persisted without changes in their size (Fig. 1).

On radiography, the patient had a radiopaque lesion at the site of each mass. On sonography, the patient had calcified lesions in the subcutaneous fat layer; the



**Fig. 1.**  
Preoperative view of the patient. (A) The mass on the dorsum of the right hand. (B) The mass on the elbow of the right arm.