

Pressure Root Resorption of the Second Molar Caused by Third Molar Impaction: A Case Report of Severely Resorbed Root with Vital Pulp

Sumi Kang, Euseong Kim

Microscope Center, Department of Conservative Dentistry and Oral Science Research Center,
Yonsei University College of Dentistry, Seoul, Korea

Pressure root resorption can be observed during the eruption of permanent dentition, especially of the maxillary canines (affecting lateral incisors) and mandibular third molars (affecting mandibular second molars). Since the cause of root resorption of the adjacent affected teeth is evident, treatment simply involves extraction of the impacted tooth. However, there have been few reports on the prognosis of the remaining resorbed tooth, as dentists often choose to extract them when damage due to root resorption is observed. We report a case involving a tooth that was severely resorbed due to pressure from an adjacent impacted tooth. After extraction of the impacted tooth, the remaining tooth retained vital pulp and survived as a functional tooth.

Key Words: Impaction; Pressure root resorption; Pulp vitality; Third molar

Introduction

Root resorption is a dental complication associated with either physiological or pathological activity of the tooth resorbing cells that results in loss of cementum and/or dentine¹⁾. The etiology of root resorption can be divided into two main categories: mechanical or chemical injury, and stimulation

by infection or pressure²⁾. It is not surprising that the treatment of root resorption depends on the etiology, but the condition is very difficult to treat and often requires extraction of the affected tooth.

Third molar impaction sometimes causes root resorption of the adjacent second molar. The reported radiographic incidence of external root resorption associated with third molar impaction

Corresponding Author: **Euseong Kim**

Microscope Center, Department of Conservative Dentistry and Oral Science Research Center, Yonsei University College of Dentistry, 50-1 Yonsei-ro, Seodaemun-gu, Seoul 03722, Korea
TEL : +82-2-2228-8701, FAX : +82-2-313-7575, E-mail : andyendo@yuhs.ac

Received for publication October 10, 2016; Returned after revision December 21, 2016; Accepted for publication December 22, 2016

Copyright © 2016 by Korean Academy of Dental Science

© This is an open access article distributed under the terms of the Creative Commons Attribution Non-Commercial License (<http://creativecommons.org/licenses/by-nc/4.0>) which permits unrestricted non-commercial use, distribution, and reproduction in any medium, provided the original work is properly cited.

varies from 3.05%³⁾ to 24.2%⁴⁾. Progressive root resorption of the second molar may develop due to pressure from the third molar, which might necessitate the removal of the second molar as well as the third molar. The process of pressure root resorption can be ceased by removal of the pressure from the impacted third molar, but the resorbed second molar also needs to be dealt with.

The prognosis of second molars affected by pressure resorption following the extraction of impacted third molars has rarely been discussed in the literature. In the present case report, a tooth that was severely resorbed due to pressure from an adjacent impacted tooth retained vital pulp and survived as a functional tooth.

Case Report

A 22-year-old male patient was referred to the Department of Conservative Dentistry at the Yonsei University Dental Hospital (Seoul, Korea) for evaluation and treatment of distal root resorption of the left mandibular second molar, tooth #37. The medical history was unremarkable. Extraction of his left lower third molar, tooth #38, had already been performed 1 week previously at the Department of Oral and Maxillofacial Surgery because of discomfort of the tooth. According to the surgeon's records, external root resorption on the distal root surface of tooth #37 was observed, seemingly caused by the impacted neighboring tooth #38 at the time of the surgical extraction. Although the periapical radiograph showed that there was extensive resorption of the distal root of tooth #37 alongside the extraction socket of tooth #38 (Fig. 1), the patient had no pain and discomfort associated with tooth #37 at the first visit to our department. Clinical examination revealed that tooth #37 had no mobility, normal responses to cold tests with ice, Endo-Frost cold spray (Roeko; Coltene Whaledent, Langenau, Germany), and electric pulp test (EPT), sensitivity to percussion, and a normal

probing depth around the tooth except for a 6-mm probing depth on the disto-buccal side adjacent to the extraction site. Given the results of our clinical tests and the absence of symptoms, the concluding diagnosis of the tooth was normal pulp and normal apical tissue with external root resorption. The treatment plan was regular follow-ups.

The patient was recalled for follow-up examinations at 6, 12, 18, and 24 months after the first examination. In clinical examinations, the tooth was functional with no signs of mobility or sensitivity to percussion, and had a normal periodontal condition. In addition, the tooth was responsive to cold tests and EPT at every follow-up visit. In radiographic examinations, the extraction socket was healed and the pulp canal space within the resorbed root was narrowed along with bone healing of the extraction socket (Fig. 2).

Discussion

There are several factors that can affect root resorption of the mandibular second molar associated with the presence of the mandibular third molar: pressure, pericoronitis, periodontal disease of the second molar and a medical history of thyroidectomy and thymectomy⁵⁾. In this case,

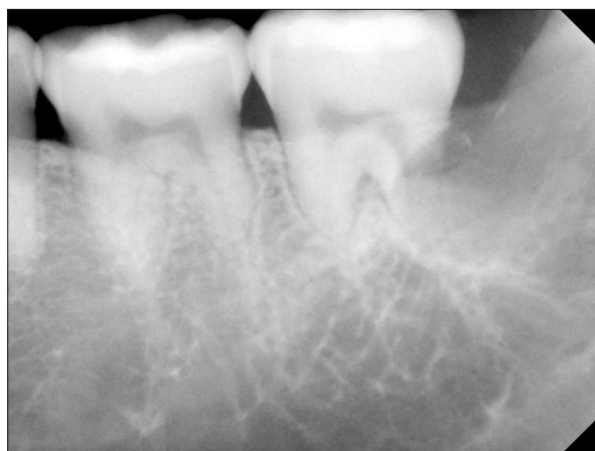

Fig. 1. Periapical radiograph of tooth #37 showing severe root resorption around the distal root of the tooth following extraction of tooth #38.

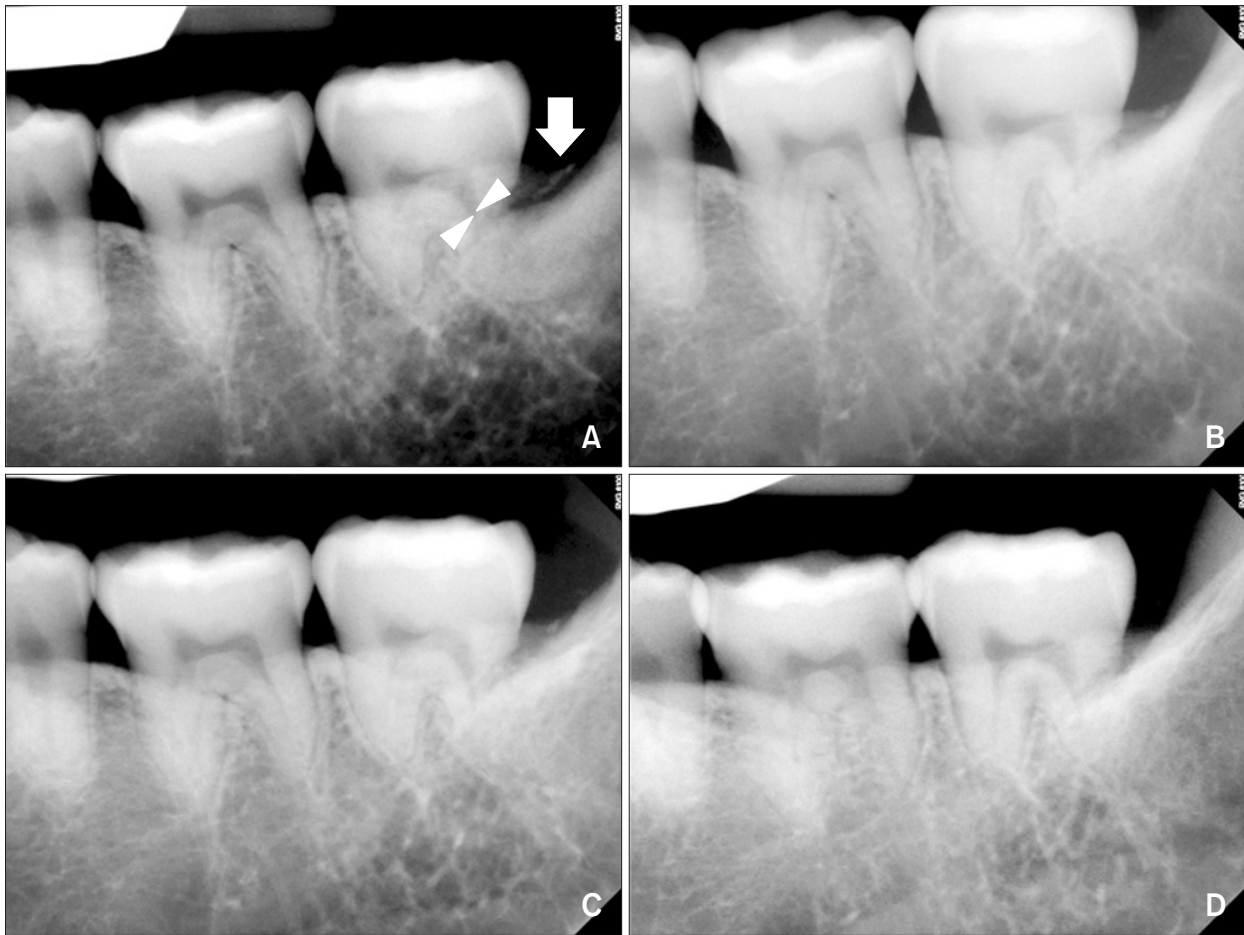


Fig. 2. Follow-up periapical radiographs of tooth #37 at 6 months (A), 12 months (B), 18 months (C), and 24 months (D) later. A narrowed root canal (arrowheads; A), implying a canal obliteration at the resorbed root side, along with alveolar bone healing (arrow; A), were observed 6 months after the removal of tooth #38.

pressure from the third molar impaction resulted in the distal root resorption of tooth #37 because the patient did not have an inflammatory impacted third molar, compromised periodontium, or contributory medical history. Comparing the panoramic radiograph in 2014 with the previous panoramic radiograph in 2012, as seen in Fig. 3, slight but obvious mesial movement of tooth #38 toward tooth #37 can be observed. This suggests that the pressure exerted by tooth #38 gradually affected the distal root of tooth #37. This type of root resorption has been described as pressure root resorption, in which the stimulation is related to the pathological process activating the resorptive cells². It was also reported that pressure root resorption is

asymptomatic with vital pulp unless the impacted tooth is located near the apical foramen, and no infection is involved in the process.

Besides the exerted pressure, other factors might mediate root resorption, such as location and angulation of non-erupted third molars. Mercier and Precious⁶ reported that horizontal and mesio-angular impacted third molars may inflict damage to the roots of adjacent teeth. Nemcovsky et al.⁴ analyzed the apical position of impacted third molars and found that mesio-inclinations of 60° or more relative to the distal root of the second molar were significantly associated with root resorption. In this case, the apical position and mesial angulation of the impacted lower third molar

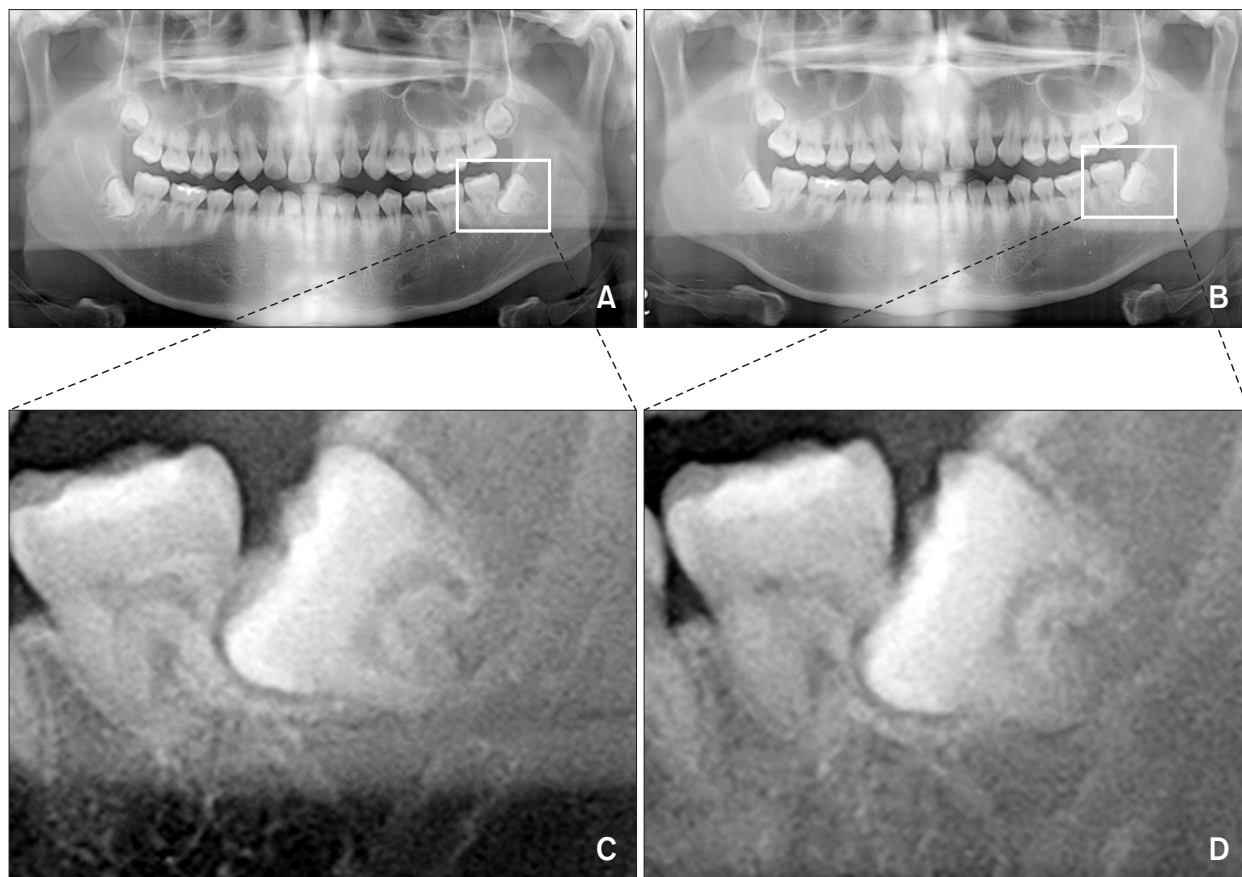


Fig. 3. Panoramic radiographs showing the mesially-impacted tooth #38 moving toward the adjacent tooth #37, indicating progressive pressure root resorption of the distal root of tooth #38 over the follow-up period between 2012 (A) and 2014 (B). (C, D) The cropped images showing a magnified view of teeth #37 and #38.

increased the susceptibility of the second molar to distal root resorption. Age and sex could contribute to root resorption as well, though their causal relationship has not been fully clarified. Nitzan et al.⁷⁾ surveyed the rate of external root resorption caused by an adjacent impacted tooth and found that the incidence was highest among the 21- to 30-year-old age group and among male patients due to the higher rates of tissue metabolism in younger persons and the effects of sex hormones on root resorption. Therefore, the severity of the root resorption shown in this case could be attributed to the fact that the patient was a 22-year-old man.

Pressure root resorption is not progressive as long as the pressure, e.g., the third molar impaction, is removed by surgical procedures. Unfortunately, most studies have only focused on the necessity

of removal of the impacted third molar, as it is the “culprit” behind pressure root resorption. In this case report, we had a chance to study the “victim”, the remaining resorbed second molar following extraction of the impacted third molar. The prognosis of the severely resorbed tooth was unclear and extraction of the tooth was considered at first, because more than half of the distal root of tooth #18 was affected, as seen in the computed tomography scans (Fig. 4). However, the asymptomatic subject and positive clinical findings led to a decision to hold off on the extraction.

An interesting feature of this case was how the severely resorbed tooth retained pulp vitality. A previous histologic study of an extracted tooth with resorbed lesion extending into the pulp due to an impacted maxillary canine could provide the

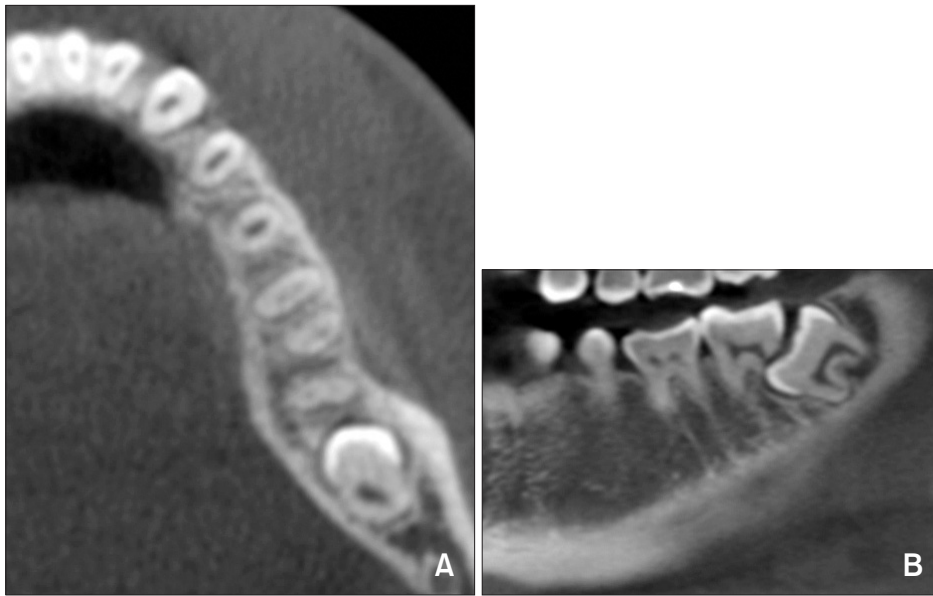

Fig. 4. Computed tomography images showing that more than half of the distal root of tooth #37 was affected by tooth #38 (A: axial view, B: sagittal view).

reason behind this⁸⁾. The authors found that the activity level of the ongoing resorption was low and most of the root surfaces showed various stages of repair tissue formation. Indeed, the exposed pulp tissue showed a normal morphology, with loose connective tissue, blood vessels, and nerves. This suggests that the pulp may have regenerative potential under pressure root resorption, which is characterized by slow progression and the absence of infection. In this case, the patient responded positively to the pulp vitality test and the follow-up periapical radiographs showed signs of pulpal healing, such as pulp obliteration. Favorable alveolar bone repair following extraction of the impacted third molar could also have contributed to preserving the pulpal environment. Marmary et al.⁹⁾ found that the degree of bone healing is affected primarily by age, and was higher in patients under the age of 30, and that periodontitis, pericoronitis, and dry socket developed among the “failure-to-heal” cases after the extraction of impacted mandibular third molars. In summary, it is likely that our patient’s young age lead to desirable alveolar bone healing, which in turn protected against inflammation, thus keeping the pulp of the remaining tooth vital.

Dentists’ priority is to maintain and preserve their patients’ own dentition as far as possible, because saving the natural teeth has many advantages compared to extraction; improved esthetics, mastication, and speech and maintenance of the natural space, arch integrity, and proprioceptive stimulation. The case report provides evidence of the healing potential of the pulp even under the unfavorable condition of pressure root resorption. Young patients with mesio-angulated impacted third molars may be vulnerable to pressure root resorption of the adjacent second molar, thus, the impacted third molar should be removed to halt the resorptive process. On the other hand, this type of root resorption tends to progress slowly enough that pulpal damage is minimized and pulp vitality is maintained. The information from this case report might be useful in treatment planning for patients with pressure root resorption of the second molar.

Conflict of Interest

No potential conflict of interest relevant to this article was reported.

References

1. Tronstad L. Root resorption--etiology, terminology and clinical manifestations. *Endod Dent Traumatol.* 1988; 4: 241-52.
2. Fuss Z, Tsesis I, Lin S. Root resorption--diagnosis, classification and treatment choices based on stimulation factors. *Dent Traumatol.* 2003; 19: 175-82.
3. Stanley HR, Alattar M, Collett WK, Stringfellow HR Jr, Spiegel EH. Pathological sequelae of "neglected" impacted third molars. *J Oral Pathol.* 1988; 17: 113-7.
4. Nemcovsky CE, Libfeld H, Zubery Y. Effect of non-erupted 3rd molars on distal roots and supporting structures of approximal teeth. A radiographic survey of 202 cases. *J Clin Periodontol.* 1996; 23: 810-5.
5. Yamaoka M, Furusawa K, Ikeda M, Hasegawa T. Root resorption of mandibular second molar teeth associated with the presence of the third molars. *Aust Dent J.* 1999; 44: 112-6.
6. Mercier P, Precious D. Risks and benefits of removal of impacted third molars. A critical review of the literature. *Int J Oral Maxillofac Surg.* 1992; 21: 17-27.
7. Nitzan D, Keren T, Marmary Y. Does an impacted tooth cause root resorption of the adjacent one? *Oral Surg Oral Med Oral Pathol.* 1981; 51: 221-4.
8. Heimisdottir K, Bosshardt D, Ruf S. Can the severity of root resorption be accurately judged by means of radiographs? A case report with histology. *Am J Orthod Dentofacial Orthop.* 2005; 128: 106-9.
9. Marmary Y, Brayer L, Tzukert A, Feller L. Alveolar bone repair following extraction of impacted mandibular third molars. *Oral Surg Oral Med Oral Pathol.* 1986; 61: 324-6.