

## The Keystone Flap in Greater Trochanter Pressure Sore

Il Hwan Byun, Soon Sung Kwon<sup>1</sup>, Seum Chung<sup>1</sup>, Woo Yeol Baek\*

Department of Plastic and Reconstructive Surgery, Yonsei University College of Medicine, Seoul,

<sup>1</sup>Department of Plastic and Reconstructive Surgery, National Health Insurance Service Ilsan Hospital, Goyang, Korea

Received July 11, 2016  
Revised August 11, 2016  
Accepted August 17, 2016

\*Correspondence to: Woo Yeol Baek  
Department of Plastic and Reconstructive  
Surgery, Yonsei University College of  
Medicine, 50 Yonsei-ro, Seodaemun-gu,  
Seoul 03722, Korea  
Tel: +82-2-2019-6367  
Fax: +82-2-577-4914  
E-mail: [parande@yuhs.ac](mailto:parande@yuhs.ac)  
ORCID: <http://orcid.org/0000-0002-6638-4110>

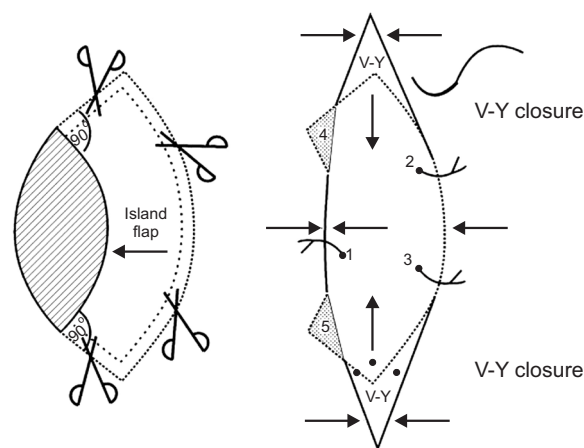
Financial support: None.  
Conflict of interest: None.

The keystone flap is a fascia-based island flap with two conjoined V-Y flaps. Here, we report a case of successful treatment of a trochanter pressure sore patient with the traditional keystone flap. A 50-year-old male patient visited our department with a 3×5 cm pressure sore (grade III) to the left of the greater trochanter that was covered with eschar. Debridement was done and the defect size increased to 5×8 cm in an elliptical shape. Doppler ultrasound was then used to locate the inferior gluteal artery perforator near the wound. The keystone flap was designed to the medial side. The perforator based keystone island flap covered the defect without resistance. The site remained clean, and no dehiscence, infection, hematoma, or seroma developed. In general, greater trochanter pressure sores are covered with a perforator based propeller flap or fascia lata flap. However, these flaps have the risk of pedicle kinking and require a large operation site. For the first time, we successfully applied the keystone flap to treat a greater trochanter pressure sore patient. Our design was also favorable with the relaxation skin tension lines. We conclude that the keystone flap including a perforator is a reliable option to reconstruct trochanteric pressure sores.

**Key Words:** Keystone flap, Pressure sore, Pressure ulcer

The keystone flap is a fascia-based island flap with two conjoined V-Y flap which is gaining popularity for its versatile use for covering various soft tissue defects, since its introduction in 2003.<sup>1</sup> It is a valuable option for closing defects of various sizes from face to lower extremities.<sup>2</sup> In defects that cannot be covered with traditional local flaps, skin grafts were the main and sometimes only option. The introduction of keystone flap opened up a powerful alternative option for such defects.<sup>3</sup> Many studies have reported the usefulness of the keystone flap for covering diverse wounds, but to our knowledge, there is no report at all on the use of keystone flap in pressure sores. Here, we report a case of pressure sore patient successfully treated with the traditional keystone flap.

The traditional keystone flap involves a defect with an elliptical shape excision. The flap design starts 90° angle from



**Fig. 1.** The original keystone flap design. Data from the article of Behan (ANZ J Surg 2003;73:112-20)<sup>2</sup> with original copyright holder's permission (John Wiley & Sons).

each corner of the ellipse and extends to create a curved arc-like flap with its width equal to the width of the defect (Fig. 1). In 2003, Behan<sup>2</sup> introduced four types of keystone flap: type I (direct closure), type II (with or without grafting), type III (employs a double island flap technique), and type IV (involves rotation and advancement with or without grafting). With further experience and development of the technique, the modified keystone flap was presented with successful outcomes.<sup>3</sup> The modified keystone flap handles defects not extended into an ellipse, and a trailing skin bridge is left intact. The modified flap effectively reduces flap scar. In this case, we used the traditional keystone flap for a pressure sore. We decided that the traditional design is more suitable for this case's large elliptical defect to provide even tension all around the flap.

### CASE REPORT

A 50-year-old male patient visited our department with a 3×5 cm pressure sore of left greater trochanter, covered with eschar (Fig. 2). He was a paraplegic patient due to past spinal cord injury and had no other medical history. The pressure sore occurred one year before the visit, and simple foam dressing was done at home. This was his first pressure sore, and he had not received any surgery before. After admission, to evaluate vessel distribution near the wound, gluteal artery computed

tomography angiography was done.

Under general anesthesia, the patient was placed on the operative table in prone position, and wide excision of the pressure sore was done. The defect size increased to 5×8 cm in an elliptical shape. Doppler ultrasound was used to locate inferior gluteal artery perforator near the wound. The traditional keystone flap was designed to the medial side. Careful dissection was done with the perforator preserved. Thorough undermining and fasciotomy was done. The island flap covered the defect without much resistance, and redundant tissues were excised. The flap was sutured without tension, and

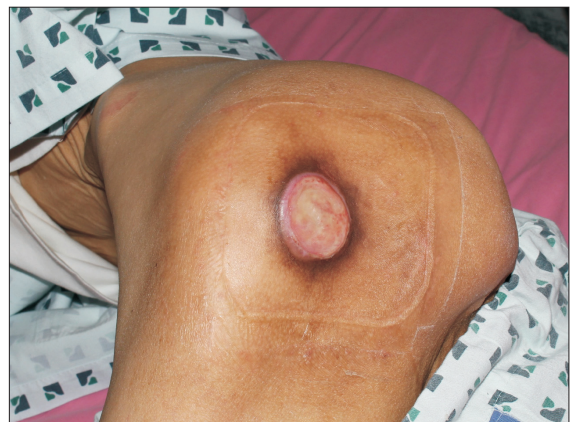

Fig. 2. A 50-year-old male patient visited our department with a 3×5 cm pressure sore of left greater trochanter, covered with eschar.

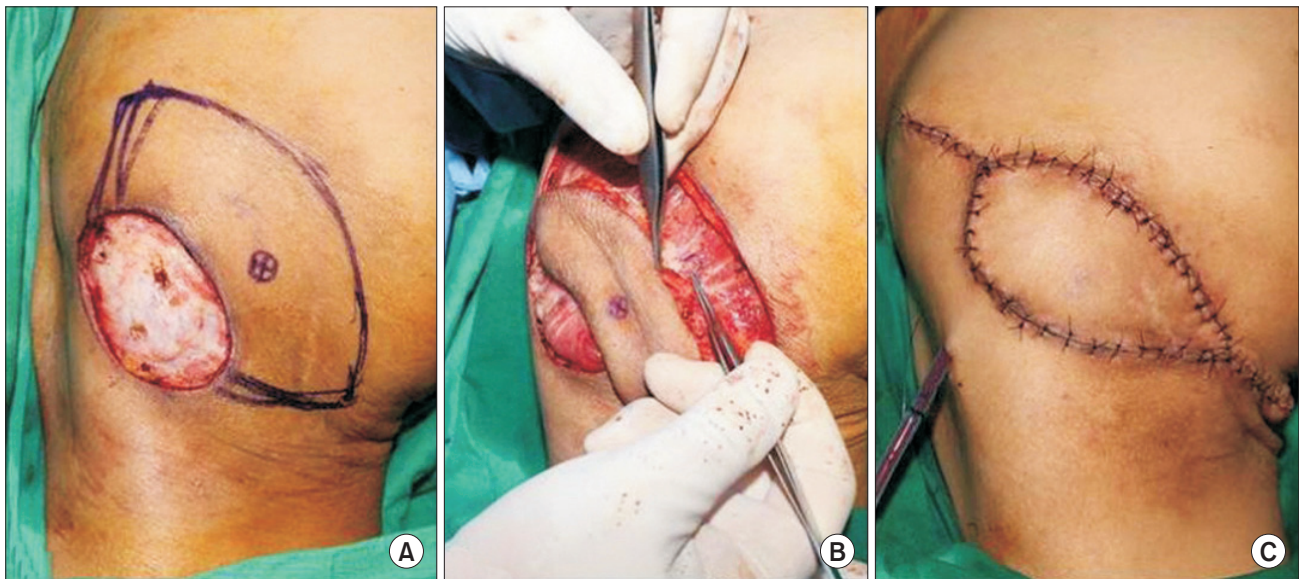


Fig. 3. (A) Wide excision of the pressure sore was done and the defect size increased to 5×8 cm in elliptical shape. Doppler ultrasound was used to locate inferior gluteal artery perforator near the wound. The traditional keystone flap was designed to the medial side. (B) Careful dissection was done with the perforator preserved. Thorough undermining and fasciotomy was done. (C) The flap was sutured without tension, and a drain was inserted.

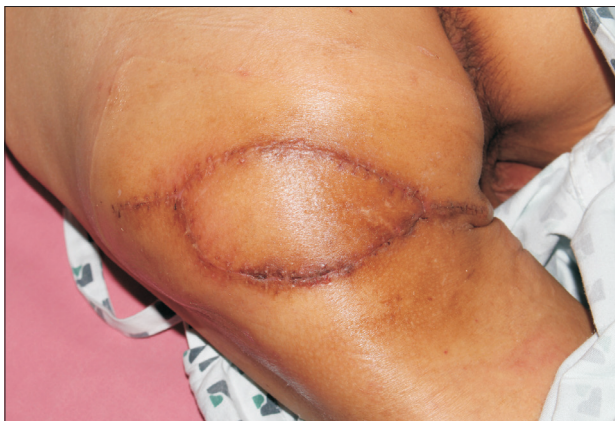

Fig. 4. Postoperative 1 month.

a drain was inserted (Fig. 3).

Daily simple dressing was done postoperatively, and the drain was removed one week after the surgery. The patient was educated not to bend his legs and maintain prone to lateral position. The stitches were removed three weeks after the operation. The site remained clean, and no dehiscence, infection, hematoma, or seroma developed (Fig. 4). The patient was pleased with the result.

## DISCUSSION

Pressure sore is a commonly encountered condition in the field of plastic and reconstructive surgery and can easily develop in paraplegic or quadriplegic patients. The wound size and location vary depending on the patient, and several surgical options exist. A greater trochanter pressure sore is often covered with perforator based propeller flap or fascia lata flap. But these flaps have the risk of pedicle kinking and large operation site. Recently, we have successfully carried out many keystone flap operations in various patients from face to lower extremities. They included both traditional and modified keystone flap designs. After examining the pressure sore of this patient, we judged that the keystone flap may be an appropriate answer for him and found that there is no reported case of pressure sore treated with the keystone flap yet.

Behan<sup>2</sup> stated that he did not use Doppler localization preoperatively or intraoperatively, but we used it to make sure our keystone flap included a reliable perforator and to proceed with dissection more effectively. Through our experience with the keystone flap in previous operations of various areas, we believe intraoperative Doppler ultrasound is a helpful tool. Between the traditional and modified design, we chose the traditional one because the defect was large and considerable flap advancement was needed to cover the wound. Also, Behan et al.<sup>4</sup> advocated completely islanding the flap to augment the deep perforator blood supply, and such blood flow was critical in this case. Our design was also favorable with the relaxation skin tension lines.

In conclusion, the keystone flap is an effective reconstructive option in defects in locations with limited tissue laxity.<sup>5</sup> For the first time, to our knowledge, we successfully applied the keystone flap to treat a greater trochanter pressure sore patient. Further studies of larger scales should be done to prove that the keystone is a significant method of treating sores, and to find out whether the traditional or modified design is more appropriate.

## REFERENCES

1. Stone JP, Webb C, McKinnon JG, Dawes JC, McKenzie CD, Temple-Oberle CF. Avoiding skin grafts: the keystone flap in cutaneous defects. *Plast Reconstr Surg* 2015;136:404-8.
2. Behan FC. The keystone design perforator Island flap in reconstructive surgery. *ANZ J Surg* 2003;73:112-20.
3. Moncrieff MD, Bowen F, Thompson JF, Saw RP, Shannon KF, Spillane AJ, et al. Keystone flap reconstruction of primary melanoma excision defects of the leg-the end of the skin graft? *Ann Surg Oncol* 2008;15:2867-73.
4. Behan FC, Lo CH, Sizeland A. The interpretation of vascular changes observed in keystone island flaps: a hypothesis. *J Plast Reconstr Aesthet Surg* 2010;63:e215-6.
5. Shipkov CD, Mojallal A. The keystone island and pedicle flap: a handy local flap for soft tissue reconstruction. *Ann Surg Oncol* 2008;15:3625.