

Analysis of midpalatal miniscrew-assisted maxillary molar distalization patterns with simultaneous use of fixed appliances: A preliminary study

Su-Jung Mah^a
Ji-Eun Kim^a
Eun Jin Ahn^b
Jong-Hyun Nam^c
Ji-Young Kim^d
Yoon-Goo Kang^b

^aDepartment of Orthodontics, Dental Hospital, Kyung Hee University Hospital at Gangdong, Seoul, Korea

^bDepartment of Orthodontics, College of Dentistry, Kyung Hee University, Seoul, Korea

^cPrivate Practice, Seoul, Korea

^dPrivate Practice, Seoul, Korea

Skeletal anchorage-assisted upper molar distalization has become one of the standard treatment modalities for the correction of Class II malocclusion. The purpose of this study was to analyze maxillary molar movement patterns according to appliance design, with the simultaneous use of buccal fixed orthodontic appliances. The authors devised two distinct types of midpalatal miniscrew-assisted maxillary molar distalizers, a lingual arch type and a pendulum type. Fourteen patients treated with one of the two types of distalizers were enrolled in the study, and the patterns of tooth movement associated with each type were compared. Pre- and post-treatment lateral cephalograms were analyzed. The lingual arch type was associated with relatively bodily upper molar distalization, while the pendulum type was associated with distal tipping with intrusion of the upper molar. Clinicians should be aware of the expected tooth movement associated with each appliance design. Further well designed studies with larger sample sizes are required. [Korean J Orthod 2016;46(1):55-61]

Key words: Distalizing, Orthodontic mini-implant, Class II

Received August 20, 2015; Revised October 21, 2015; Accepted November 17, 2015.

Corresponding author: Yoon-Goo Kang.

Associate Professor, Department of Orthodontics, College of Dentistry, Kyung Hee University, 26 Kyungheedae-ro, Dongdaemun-gu, Seoul 02447, Korea.

Tel +82-2-440-6273 **e-mail** deodor94@khu.ac.kr

The authors report no commercial, proprietary, or financial interest in the products or companies described in this article.

© 2016 The Korean Association of Orthodontists.

This is an Open Access article distributed under the terms of the Creative Commons Attribution Non-Commercial License (<http://creativecommons.org/licenses/by-nc/4.0>) which permits unrestricted non-commercial use, distribution, and reproduction in any medium, provided the original work is properly cited.

INTRODUCTION

Maxillary molar distalization is one of the most frequently used orthodontic treatment modalities for the correction of a Class II molar relationship and/or space gaining. Appliances including headgear, pendulums, Jones jigs, and distal jets have conventionally been used for maxillary molar distalization.¹⁻⁴ However, distalization is often associated with adverse effects such as anchor loss and uncontrolled tipping. Currently, skeletal anchorage, including orthodontic miniscrew-assisted upper molar distalization is the standard treatment modality. It is not limited by patient compliance, and it can prevent dental anchor loss.

There are numerous clinical skeletal anchorage options available for upper molar distalization. One method utilizes miniplates inserted into the buccal maxillary, zygomatic, and palatal bones.⁵⁻⁷ The utilization of miniscrews inserted into the buccal interdental alveolar bone, maxillary tuberosity, and palatal area for the distalization of upper molars has also been reported.⁸⁻¹⁰ Furthermore, combinations of conventional maxillary molar distalizing appliances and skeletal anchorages such as miniscrew-assisted pendulum appliances have been proposed.¹¹⁻¹³ All of these treatment modalities produce similar but different dental effects, with potentially varying levels of convenience for both clinicians and patients. Clinicians are required to acquire a full understanding of the effects of each appliance prior to treatment selection; therefore, the effects of each distalizing appliance require analysis.

A treatment system using midpalatal miniscrews has previously been reported.^{8,14} Among the proposed biomechanical options, maxillary molar distalization can be obtained using two distinct appliance designs, lingual arches and pendulum arms. The aim of this current study was to compare the patterns of tooth movement associated with these two different designs, using midpalatal miniscrews with the simultaneous use of buccal fixed orthodontic appliances.

Maxillary molar distalization with two midpalatal miniscrews

Midpalatal miniscrew placement

A multi-purpose miniscrew-supported biomechanical system to control maxillary dentition three-dimensionally has previously been described.⁸ This system utilizes two miniscrews placed in the midpalatal area, each with a 0.0215 × 0.0250-inch rectangular slot on its head. Miniscrews are inserted 2–3 mm lateral to the midpalatal suture on both the left and right sides, and in the sagittal position around the line connecting the right and left first upper molar. Placement is performed using a conventional miniscrew insertion technique. Under local anesthesia, miniscrews are inserted with a speed-reduction contra-angle hand-piece under saline irrigation. Through the insertion of various forms of wire into the miniscrews' rectangular slots, different types of maxillary tooth movement, including distalization, can be achieved.

Lingual arch type appliance for upper molar distalization

The lingual arch type of biomechanical system utilizes a lingual arch (0.8–0.9 mm) connecting the right and left first molars with hooks soldered onto the mesial part (Figure 1). A rectangular wire with hooked ends is inserted into the miniscrews' rectangular slots to connect two midpalatal miniscrews (Figure 1). Elastomeric chain or coil springs are engaged between the lingual arch hook and midpalatal miniscrew connecting wires to deliver a distalizing force to the molars. By adjusting the vertical length of the midpalatal miniscrew connecting wires, the maxillary molar distalizing pattern can be controlled: shorter lengths (hooks placed near the palatal roof) can provide greater root distalizing movement, while longer lengths (hooks placed near the tooth crown) can provide greater crown distalizing movement. In all of the cases included in the present study, the midpalatal miniscrew connecting wires and the lingual arches were adjusted to direct the distalizing force vector

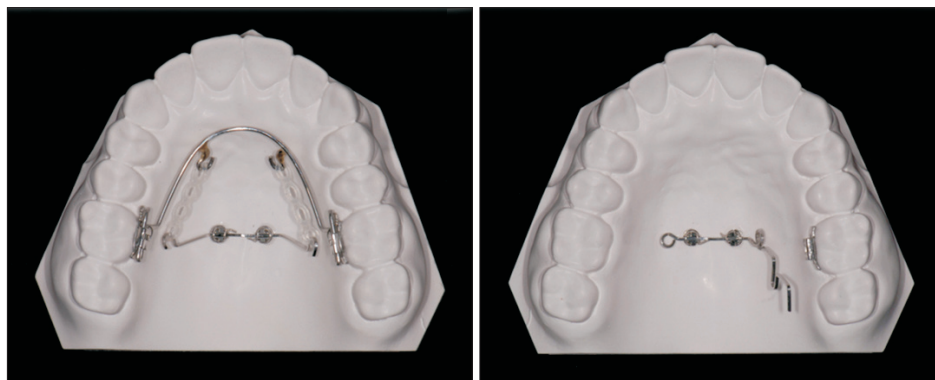

Figure 1. Midpalatal miniscrew assisted maxillary molar distalizer. Right, lingual arch-type appliance; Left, pendulum type appliance

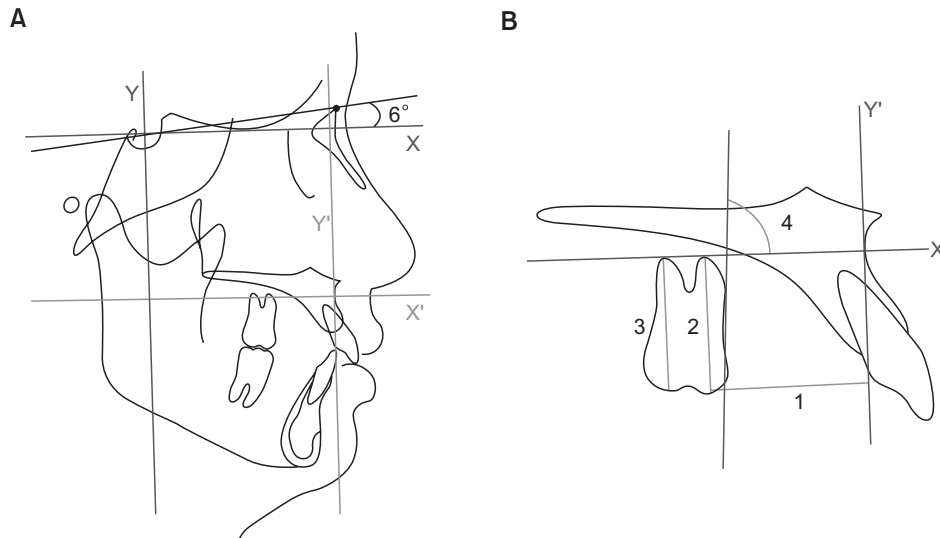


Figure 2. Cephalometric measurements. **A**, The X-Y coordinate was constructed using a horizontal rotating sella-nasion line in a downward direction at 6° (X-axis) and a vertical line perpendicular to the horizontal line passing through the sella point (Y-axis). Using the X-Y coordinate, a 0–0 point was set at point A, and a new X'–Y' coordinate was constructed. **B**, 1: Y' line to maxillary first molar mesial cusp tip distance (mm). 2: X' line to maxillary first molar mesial cusp tip distance (mm). 3: X' line to maxillary first molar distal cusp tip distance (mm). 4: Angle (°) between X' line and a line starting from the mesial point of the maxillary first molar crown tangent to the root.

through the furcation of the maxillary first molar and parallel to the occlusal plane.

Pendulum type appliance for maxillary molar distalization

The pendulum type of midpalatal miniscrew-supported maxillary molar distalizer adopts the wire design of the conventional Hilgers pendulum appliance.¹⁵ A stainless steel 0.0215 × 0.0250 inch midpalatal-miniscrew connecting wire with a helix and a horizontal loop is utilized, with its end inserted into the lingual sheath of the first molar (Figure 1). The activation mode is the same as that for the conventional pendulum appliance: the helix is activated to distalize the whole pendulum arm and then inserted into the lingual sheath of the first molar.

MATERIALS AND METHODS

To investigate the molar distalization patterns associated with lingual arch type and pendulum type appliances, 14 patients who each received one of the two appliances were enrolled into the study. All patients exhibited a bilateral or unilateral Class II molar relationship at the start of treatment. Seven patients (14 molars, age 19.2±4.4 years) were treated with the lingual arch type appliance, and seven (12 molars, age 20.9±7.6 years) were treated with the pendulum type appliance. All patients received full fixed orthodontic appliances.

With brief regard to treatment mechanics, alignment and leveling was performed after placing full fixed

appliances until 0.016 × 0.022-inch stainless steel wire could be engaged passively. Molar distalization was performed until a super Class I relationship was achieved. Molar distalizing force was subsequently decreased to hold the position while retracting premolars, canines, and incisors.

Initial (pre-orthodontic treatment) and final (post-orthodontic treatment) lateral cephalograms were obtained and analyzed. Maxillary molar movement was analyzed using measurements described by Cha and Ngan.¹⁶ The X-Y coordinate was constructed using a horizontal rotating sella-nasion line in a downward direction at 6° (X-axis) and a vertical line perpendicular to the horizontal line passing through the sella point (Y-axis). Using the X-Y coordinate, a 0–0 point was set at point A and a new X'–Y' coordinate was constructed (Figure 2A). Measurements recorded included the Y' line to maxillary first molar mesial cusp tip distance (mm), X' line to maxillary first molar mesial cusp tip distance (mm), X' line to maxillary first molar distal cusp tip distance (mm), and angle (°) between the X' line and a line starting from the mesial point of the maxillary first molar crown tangent to the root (Figure 2B).

Statistical evaluation

The Mann-Whitney U test was used to compare measurements between the two groups (lingual arch versus pendulum), while for intragroup comparisons (pre- and post-treatment), the Wilcoxon signed-rank test was used.

Table 1. Pre and post treatment measurements comparison between the appliance groups using Mann-Whitney U-test

	Pretreatment		Group difference (p-value)	Posttreatment		Group difference (p-value)
	Lingual arch type (n = 14)	Pendulum type (n = 12)		Lingual arch type (n = 14)	Pendulum type (n = 12)	
Sagittal measurement (mm)						
Y'-Mx6	26.5 ± 3.2	30.5 ± 4.5	0.231	29.1 ± 3.9	32.6 ± 4.3	0.820
Vertical measurement (mm)						
X'-mesial cusp	17.9 ± 3.0	16.8 ± 3.7	0.667	17.5 ± 2.8	16.0 ± 3.4	0.432
X'-distal cusp	15.4 ± 3.7	14.8 ± 4.7	0.899	15.0 ± 3.5	13.8 ± 4.4	0.527
Angulation (°)	84.2 ± 5.3	80.2 ± 8.9	0.403	85.3 ± 4.8	78.6 ± 8.5	0.046*

Values are presented as mean ± standard deviation.

**p* < 0.05.

RESULTS

Pre-treatment measurements did not differ statistically significantly between the two groups (Table 1). Post-treatment, first molar angulation differed significantly between the groups (Table 1). Post-treatment, the pendulum appliance group showed greater distal angulation than the lingual arch appliance group.

In the lingual arch appliance group, pre- and post-treatment comparisons yielded a mean distalization of 2.4 mm (Table 2). The vertical position exhibited slight intrusion (0.3 mm); however, this was not statistically significant. A statistically significant reduction in angulation to 0.8 mm indicated the occurrence of crown mesial tipping or root distal tipping.

For the pendulum type appliance, pre- and post-treatment comparisons yielded a mean distalization of 1.8 mm, and intrusion of the first molar differed statistically significantly (Table 2). The amount of intrusion differed between the mesial cusp and the distal cusp: distal cusp intrusion (X'-distal cusp distance -1.1 ± 0.4 mm) was greater than mesial cusp intrusion (X'-mesial cusp distance -0.8 ± 0.5 mm). Additionally, angulation changed significantly to $+1.5^\circ \pm 1.3^\circ$, indicating the occurrence of distal tipping during distalization.

DISCUSSION

The utilization of midpalatal miniscrews as an absolute anchorage mechanism offers several advantages, and can aid in the achievement of optimal treatment outcomes. The most essential advantage is the low failure rate. The midpalatal area lacks critical anatomical structures such as large sized vessels and nerves, and dental roots which are reportedly responsible for increasing the risk of miniscrew failure when they are implanted in close proximity.^{17,18} In contrast, the midpalatal area has an

abundance of keratinized gingiva with an excellent quality of cortical bones, favoring the stability of miniscrews.¹⁹ However, the utilization of midpalatal miniscrews is not as popular as interdental miniscrews because the midpalatal area is far from maxillary dentition. Several articles describing the biomechanics of midpalatal miniscrew utilization for the control of maxillary dentition have been published.^{8,14,20} The current report analyzes maxillary molar distalizing patterns as a follow-up study.

Distalizing force vector was adjusted to pass through furcation of the upper first molar for the lingual arch type appliance group. As expected, the results showed almost bodily distal movement: mean 0.8° mesial crown tipping or root distal tipping occurred, while a mean distal movement of 2.4 mm was achieved. This equates to approximately 0.3° of mesial crown tipping per 1 mm of distal movement, and is clinically negligible. The clinical advantage of the lingual arch appliance is the control of molar tipping; however, it is disadvantaged by its complex design (two wires in the palate) which can increase patient discomfort. Furthermore, it can only be applied in bilateral distalizing cases.

The pendulum type appliance produced significant distal tipping of the maxillary molars during distalization. This was anticipated based on previous studies investigating the effects of the conventional pendulum appliance, which included distal tipping of the maxillary molars during distalization.^{3,4,21} Mean distal crown tipping of 1.5° occurred during a mean distalization of 1.8 mm, which equates to approximately 0.8° distal tipping per 1 mm of distalization. The extent of distal tipping was lower than that reported in previous studies investigating the pendulum appliance; however, direct comparison is not possible as total distalization was much smaller in the present study. In addition, the movement pattern of the upper first molars measured in the present study was actually the result of a

Table 2. Evaluation of treatment changes in the lingual arch type appliance and pendulum type appliance group using Wilcoxon Signed-rank test

	Lingual arch type (n = 14)			Pendulum type (n = 12)		
	Pretreatment	Posttreatment	Changes	Pre-treatment	Post-treatment	Changes
Sagittal measurement (mm)						
Y'-Mx6	26.5 ± 3.2	29.1 ± 3.9	2.4 ± 3.1	30.5 ± 4.5	32.6 ± 4.3	1.8 ± 1.2
Vertical measurement (mm)						
X' - mesial cusp	17.9 ± 3.0	17.5 ± 2.8	-0.3 ± 1.2	16.8 ± 3.7	16.0 ± 3.4	-0.8 ± 0.5
X' - distal cusp	15.4 ± 3.7	15.0 ± 3.5	-0.3 ± 1.0	14.8 ± 4.7	13.8 ± 4.4	-1.1 ± 0.4
Angulation (°)	84.2 ± 5.3	85.3 ± 4.8	0.8 ± 2.0	80.2 ± 8.9	78.6 ± 8.5	-1.5 ± 1.3

Values are presented as mean ± standard deviation.

**p* < 0.05.

combination of the effects of the midpalatal miniscrew-supported distalizer and the labial-fixed orthodontic appliance with continuous wire. Engagement of the continuous wire on the labial side may have reduced distal tipping. Subsequent distalization of premolars, canines, and incisors may also have affected the position of distalized maxillary molars. Such tooth movement may have influenced the first molar position with regard to mesio-distal angulation and transverse rotation (particularly, mesial-in rotation could have occurred). This effect seems to have been minor however, because the resultant molar movement pattern was as expected. The reduced distal tipping of the upper molar associated with the pendulum type appliance may be a result of this effect.

There was significant intrusion of the molar during distalization using the pendulum type appliance. Several previous studies have reported intrusion of the first molar after distalization with the conventional pendulum appliance; however, statistical and clinical significance was lacking.^{3,4,22} In contrast, other studies have reported extrusion of the molar, but also without statistical or clinical significance.^{12,13} One study by Byloff and Darendeliler²³ reported significant maxillary molar intrusion during the application of the conventional pendulum appliance (1.68 ± 1.33 mm intrusion occurred in conjunction with 3.39 ± 1.25 mm distalization). They suggested that intrusion was attributable to the effect of the tongue and/or prevention of vertical growth by the rigid bonded appliance, and also noted the potential influence of the design and activation trajectory of the titanium molybdenum alloy loop. The pendulum type appliance in the present study showed significant intrusion both statistically and clinically; 1.1 mm intrusion (at the distal cusp) during 1.8 mm distalization. Unlike the study by Byloff and Darendeliler,²³ the patients in the present study were adults, in whom vertical growth of the dentoalveolar unit cannot be expected. Furthermore, in contrast to the conventional pendulum appliance, the pendulum type appliance investigated in the present study lacked a resin button via which the tongue could exert intrusion pressure on the molars. We presume that the reason for the significant intrusion is related to the absolute anchorage source provided in the midpalatal area, which is directly connected to the first molar through a wire. Further studies are required to elucidate the relationship between skeletal anchorage position and upper molar distalization pattern.

Several studies have investigated the effects of bone anchorage-supported pendulum appliances.^{12,13,24} These studies used miniscrews implanted in the anterior paramedian region of the midpalate area, embedded in the resin plate of a conventional pendulum appliance,

and lacked a premolar anchorage component. Successful distalization of the maxillary molars with significant distal tipping and without significant vertical changes was a consistent finding in all of these studies. The difference in vertical movement between previously reported studies and the present study is presumably due to variations in the position of the miniscrews.

In summary, the lingual arch type appliance is capable of bilateral bodily molar distalization, while the pendulum type appliance can distalize molars with distal tipping and intrusion. The midpalatal miniscrew-supported pendulum type appliance reported in this study can be applied for both bilateral and unilateral molar distalization. Clinicians should be aware of the differences in molar distalization patterns between appliances to facilitate effective treatment decisions. Nevertheless the buccal fixed orthodontic appliance was used simultaneously with the molar distalizers, the expected movement pattern occurred but with reduced distal tipping of the molar, when pendulum type appliance was used. Therefore, when used properly the clinician can control distal tipping of the molar resulting from the pendulum type appliance by adjusting the buccal fixed orthodontic appliance. Additional well designed studies with larger sample sizes are required to elucidate the patterns of maxillary molar distalization associated with different appliance types.

REFERENCES

1. Bolla E, Muratore F, Carano A, Bowman SJ. Evaluation of maxillary molar distalization with the distal jet: a comparison with other contemporary methods. *Angle Orthod* 2002;72:481-94.
2. Burhan AS. Combined treatment with headgear and the Frog appliance for maxillary molar distalization: a randomized controlled trial. *Korean J Orthod* 2013;43:101-9.
3. Fuziy A, Rodrigues de Almeida R, Janson G, Angelieri F, Pinzan A. Sagittal, vertical, and transverse changes consequent to maxillary molar distalization with the pendulum appliance. *Am J Orthod Dentofacial Orthop* 2006;130:502-10.
4. Patel MP, Janson G, Henriques JF, de Almeida RR, de Freitas MR, Pinzan A, et al. Comparative distalization effects of Jones jig and pendulum appliances. *Am J Orthod Dentofacial Orthop* 2009;135:336-42.
5. Sugawara J, Kanzaki R, Takahashi I, Nagasaka H, Nanda R. Distal movement of maxillary molars in nongrowing patients with the skeletal anchorage system. *Am J Orthod Dentofacial Orthop* 2006;129:723-33.
6. Nur M, Bayram M, Celikoglu M, Kilgis D, Pampu AA. Effects of maxillary molar distalization with Zygoma-Gear Appliance. *Angle Orthod* 2012;82:596-602.
7. Sa'aed NL, Park CO, Bayome M, Park JH, Kim Y, Kook YA. Skeletal and dental effects of molar distalization using a modified palatal anchorage plate in adolescents. *Angle Orthod* 2015;85:657-64.
8. Kang YG, Kim JY, Nam JH. Control of maxillary dentition with 2 midpalatal orthodontic miniscrews. *Am J Orthod Dentofacial Orthop* 2011;140:879-85.
9. Oh Y, Park HS, Kwon TG. Treatment effects of microimplant-aided sliding mechanics on distal retraction of posterior teeth. *Am J Orthod Dentofacial Orthop* 2011;139:470-81.
10. Venkateswaran S, George AM, Anand M, Devi VS, Vora SR, Krishnaswamy N. Skeletal anchorage using mini-implants in the maxillary tuberosity region. *J Ind Orthod Soc* 2013;47:217-24.
11. Cozzani M, Pasini M, Zallio F, Ritucci R, Mutinelli S, Mazzotta L, et al. Comparison of maxillary molar distalization with an implant-supported distal jet and a traditional tooth-supported distal jet appliance. *Int J Dent* 2014;2014:937059.
12. Kircelli BH, Pektaş ZO, Kircelli C. Maxillary molar distalization with a bone-anchored pendulum appliance. *Angle Orthod* 2006;76:650-9.
13. Polat-Ozsoy O, Kircelli BH, Arman-Ozçirpici A, Pektaş ZO, Uçkan S. Pendulum appliances with 2 anchorage designs: conventional anchorage vs bone anchorage. *Am J Orthod Dentofacial Orthop* 2008;133:339.e9-17.
14. Kwon HY, Mah SJ, Kang YG. Asymmetric transverse control of maxillary dentition with two midpalatal orthodontic miniscrews. *Angle Orthod* 2015;85:525-34.
15. Hilgers JJ. The pendulum appliance for Class II non-compliance therapy. *J Clin Orthod* 1992;26:706-14.
16. Cha BK, Ngan P. Skeletal anchorage for orthopedic correction of growing Class III patients. *Semin Orthod* 2011;17:124-37.
17. Kang YG, Kim JY, Lee YJ, Chung KR, Park YG. Stability of mini-screws invading the dental roots and their impact on the paradental tissues in beagles. *Angle Orthod* 2009;79:248-55.
18. Kim YH, Yang SM, Kim S, Lee JY, Kim KE, Gianelly AA, et al. Midpalatal miniscrews for orthodontic anchorage: factors affecting clinical success. *Am J Orthod Dentofacial Orthop* 2010;137:66-72.
19. Park J, Cho HJ. Three-dimensional evaluation of interradicular spaces and cortical bone thickness for the placement and initial stability of microimplants in adults. *Am J Orthod Dentofacial Orthop* 2009;136:314.e1-12; discussion 314-5.
20. Lee J, Miyazawa K, Tabuchi M, Sato T, Kawaguchi M,

- Goto S. Effectiveness of en-masse retraction using midpalatal miniscrews and a modified transpalatal arch: Treatment duration and dentoskeletal changes. *Korean J Orthod* 2014;44:88-95.
21. Onçağ G, Seçkin O, Dinçer B, Arikan F. Osseointegrated implants with pendulum springs for maxillary molar distalization: a cephalometric study. *Am J Orthod Dentofacial Orthop* 2007;131:16-26.
 22. Bussick TJ, McNamara JA Jr. Dentoalveolar and skeletal changes associated with the pendulum appliance. *Am J Orthod Dentofacial Orthop* 2000;117:333-43.
 23. Byloff FK, Darendeliler MA. Distal molar movement using the pendulum appliance. Part 1: Clinical and radiological evaluation. *Angle Orthod* 1997;67:249-60.
 24. Sar C, Kaya B, Ozsoy O, Özçirpici AA. Comparison of two implant-supported molar distalization systems. *Angle Orthod* 2013;83:460-7.