

## Case Report

# Post-Traumatic Arteriovenous Fistula of the Scalp

Hee Jong Ki, M.D., Hyun Koo Lee, M.D., Jin Woo Hur, M.D., Jong Won Lee, M.D.

Department of Neurosurgery, Cheongju St. Mary's Hospital, The Catholic University of Korea College of Medicine, Cheongju, Korea

Arteriovenous fistula of the scalp is relatively rare disease. We report a traumatic arteriovenous fistula of the scalp treated with complete surgical excision and review the literature with regard to etiology, pathogenesis, and management of these unusual lesions.

**Key Words** : Trauma · Scalp arteriovenous fistula · Superficial temporal artery.

## INTRODUCTION

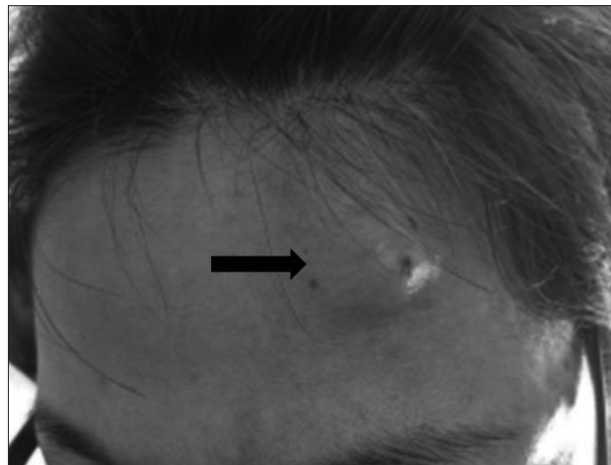
Traumatic arteriovenous fistulas (AVFs) of the scalp are rarely encountered by the neurosurgeon. AVF of the scalp is the direct connection between the arterial feeding vessels of the scalp and the draining veins without intervening capillary beds. The draining veins or feeding arteries are often grossly dilated, creating a cosmetic deformity. The symptoms are pulsatile mass, bruit, tinnitus, and headache<sup>8)</sup>. The treatment options include surgical excision<sup>1,2,4,6-8,11,12,14-17,22)</sup>, ligation of feeders, transarterial and transvenous embolization<sup>5,9,10,13,23)</sup>, and injection of sclerosing agent<sup>21)</sup>. We experienced a case of traumatic AVF of scalp, successfully treated by surgical excision.

## CASE REPORT

A 42-year-old woman bumped her forehead against the TV about 30 years ago. She noticed the swelling at her left forehead after the trauma; thereafter, a small lesion persisted without any symptoms or size alteration. From 4–5 years ago, “the mass” has gradually increased in size, and showed pulsation. She could hear bruit from the mass when she lay down; the patient also complained about frequent headaches. Physical examination revealed 25×20 mm-sized pulsatile and a round mass on the left forehead (Fig. 1). There was a continuous bruit on auscultation. The pulsation of the mass disappeared with the compression on the proximal portion of the superficial temporal artery (STA). The presumptive diagnosis of AVF was confirmed by selective internal and external carotid digital subtraction angiography (Fig. 2). The main arterial supply was from the left STA, and

other feeders were the left deep temporal artery and the ethmoid branch of the left ophthalmic artery. Drainage was seen preferentially into the superficial temporal vein, as well as into the left frontal cortical veins and left superior ophthalmic vein.

The operation was performed under general anesthesia. A curvilinear 10 cm skin incision was made on the inner part of hairline because of a cosmetic problem. The right STA and AVF were gently dissected from the adjacent subcutaneous tissue. The largest feeder was from the STA and was controlled with a hemoclip. Other vessels were all coagulated and cut. After operation, all the symptoms and signs disappeared, and no other complications developed (Fig. 3). The pathologic report confirmed consistent AVF.



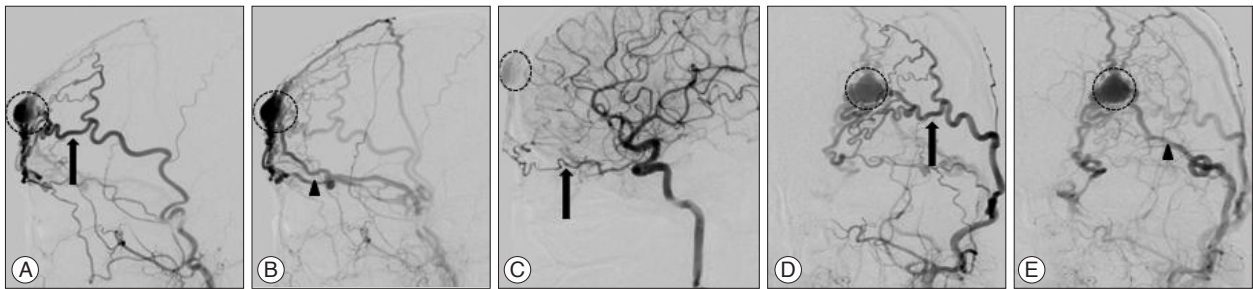**Fig. 1.** The clinical photo showing 25×20 mm-sized round mass on left forehead (arrow).

• Received : June 7, 2014 • Revised : September 3, 2014 • Accepted : September 23, 2014

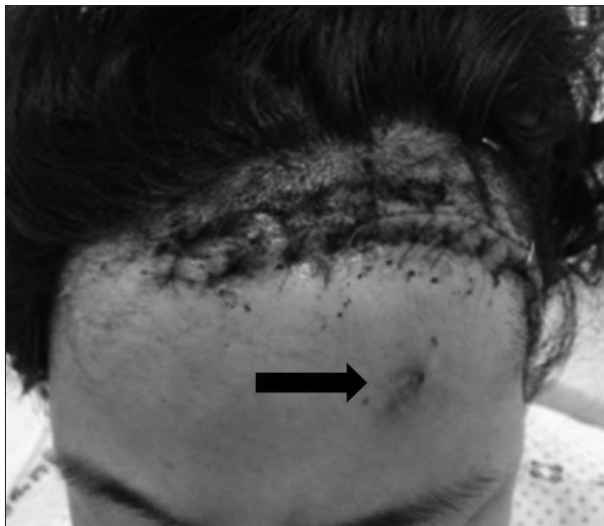• Address for reprints : Hee Jong Ki, M.D.

Department of Neurosurgery, Cheongju St. Mary's Hospital, The Catholic University of Korea College of Medicine, 173-19 Juseong-ro, Cheongwon-gu, Cheongju 28323, Korea  
Tel : +82-43-219-8150, Fax : +82-43-211-7925, E-mail : khjido1@hanmail.net

• This is an Open Access article distributed under the terms of the Creative Commons Attribution Non-Commercial License (<http://creativecommons.org/licenses/by-nc/3.0>) which permits unrestricted non-commercial use, distribution, and reproduction in any medium, provided the original work is properly cited.



**Fig. 2.** Digital subtraction angiographic images depicting the arteriovenous fistula : selective left external carotid artery from which the left superficial temporal artery comes (arrow) and drains itself mainly through the fistula (dashed circle) into multiple large superficial temporal veins (arrowhead). A and B : Lateral views. D and E : Front views. C : Lateral view of the left internal carotid artery showing feeding artery from branch of left ophthalmic artery (arrow).



**Fig. 3.** The post-operative photo showing the totally removed mass (arrow) and suture line.

## DISCUSSION

The AVF of the scalp has been previously named cirroid aneurysm, rasemose aneurysm, plexiform angioma, pulsating angioma, aneurysmal varix, arteriovenous aneurysm, and arteriovenous malformation<sup>8,17</sup>. The location of this lesion is roughly evenly distributed among the frontal, temporal, parietal, and occipital regions<sup>6</sup>. The etiology of the AVF of the scalp is still controversial, however, it may be either of congenital or traumatic origin. Among 64 patients with the AVF of the scalp reported in previous research<sup>1-18,21-23</sup>, 36 patients had the traumatic origin. Traumatic origin splits into incidental injury (28 patients) and iatrogenic injury (8 patients). Iatrogenic injury included hair transplantation<sup>3-5</sup>, craniotomy<sup>1,16</sup>, and temporomandibular joint arthroscopy<sup>5</sup>. Theories about pathogenesis of the congenital AVF include persistence of primitive AVFs, as a sequel to vascular hamartomas, and formation at a site of arteriovenous crossing<sup>8</sup>. On the other hand, there are two theories about pathogenesis of the traumatic AVFs. One is a disruption of the arterial wall and its vasa vasorum with endothelial proliferation to adjacent veins<sup>2</sup>. The other is simultaneous lacerations of

the artery and the accompanying vein result in a single fistula<sup>20</sup>.

Management of scalp AVF is difficult because of its high shunt flow, complex vascular anatomy, and associated cosmetic problems. The indication of treatment includes cosmetic relief of the pulsatile mass, prevention of hemorrhage, as well as other symptoms such as headache and tinnitus<sup>8</sup>. In the majority of cases<sup>1,2,4,6-8,11,12,14-17,22</sup>, radical surgical excision has been the most common treatment method. Complete excision of the fistula with ligation of all feeding vessels is necessary, as there is a high propensity of these lesions to recur. Incomplete treatment can also cause scalp necrosis and bleeding. Additionally, primary scalp vascular malformation can be excised entirely without significant blood loss and scalp necrosis. However, excision of secondary scalp venous dilatation without treatment of the intracranial component can be life-threatening<sup>19</sup>. Other therapeutic methods, such as ligation of feeding vessels, transarterial and transvenous embolization<sup>5,9,10,13,23</sup>, and injection of sclerosing agent<sup>21</sup> have been used to treat AVF. In the reported case, we choose the surgical method because of the cosmetic issue and the probability of recurrence with other methods. We applied a hemoclip on the largest feeder (STA), and sacrificed the other vessels with coagulation. No complications were observed, and the patient was satisfied with the outcome.

## CONCLUSION

Traumatic AVF of the scalp must be considered if the patient had a trauma and has a palpable thrill and/or pulsatile mass lesion, disappeared after proximal STA compression. There are many different methods to treat these lesions. In the present study, surgical excision under general anesthesia was chosen.

## References

1. Amlashi SE, Riffaud L, Morandi X : Arteriovenous fistula of the superficial temporal artery : an exceptional complication of the pterional approach. *J Neurol Neurosurg Psychiatry* 75 : 1077-1078, 2004
2. Badejo L, Rockwood P : Traumatic arteriovenous fistula of the scalp. Case report. *J Neurosurg* 66 : 773-774, 1987
3. Bernstein J, Podnos S, Leavitt M : Arteriovenous fistula following hair transplantation. *Dermatol Surg* 37 : 873-875, 2011
4. Champeaux C, Jecko V, Penchet G, Chibbaro S : Scalp arteriovenous fis-

- tula following hair transplantation. *Clin Neuroradiol* 24 : 285-288, 2014
5. Dabus G, Pizzolato R, Lin E, Kreusch A, Linfante I : Endovascular treatment for traumatic scalp arteriovenous fistulas : results with Onyx embolization. *J Neurointerv Surg* 6 : 405-408, 2014
  6. El Shazly AA, Saoud KM : Results of surgical excision of cirroid aneurysm of the scalp without preoperative interventions. *Asian J Neurosurg* 7 : 191-196, 2012
  7. Elkin DC : Cirroid aneurism of the scalp : with the report of an advanced case. *Ann Surg* 80 : 332-340, 1924
  8. Fisher-Jeffes ND, Domingo Z, Madden M, de Villiers JC : Arteriovenous malformations of the scalp. *Neurosurgery* 36 : 656-660; discussion 660, 1995
  9. Heilman CB, Kwan ES, Klucznik RP, Cohen AR : Elimination of a cirroid aneurysm of the scalp by direct percutaneous embolization with thrombogenic coils. Case report. *J Neurosurg* 73 : 296-300, 1990
  10. Hendrix LE, Meyer GA, Erickson SJ : Cirroid aneurysm treatment by percutaneous injection of sodium tetradecyl sulfate. *Surg Neurol* 46 : 557-560; discussion 560-561, 1996
  11. Hyshaw C, DiTullio M, Renaudin J : Superficial temporal arteriovenous fistula. *Surg Neurol* 12 : 46-48, 1979
  12. Johns DR, Swann KW, Heros RC : Spontaneous arteriovenous fistula of the superficial temporal artery. *Surg Neurol* 27 : 273-276, 1987
  13. Kumar A, Ahuja CK, Khandelwal N, Bakshi JB : Cirroid aneurysm of the right pre-auricular region : an unusual cause of tinnitus managed by endovascular glue embolisation. *J Laryngol Otol* 126 : 923-927, 2012
  14. Li F, Zhu S, Liu Y, Chen Y, Chi L, Chen G, et al. : Traumatic arteriovenous fistula of the superficial temporal artery. *J Clin Neurosci* 14 : 595-600, 2007
  15. Morandi X, Godey B, Riffaud L, Brassier G : Nontraumatic arteriovenous fistula of the superficial temporal artery. *Otolaryngol Head Neck Surg* 124 : 588-589, 2001
  16. Morioka T, Nishio S, Hikita T : Traumatic arteriovenous fistulae of the scalp at the area of previous craniotomy. *Surg Neurol* 30 : 406-407, 1988
  17. Muthukumar N, Rajagopal V, Manoharan AV, Durairaj N : Surgical management of cirroid aneurysms. *Acta Neurochir (Wien)* 144 : 349-356, 2002
  18. Saade C, Wilkinson M, Parker G, Dubenec S, Brennan P : Multidetector computed tomography in the evaluation of cirroid aneurysm of the scalp--a manifestation of trauma. *Clin Imaging* 37 : 558-560, 2013
  19. Shenoy SN, Raja A : Scalp arteriovenous malformations. *Neurol India* 52 : 478-481, 2004
  20. Stasik JE, Engelcke BR, Zwemer E, Tomaro AJ : False aneurysm of the external maxillary artery : report of case. *J Oral Surg Anesth Hosp Dent Serv* 22 : 441-445, 1964
  21. Whiteside OJ, Monksfield P, Steventon NB, Byrne J, Burton MJ : Endovascular embolization of a traumatic arteriovenous fistula of the superficial temporal artery. *J Laryngol Otol* 119 : 322-324, 2005
  22. Yi WJ, Cho JH, Lee HJ, Lee HG, Ryu KY, Kang DG, et al. : Surgical treatment of a post-traumatic arteriovenous fistula of the superficial temporal artery and vein. *J Korean Neurotraumatol Soc* 3 : 59-61, 2007
  23. Youn SW, Lee NJ, Suh SI, Kang SH : Direct-puncture embolization of scalp arteriovenous fistulae. *Neurol Med Chir (Tokyo)* 52 : 525-528, 2012