

Clinical Article

Endovascular Treatment of Vertebral Artery Dissecting Aneurysms That Cause Subarachnoid Hemorrhage : Consideration of Therapeutic Approaches Relevant to the Angioarchitecture

Seung Hoon Lim, M.D., Hee Sup Shin, M.D., Ph.D., Seung Hwan Lee, M.D., Ph.D., Jun Seok Koh, M.D., Ph.D.

Department of Neurosurgery, Kyung Hee University Hospital at Gangdong, Kyung Hee University School of Medicine, Seoul, Korea

Objective : Intracranial ruptured vertebral artery dissecting aneurysms (VADAn) are associated with high morbidity and mortality when left untreated due to the high likelihood of rebleeding. The present study aimed to establish an endovascular therapeutic strategy that focuses specifically on the angioarchitecture of ruptured VADAn.

Methods : Twenty-three patients with ruptured VADAn received endovascular treatment (EVT) over 7 years. The patient group included 14 women (60.9%) and 9 men (39.1%) between the ages of 39 and 72 years (mean age 54.2 years). Clinical data and radiologic findings were retrospectively analyzed.

Results : Four patients had aneurysms on the dominant vertebral artery. Fourteen (61%) aneurysms were located distal to the posterior inferior cerebellar artery (PICA). Six (26%) patients had an extracranial origin of the PICA on the ruptured VA, and 2 patients (9%) had bilateral VADAn. Eighteen patients (78%) were treated with internal coil trapping. Two patients (9%) required an adjunctive bypass procedure. Seven patients (30%) required stent-supported endovascular procedures. Two patients experienced intra-procedural rupture during EVT, one of which was associated with a focal medullary infarction. Two patients (9%) exhibited recanalization of the VADAn during follow-up, which required additional coiling. No recurrent hemorrhage was observed during the follow-up period.

Conclusion : EVT of ruptured VADAn based on angioarchitecture is a feasible and effective armamentarium to prevent fatal hemorrhage recurrence with an acceptable low risk of procedural complications. Clinical outcomes depend mainly on the pre-procedural clinical state of the patient. Radiologic follow-up is necessary to prevent hemorrhage recurrence after EVT.

Key Words : Vertebral artery dissecting aneurysm · Subarachnoid hemorrhage · Endovascular treatment.

INTRODUCTION

Intracranial vertebral artery dissecting aneurysms (VADAn) are rare, with an incidence of 0.001% to 0.0015% in the general population^{23,24}. VADAn account for approximately 3% of all spontaneous subarachnoid hemorrhages (SAH)^{16,29}. Ruptured VADAn are associated with dismal clinical outcomes with rebleeding rates as high as 71.4% and mortality rates of 46.7% following rebleeding²¹. Patients are especially likely to present with rebleeding in the first 24 hours, and there is a high risk of rebleeding within the first week after the initial ictus if patients remain untreated. Therefore, the early treatment of VADAn with concurrent SAH is imperative to the improvement of clinical

outcomes^{8,11,22,23}.

Conventional surgical treatments for VADAn include proximal occlusion of the ipsilateral vertebral artery (VA) and trapping the affected VA segment with or without bypass surgery. Although proximal occlusion of the VA has lower postoperative complications and is a simpler surgical procedure¹³, some reports state that regrowth or rebleeding of the VADAn can occur even after the surgical procedure due to the maintenance of blood flow from the contralateral VA^{1,11,13,28}. Trapping of the affected segment has been accepted as an appropriate management strategy to prevent rebleeding. However, ischemic complications and lower cranial nerve palsy may occur following the blockade of VA blood flow and the perforating arteries that arise from the

• Received : April 30, 2015 • Revised : July 10, 2015 • Accepted : July 20, 2015

• Address for reprints : Hee Sup Shin, M.D., Ph.D.

Department of Neurosurgery, Kyung Hee University Hospital at Gangdong, Kyung Hee University School of Medicine, 892 Dongnam-ro, Gangdong-gu, Seoul 05278, Korea
Tel : +82-440-6090, Fax : +82-440-8404, E-mail : realeponym@hanmail.net

• This is an Open Access article distributed under the terms of the Creative Commons Attribution Non-Commercial License (<http://creativecommons.org/licenses/by-nc/3.0>) which permits unrestricted non-commercial use, distribution, and reproduction in any medium, provided the original work is properly cited.

VA. Moreover, because the operative corridor of this area is narrow and deep, there are considerable operative risks that often result in incomplete trapping and revascularization failure when attempting bypass surgery³⁾.

Endovascular treatment (EVT) as a means of proximal occlusion or trapping of the VA is being used more frequently as the first-line treatment for VADAnS due to several advantages, including easy accessibility, relatively minimal invasiveness, and rapid treatment transition following diagnostic angiography⁹⁾. Although these treatments are effective and safe with a low risk of complications, they still have ischemic risks comparable to surgical measures. Nevertheless, recent attempts to use stent-assisted coil embolization and stent-only techniques with advanced intracranial stents produced satisfactory results, including both the safe obliteration of dissected aneurysms and the preservation of VA and posterior inferior cerebellar artery (PICA) patency. However, there is still an insufficient understanding of EVT for treating VADAnS, especially those with accompanying PICA involvement, bilateral presentation, and VA dominance. The present study aimed to establish an endovascular therapeutic strategy relevant to the angioarchitecture of VADAnS that cause subarachnoid hemorrhages.

MATERIALS AND METHODS

From June 2006 to December 2013, 725 patients with spontaneously ruptured intracranial aneurysms were surgically or endovascularly treated at our institution. Of these patients, 23 had ruptured VADAnS and enrolled in our study. SAH was confirmed by computed tomography (CT) scans, and contrast-enhanced three-dimensional CT angiography (3D-CTA) was performed to assess cerebral vasculature anomalies. This retrospective analysis included 9 men and 14 women whose age ranged from 39 to 72 years (mean 54.2 years). Two female patients had bilateral VADAnS, one of which eventually resulted in an SAH and the other of which required a staged subsequent EVT due to the fear of a future rupture resulting from hemodynamic augmentation after occlusion of the ruptured VA. All patients were treated within the first day of hemorrhage. Presenting symptoms included headache and vomiting, decreased consciousness, and cranial nerve palsy. Two patients experienced cardiopulmonary arrest after their clinical deterioration. The clinical status of the patients at admission was recorded according to the Hunt-Hess grading (HHG) system, and the Fisher grading (FG) system was used to evaluate the amount of blood on CT. All patients underwent 4-vessel digital subtraction angiography (DSA). The diagnosis of dissection was based on classical angiographic findings, such as fusiform dilatation, the “pearl and string” sign, subintimal flap, and irregular luminal stenosis.

We adopted EVT as the first-line treatment. The procedure performed depended on patient status, location of the dissection, composition of the related vessels, and collateral circulation. EVT was performed on the day of admission immediately after

the diagnostic DSA. EVT was performed under general anesthesia in all patients except for one who required instantaneous sacrifice of the affected VA due to a worsening clinical status. The collateral circulation was evaluated based on an elaborate analysis of the arterial and venous anatomy. When the quality of the image was poor, a diagnostic DSA was performed again under general anesthesia prior to EVT. Electrolytically detachable coils (Target[®] detachable coil, Boston Scientific, Fremont, CA, USA) were used for arterial occlusion. Stents (Neuroform, Boston Scientific, Fremont, CA, USA and Enterprise, Cordis Endovascular, Miami Lakes, FL, USA) were deployed when trapping of the VA would be expected to create an ischemic incident or when flow preservation of a neighboring PICA on the dissecting VA was necessary. Once the dissecting segment was secured, either with the deconstructive or reconstructive EVT, management for the SAH followed standard of care. Heparinization was discontinued immediately after EVT and anti-platelet agents were orally administered for 6 months after EVT when stents were used.

RESULTS

The clinical and radiological data from our 23 patients are summarized in Table 1, 2. Ten patients (45%) had poor clinical grades (HHG IV or V) and 16 patients (70%) had intraventricular or intraparenchymal hemorrhages (FG IV). Four patients had ruptured aneurysms on the dominant side of the VA, whereas 2 patients had ruptured aneurysms on the non-dominant VA. The other 17 patients had even balanced VAs on DSA. Two patients had VADAnS that extended up to the vertebrobasilar junction (VBJ). Fourteen aneurysms were located in a supra-PICA area, 1 in an infra-PICA area, 5 in a PICA-involved segment, and 3 in an irrelevant PICA area. Nine VADAnS were on the right and 14 were on the left. Two female patients had bilateral VADAnS. The diagnosis of dissection, based on classical angiographic findings, was recorded as fusiform dilatation in 5 patients, “pearl and string” sign in 14 patients, and irregular luminal stenosis in 4 patients. There were 6 patients with extracranial origins of the PICA (ECOPICA) lesions, and 1 patient exhibited a double origin of the PICA lesion.

Eighteen patients (78%) were treated with an internal trapping (partial or total) procedure using detachable coils, including 12 of 14 patients with supra-PICA lesions, 1 patient with an infra-PICA lesion, 1 of 3 patients with non-PICA lesions, and 4 of 5 patients with PICA-involved lesions. Two patients with PICA-involved lesions had partial internal trapping of the ruptured VA segment with PICA preservation, and were treated with surgical trapping for the remaining dissected segment after occipital artery (OA)-PICA bypass surgery the following day. Two of the 5 patients with PICA-involved lesions were treated using a stent procedure, which included consecutive stent-assisted coiling and stent-assisted trapping. Seven patients (30%) had stent-supported endovascular procedures. One patient with a PICA-involved lesion had internal trapping of the ruptured segment of the VA

Table 1. Clinical and angiographic characteristics of ruptured vertebral artery dissecting aneurysms

Case	Sex/ Age	Chief complaint	HHG	FG	VA dominancy	Relation to PICA	Location	Characteristic features	Other findings
1	F/52	Drowsy	III	IV	Equal	Distal & involved	Lt	Pearl & string	Bifocused aneurysmal dilatations
2	M/59	Semi-coma	V	IV	Non-dominant	Distal	Lt	Pearl & string	ECOPICA, Rt
3	M/39	Headache	II	II	Equal	Distal	Rt	Pearl & string	DOPICA, ECOPICA
4	F/43	Drowsy	III	IV	Equal	Distal	Rt	Pearl & string	BVADAn, VBJ fenestration, PComAn
5	F/58	Drowsy	III	II	Dominant	Distal & involved	Rt	Luminal irregularity	
6	F/66	Stupor	IV	IV	Dominant	Distal	Lt & VBJ	Fusiform dilatation	
7	F/70	Semi-coma	IV	IV	Dominant	Distal & involved	Rt	Luminal irregularity	
8	M/52	Coma, CPR	V	IV	Equal	Distal	Lt	Pearl & string	
9	M/61	Semi-coma	V	IV	Equal	Distal & involved	Rt	Luminal irregularity	Contralateral VA narrowing
10	F/43	Drowsy	III	IV	Equal	Distal	Lt	Pearl & string	BVADAn, ECOPICA
11	M/55	Drowsy	III	II	Equal	Distal	Lt	Fusiform dilatation	VBJ fenestration
12	F/67	Semi-coma	IV	IV	Equal	No PICA	Lt	Pearl & string	Ipsilateral AICA common trunk
13	F/72	Drowsy	III	II	Equal	Distal	Rt	Pearl & string	
14	M/49	Semi-coma	IV	IV	Equal	Distal	Lt	Pearl & string	
15	F/42	Drowsy	III	IV	Equal	Distal	Lt	Pearl & string	
16	F/56	Drowsy	III	IV	Equal	Distal	Lt & VBJ	Luminal irregularity	
17	F/64	Drowsy	III	III	Dominant	No PICA	Lt	Pearl & string	Ipsilateral AICA common trunk
18	M/46	Stupor	IV	IV	Equal	Distal	Lt	Pearl & string	ECOPICA, Lt
19	M/57	Headache	II	III	Equal	Proximal	Rt	Fusiform dilatation	
20	F/46	Drowsy	III	IV	Equal	Distal	Lt	Fusiform dilatation	
21	M/54	Stupor	IV	IV	Equal	Distal	Rt	Pearl & string	ECOPICA, Rt
22	F/61	Stupor	IV	IV	Non-dominant	No PICA	Lt	Pearl & string	
23	F/43	Headache	II	III	Equal	Distal & involved	Rt	Fusiform dilatation	ECOPICA, Rt

F : female, M : male, HHG : Hunt-Hess grading system, FG : Fisher grading system, VA : vertebral artery, PICA : posterior inferior cerebellar artery, AICA : anterior inferior cerebellar artery, PComAn : posterior communicating artery aneurysm, Lt : left, Rt : right, ECOPICA : extracranial origins of posterior inferior cerebellar artery, DOPICA : double origin of posterior inferior cerebellar artery, BVADAn : bilateral vertebral artery dissecting aneurysm, VBJ : vertebrobasilar junction, CPR : cardiopulmonary resuscitation

under local anesthesia due to a poor clinical condition, therefore, the PICA origin could not be determined.

Three of the 4 patients with ruptured dissecting aneurysms on the dominant VA had stent-assisted coiling procedures to preserve the VA flow. One patient had ipsilateral VA trapping after an OA-PICA bypass to preserve the PICA flow because the contralateral VA was not severely hypoplastic. Ventricular or lumbar cerebrospinal fluid drainage occurred in 17 patients (74%) with acute hydrocephalus or thick intraventricular hematoma, and 2 patients (9%) required a permanent ventriculoperitoneal shunt for delayed communicating hydrocephalus.

Clinical outcomes were favorable for 15 of 23 patients (65%); 13 patients (17%) had good recovery, and 2 patients (4%) had moderate disability. Outcomes were unfavorable for 8 patients (35%); 4 patients (17%) had severe disability, 1 patient (4%) entered a persistent vegetative state, and 3 patients (13%) died. All 3 patient deaths could be attributed to the severity of the initial clinical status (HHG IV). The complete occlusion of the dissected arterial and aneurysm segment was achieved in 21 of 23 pa-

tients (91%). Two patients (1 with stent-assisted coiling and 1 with internal trapping) had near-complete occlusions on angiography, and one required additional endovascular coiling during the follow-up period.

There were 5 complications in our study : 2 patients developed rebleeding at the end of the coiling procedure, 1 patient developed symptomatic medullary infarction, and 2 patients experienced recanalization of the VADAn after the first EVT. Rebleeding during the endovascular procedure was managed with an additional compact coil insertion or rescue stent placement and reversal of the anticoagulant.

Illustrative cases

Case 1

A 52-year-old woman presented with decreased consciousness after a sudden headache and vomiting. A brain CT indicated a dense SAH and 3D-CTA revealed dilatation and narrowing of the left VA, indicating a possible dissection. An emergency

Table 2. Outcomes and complications of ruptured vertebral artery dissecting aneurysms by treatment method

Case	Treatment modalities	Angiographic outcomes*	Clinical outcomes	Complications
1	Partial trapping, surgical trapping after OA-PICA bypass	Complete	GR	
2	Trapping	Complete	SD	
3	Trapping	Complete	GR	
4	Trapping	Complete	GR	
5	Partial trapping, surgical trapping after OA-PICA bypass	Complete	GR	
6	Stent assisted coiling	Near complete [†]	GR	Recanalization
7	Stent assisted coiling f/b rescue stent	Complete	Death	Aneurysm rupture
8	Trapping	Near complete	PVS	
9	Trapping	Complete	MD	Focal medullary infarction
10	Trapping	Complete	GR	
11	Stent (contralateral) assisted trapping	Complete	GR	
12	Trapping	Complete	SD	
13	Trapping	Complete	GR	
14	Trapping	Complete	SD	
15	Trapping	Complete	GR	
16	Stent assisted coiling f/b double stent	Complete	GR	
17	Stent assisted coiling	Complete	GR	
18	Trapping	Complete	Death	
19	Trapping	Complete	GR	Aneurysm rupture
20	Trapping	Complete	Death	
21	Trapping	Complete	MD	
22	Stent assisted coiling	Complete	SD	
23	Stent assisted trapping	Complete [†]	GR	Recanalization

*Degree of occlusion in angiographic findings, [†]Recanalization during follow-up required additional endovascular treatment. OA : occipital artery, PICA : posterior inferior cerebellar artery, GR : good recovery, MD : moderate disability, SD : severe disability, PVS : persistent vegetative state

cerebral DSA was conducted, and a vertebral angiogram (VAG) indicated that the left VA dissection produced multiple dilations and stenosis (Fig. 1A, B). Both VAs had similar diameters. The proximal VADAn included the origin of the PICA (Fig. 1C) and the distal VADAn was hypothesized as the source of the SAH. Under general anesthesia, the ruptured distal VADAn was internally trapped (Fig. 1D, E); the proximal part of the VADAn was then surgically trapped after OA-PICA bypass surgery the next day (Fig. 1F, G). A postoperative angiogram demonstrated a completely occluded VADAn and well-preserved PICA flow (Fig. 1H). The patient recovered well with no neurologic deficits after 2 procedures.

Case 2

A 43-year-old woman had a sudden headache and vomiting. A brain CT indicated a dense SAH, and 3D-CTA revealed a dilatation and narrowing of the right VA, indicating a possible dissection. The diameters of both VAs were similar. The proximal VADAn included the origin of the PICA, and the central VADAn was hypothesized as the source of the SAH (Fig. 2A, B). Under general anesthesia, the ruptured central VADAn was internally trapped; the proximal VADAn, including the PICA origin, then was managed with stent placement from the VA to the PICA (Fig. 2C). After the stent insertion, tighter coil packing of the ruptured portion of the VADAn occurred. A postoperative VAG

demonstrated a completely occluded VADAn and well-preserved PICA flow through the stent, and the patient recovered well with no neurologic deficits (Fig. 2D). After 7 months, the VADAn recanalized. The recanalized VADAn was treated with additional coiling via the contralateral VA (Fig. 2E). The final angiogram revealed a complete occlusion of the VADAn and patent PICA flow (Fig. 2F).

Case 3

A 44-year-old woman presented with a sudden onset of headache, vomiting, and disturbance of consciousness. A brain CT revealed an SAH, and a 3D-CTA revealed bilateral VADAns (Fig. 3A). The VAG demonstrated that both aneurysms were located distal to the PICA (Fig. 3B), and the left VADAn had a bleb-like lesion, which was considered to be the source of the SAH (Fig. 3C). The ruptured left VADAn was internally completely trapped with detachable coils (Fig. 3D, E) immediately. Staged intervention was performed 1 week later. In order to preserve the flow, the right VADAn was treated using an endovascular stent-within-a-stent construct with 2 self-expandable intracranial stents. Although the control angiography revealed that the stents failed to completely exclude the aneurysm, definite stagnation of the contrast inside the aneurysm was achieved (Fig. 3F, G). The patient's postoperative course was uneventful, and she was discharged in excellent neurological condition ex-

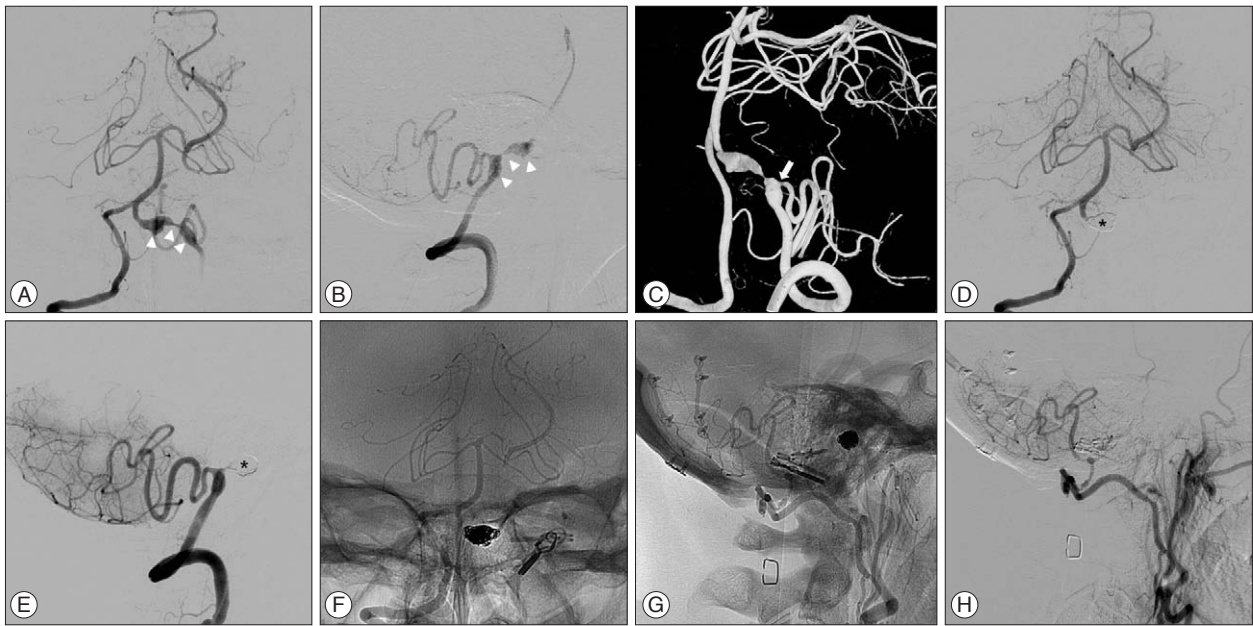


Fig. 1. Radiological findings of internal trapping and bypass surgery of a ruptured left vertebral artery dissecting aneurysm (VADAn). A and B : Two dilations and a stenosis (arrowheads) of the left vertebral artery (VA) are revealed on the right vertebral angiogram (VAG) frontal view (A) and the left VAG lateral view (B). These radiological findings reveal a VADAn with proximal and distal parts. C : A three-dimensional rotational angiogram shows the proximal part of the VADAn, including the origin of the posterior inferior cerebellar artery (PICA, arrow). Because of its irregular and lobulated features, the distal part of the VADAn is considered to be ruptured. D and E : The ruptured distal VADAn is successfully internally trapped with detachable coils (asterisks). F and G : Performing the surgical interventions of trapping with clip ligations to prevent rupture of the proximal part of the VADAn and occipital artery (OA)-PICA anastomosis to preserve PICA flow. H : The left external carotid angiogram shows well-preserved blood flow of PICA supplied from the OA-PICA anastomosis.

cept for mild diplopia. A 6-month follow-up VAG demonstrated that the left VA remained occluded. The right VA was remodeled and reconstituted, and the blood flow was preserved normally (Fig. 3H).

DISCUSSION

The undefined neck and fragile aneurysm wall of VADAn create an innate pathologic nature, including technical difficulties and risks of rupture when applying a microsurgical neck clip or performing endovascular coil embolization³³. To prevent the ruptured VADAn from rebleeding, surgical or endovascular proximal occlusion and external or internal trapping are safe and effective management strategies. However, these destructive techniques increase the risk of ischemic complications resulting from occlusion of the VA, PICA, and perforating arteries, which have a significant impact on the clinical outcome³. Revascularization and reconstructive treatments, including bypass surgery, stent-assisted coiling, and multiple stenting are necessary to prevent and minimize ischemic complications. To achieve the best treatment results, which include complete obliteration and preserved blood flow patency, precise treatment planning should occur following careful inspection of angiographic architecture in each individual case. We considered the angioarchitecture of VADAn in relation to the PICA location, VA dominance, and bilateral lesions, as described in Fig. 4.

We designed the treatment strategy to preserve PICA flow

patency if needed, because the PICA is the major artery supplying the posterior inferior cerebellar hemisphere, inferior portion of the vermis, and lower medulla. The VADAn were divided into 3 categories, according to the location of the VADAn from the origin of the PICA : supra-PICA, infra-PICA, and PICA-involved. Twelve of the 14 patients who had supra-PICA lesions with sufficient contralateral VA flow were treated with internal trapping, and the affected segments were successfully occluded. Anatomically, many perforators originate from the distal VA to the VBJ¹⁸. Therefore, longer sections of internal trapping in the distal VA segment were more prone to the fatal occlusion of perforators that supply the medulla oblongata^{7,30,33}. However, we attempted to occlude the affected ruptured VADAn segments over as long a section as possible. Due to the underlying nature of dissection, we hypothesized that the actual dissected vessel wall may be longer than the angiographic feature, and that the complete occlusion of the dissected site could therefore prevent rebleeding. Fortunately, there was no medullary infarction or any ischemia resulting from the occlusion of the perforating arteries when trapping occurred in cases of supra-PICA lesions. Of the 12 cases where internal trapping was used, 1 case involved stent-assisted trapping. In this case, the dissected section was just distal to the PICA, so we decided to deploy the stent from the VA to the PICA in order to preserve PICA flow. Several authors have reported the efficacy and safety of VA-PICA stenting with no stent occlusion, and midterm follow-up angiography revealed that PICA flow was patent without stenosis or occlusion^{4,12}.

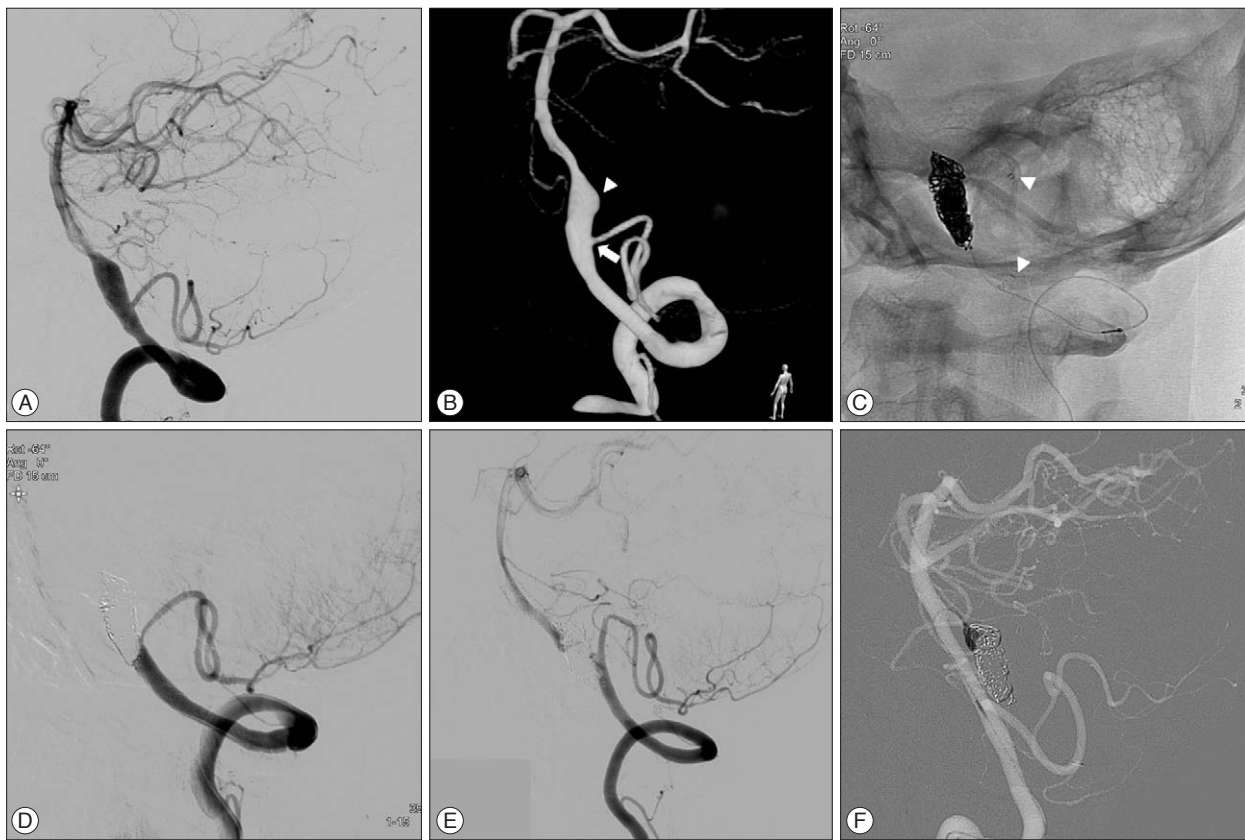


Fig. 2. Radiologic findings of stent-assisted trapping of the ruptured right vertebral artery dissecting aneurysm (VADAn). A : The right vertebral angiogram (VAG) displays a dilatation and narrowing of the right vertebral artery (VA) that is considered a dissection. B : The three-dimensional rotational angiogram shows the proximal part of the VADAn, including the origin of the posterior inferior cerebellar artery (PICA, arrow), and the central VADAn is regarded as the ruptured point (arrowhead). C : Performing a successful internal trapping on the VADAn just distal to the origin of the PICA with stent placement from the VA to the PICA (arrowheads indicate both ends of the stent). D : Postoperative VAG reveals a completely occluded VADAn and well-preserved PICA flow through the stent. E : Follow-up angiogram after 7 months demonstrates recanalization of the previously trapped VADAn and blood flow of the basilar artery through the VADAn. F : Treating the recanalized VADAn with additional coiling via the contralateral VA; the VADAn was successfully occluded.

There was only 1 infra-PICA VADAn case that was treated with internal trapping in this study. Similar to our results, other studies have found that infra-PICA lesions are relatively rare compared to supra-PICA lesions, and internal trapping has provided reliable management in cases with sufficient blood flow from the contralateral VA^{9,26,33}.

The treatment of PICA-involved VADAn remains difficult and controversial. Some authors argue that PICA occlusion does not result in severe disability, due to sufficient collaterals; however, the ideal treatment for a PICA-involved aneurysm is trapping and PICA reconstruction³⁰. Therefore, endovascular segmental occlusion using coils, followed by PICA-to-PICA side anastomosis or OA-PICA revascularization, has been performed in many cases^{5,26,30}. In our study, 2 patients had partial trapping using coils to reduce the rebleeding risk immediately after diagnostic angiography, which was followed by surgical trapping after the OA-PICA bypass.

We applied the stent-assisted technique, according to our extensive experience, to PICA-involved VADAn. Two stent-assisted coiling procedures and 1 stent-assisted trapping procedure

were performed. The clinical outcomes were favorable for these patients, and postoperative angiography indicated complete occlusion. Stent-assisted coiling has several advantages : 1) maintaining the patency of the parent artery, and therefore preventing ischemic complications; 2) forming an aneurysmal neck, which allows coil placement; 3) altering hemodynamics and inducing thrombosis into the aneurysmal sac; and 4) attaching the intimal flap to the vessel wall and reducing the size of pseudoaneurysms^{26,31}.

ECOPICAs, excluding the intradural origin of PICAs, have specific anatomical characteristics. Notably, the perforating arteries supplying the lateral surface of the brainstem originate from the VA not the PICA²⁰. Consequently, there are risks of lateral medullary infarction as a result of internal trapping of the VA, even when the ECOPICA is preserved. In the present study, of the 6 VADAn with ECOPICAs, 5 were supra-PICA cases and 1 was a PICA-involved case. All lesions were treated with internal trapping. We had concerns regarding potential brainstem infarction, but these events did not occur. Although ECOPICAs were observed relatively often and had anatomical features that

should be considered when treating VADAn, we did not find evidence that these features affected treatment or prognosis.

VA dominance is another important angiographic factor in treating VADAn. When the affected segment is on the dominant

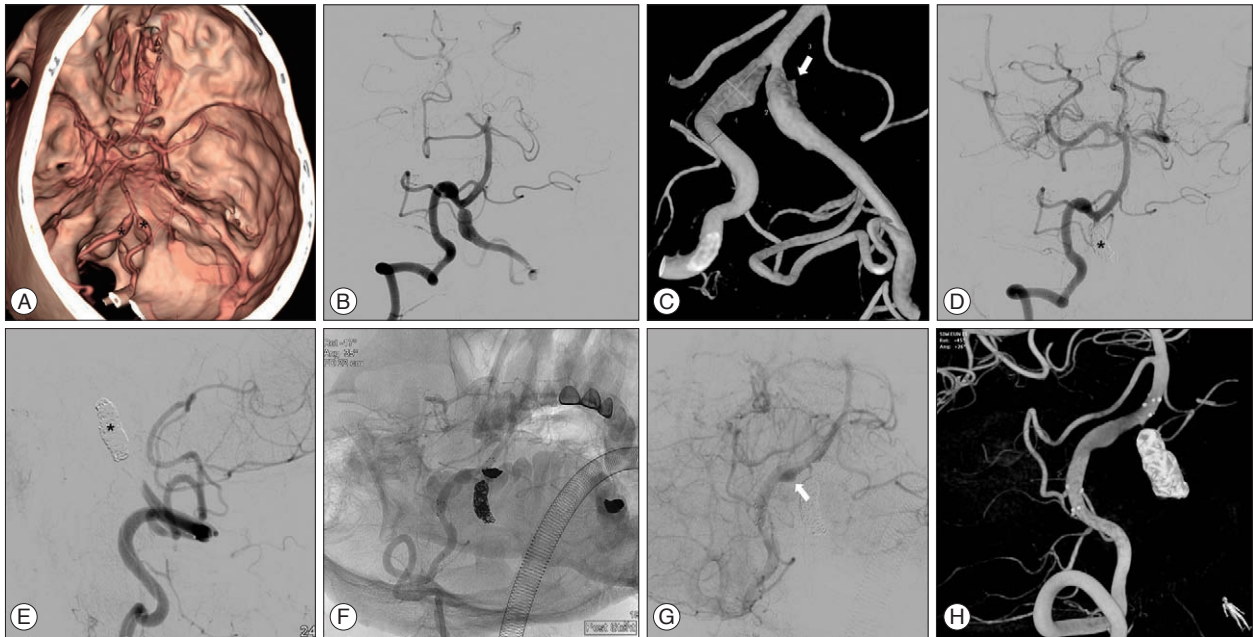


Fig. 3. Radiologic findings of endovascular treatment of bilateral vertebral artery dissecting aneurysms (VADAn). A : Three-dimensional brain computed tomography angiography demonstrates bilateral VADAn (asterisks). B : The vertebral angiogram (VAG) shows the dissecting aneurysms in the intracranial portion of the bilateral VAs. C : The three-dimensional rotational angiogram demonstrates that the left VADAn has a bleb-like lesion, which is considered to be the source of the SAH (arrow). D and E : A left VAG obtained immediately after the endovascular trapping using detachable coils (asterisk) shows the complete obliteration of the ruptured VADAn distal to the PICA. F : The right VAG after the staged intervention shows 2 overlapping stents in the dissected vessel. G : After deploying 2 overlapping stents, the definite stagnation of contrast inside the aneurysm is achieved (arrow). H : The three-dimensional rotational angiogram of the right VA demonstrates remodeling of the left VADAn by 2 overlapping stents.

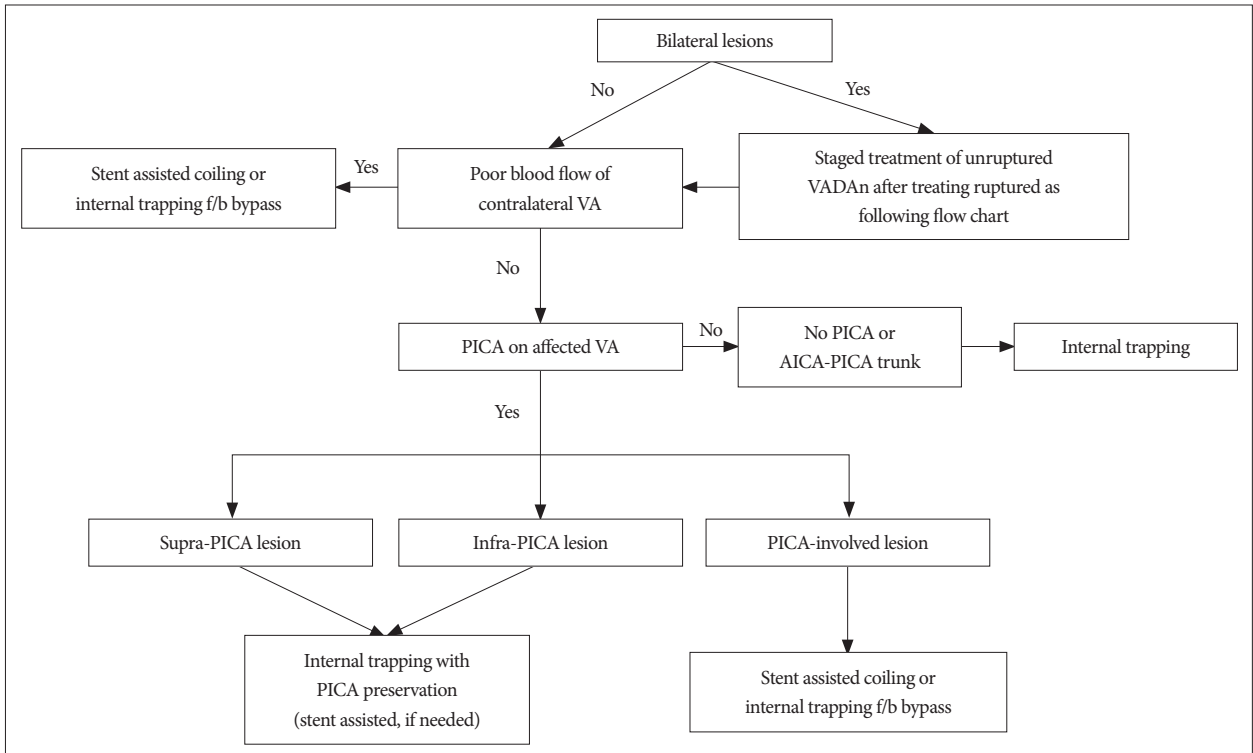


Fig. 4. Flow chart for treating a ruptured vertebral artery dissecting aneurysm. VA : vertebral artery, VADAn : vertebral artery dissecting aneurysm, f/b : followed by, PICA : posterior inferior cerebellar artery, AICA : anterior inferior cerebellar artery.

VA, trapping and proximal occlusion can cause fatal ischemia. Therefore, the treatment strategy should be planned to preserve VA and basilar artery patency during and after treatment. Theoretically, the balloon occlusion test (BOT) provides valuable information regarding collateral flows, but BOT is not always recommended during the acute bleeding stage²⁶. We treated 3 cases with stent-assisted coiling for a total of 4 lesions of the dominant VA without BOT. All 3 VADAn were successfully occluded, and the dominant VA flows were preserved.

VADAn sometimes occur bilaterally^{14,25}. The known pathogenesis for bilateral presentation is spontaneous dissection, which involves pre-existing vessel wall defects that typically present with symmetric distribution³³. These characteristics predispose the arteries to an increased risk of contralateral VADAn rupture via hemodynamic changes resulting from the occlusion of ipsilateral ruptured VA segments. We performed subsequent staged EVT on contralateral unruptured aneurysms as a strategy to avoid future rupture.

Although there was no angiographic result of VADAn that involved the anterior spinal artery (ASA) in this series, ASA is one of considerable anatomical factors in treating VADAn. The ASA arises from near the termination of VA bilaterally in 45.5%, and the bilateral ASAs joins together at a distance to the VBJ from 1.6 mm to 7.1 mm (mean 4.8 mm)¹⁹. It has a number of small perforating branches that supply the anterior surface of the medulla and anterior two thirds of the upper cervical cord³², and occlusion of the ASA results in infarction of medial or lateral part of medulla oblongata and spinal cord ischemia¹⁹. Because of presence of anastomoses among the perforators of VA, PICA, ASA, and BA, occlusion does not always lead to ischemia of brain stem and spinal cord¹⁰. However we cannot sure that the frequency and the number of their anastomoses are sufficient enough to avoid ischemia, the result of occlusion is uncertain¹⁹. Therefore, in cases of VADAn associated with ASA involvement, proximal occlusion or multiple stenting are preferred to consider for preventing ischemia of brain stem and spinal cord.

Several potential technique related complications of EVT have been reported, including aneurysm rupture, VA branch occlusion, hemodynamic compromise of the vertebrobasilar system resulting from vertebral artery occlusion, and recanalization of occluded vessels^{15,27}. In the present study, rebleeding occurred in 2 patients during EVT. MacKay et al.¹⁷ proposed that stent-assisted coiling of the dissection might cause a dissection rupture or lead to recanalization if the coil migrates through the dissected vessel wall. Rebleeding during the endovascular procedure was successfully managed with additional compact coil insertion or rescue stent placement combined with a reversal of the anticoagulant. There were 5 complications recorded in this study : 2 patients developed rebleeding at the end of the coiling procedure, 1 patient developed symptomatic medullary infarction, and 2 patients experienced recanalization of the VADAn after the first EVT. Taha et al.²⁷ reported 8% recanalization during the perioperative period after complete internal trapping.

Therefore, we propose that follow-up angiography is necessary during the perioperative period even when EVT is considered successful.

The prediction of patient outcomes following a ruptured VADAn is important because these events are associated with high morbidity and mortality. Previous studies have suggested the initial stroke severity, including National Institute of Health Stroke Scale score, and patient age as prognostic factors^{2,6}. In the present study, of the 10 patients with poor initial clinical grade (HHG IV or V), clinical outcomes were favorable in 3 patients (e.g., good recovery, moderate disability) and unfavorable in 7 patients (e.g., severe disability, persistent vegetative state, and death). Conversely, among the 16 patients with an initial FG IV, 8 patients (50%) experienced favorable clinical outcomes and 8 patients (50%) had unfavorable outcomes. Our findings therefore demonstrate that the initial clinical state is a good predictor of clinical outcome, and initial HHG scores are better predictors than FG scores.

This study does have some limitations. First, the size of the study population is relatively small. However, given that most of treatment options were used in this study and considering low incidence of the ruptured VADAn, this study could strengthen the fact of usefulness of EVTs for VADAn. Second, this study was a retrospective study in which the data were acquired through a retrospective chart review. Thus, it is thought that a prospective study using a larger number of patients will be necessary to determine the safety and effectiveness of EVTs for VADAn with the concept of prompt application of treatment.

CONCLUSION

Ruptured VADAn should be treated as soon as possible because of the high risk of rebleeding and mortality. EVT has been demonstrated as safe and effective for ruptured VADAn because of its easy accessibility, minimal invasiveness, and rapid treatment potential after diagnostic angiography. Recent advancements in stent-assisted techniques, including stent-assisted coiling, enable both destructive (internal trapping) and reconstructive (preservation of VA and PICA patency) treatments. The careful selection of an appropriate EVT technique following the meticulous inspection of the angioarchitecture, including the location of the PICA origin, VA dominance, and bilateral lesions, is mandatory for successful treatment outcomes with low complication risks.

References

1. Aoki N, Sakai T : Rebleeding from intracranial dissecting aneurysm in the vertebral artery. *Stroke* 21 : 1628-1631, 1990
2. Arnold M, Bousser MG, Fahrni G, Fischer U, Georgiadis D, Gandjour J, et al : Vertebral artery dissection : presenting findings and predictors of outcome. *Stroke* 37 : 2499-2503, 2006
3. Chen YA, Qu RB, Bian YS, Zhu W, Zhang KP, Pang Q : Stent placement to treat ruptured vertebral dissecting aneurysms. *Interv Neuroradiol* 19 : 479-482, 2013
4. Chung J, Kim BS, Lee D, Kim TH, Shin YS : Vertebral artery occlusion

- with vertebral artery-to-posterior inferior cerebellar artery stenting for preservation of the PICA in treating ruptured vertebral artery dissection. *Acta Neurochir (Wien)* 152 : 1489-1492, 2010
5. Chung SY, Yoon BH, Park MS, Kim SM : A case of endovascular treatment for followed by side to side bypass for vertebral artery dissecting aneurysms involved posterior inferior cerebellar artery. *J Korean Neurosurg Soc* 55 : 36-39, 2014
 6. de Bray JM, Penisson-Besnier I, Dubas F, Emile J : Extracranial and intracranial vertebrobasilar dissections : diagnosis and prognosis. *J Neurol Neurosurg Psychiatry* 63 : 46-51, 1997
 7. Endo H, Matsumoto Y, Kondo R, Sato K, Fujimura M, Inoue T, et al. : Medullary infarction as a poor prognostic factor after internal coil trapping of a ruptured vertebral artery dissection. *J Neurosurg* 118 : 131-139, 2013
 8. Hamada J, Kai Y, Morioka M, Yano S, Todaka T, Ushio Y : Multimodal treatment of ruptured dissecting aneurysms of the vertebral artery during the acute stage. *J Neurosurg* 99 : 960-966, 2003
 9. Hamasaki O, Ikawa F, Hidaka T, Kurokawa Y, Yonezawa U : Treatment of ruptured vertebral artery dissecting aneurysms. A short report. *Interv Neuroradiol* 20 : 304-311, 2014
 10. Hsu CY, Cheng CY, Lee JD, Lee M, Huang YC, Wu CY, et al. : Clinical features and outcomes of spinal cord infarction following vertebral artery dissection : a systematic review of the literature. *Neurol Res* 35 : 676-683, 2013
 11. Iihara K, Sakai N, Murao K, Sakai H, Higashi T, Kogure S, et al. : Dissecting aneurysms of the vertebral artery : a management strategy. *J Neurosurg* 97 : 259-267, 2002
 12. Kim MJ, Chung J, Kim SL, Roh HG, Kwon BJ, Kim BS, et al. : Stenting from the vertebral artery to the posterior inferior cerebellar artery. *AJNR Am J Neuroradiol* 33 : 348-352, 2012
 13. Kitanaka C, Morimoto T, Sasaki T, Takakura K : Rebleeding from vertebral artery dissection after proximal clipping. Case report. *J Neurosurg* 77 : 466-468, 1992
 14. Koh JS, Ryu CW, Lee SH, Bang JS, Kim GK : Bilateral vertebral-artery-dissecting aneurysm causing subarachnoid hemorrhage cured by staged endovascular reconstruction after occlusion. *Cerebrovasc Dis* 27 : 202-204, 2009
 15. Luo CB, Chang CY, Teng MM, Chang FC : Endovascular treatment of ruptured vertebral dissecting aneurysms with electrodetachable coils. *J Chin Med Assoc* 68 : 578-584, 2005
 16. Lylyk P, Ceratto R, Hurvitz D, Basso A : Treatment of a vertebral dissecting aneurysm with stents and coils : technical case report. *Neurosurgery* 43 : 385-388, 1998
 17. MacKay CI, Han PP, Albuquerque FC, McDougall CG : Recurrence of a vertebral artery dissecting pseudoaneurysm after successful stent-supported coil embolization : case report. *Neurosurgery* 53 : 754-759; discussion 760-761, 2003
 18. Mahmood A, Dujovny M, Torche M, Dragovic L, Ausman JI : Microvascular anatomy of foramen caecum medullae oblongatae. *J Neurosurg* 75 : 299-304, 1991
 19. Marinković S, Milisavljević M, Gibo H, Maliković A, Djulejić V : Microsurgical anatomy of the perforating branches of the vertebral artery. *Surg Neurol* 61 : 190-197; discussion 197, 2004
 20. Mercier PH, Brassier G, Fournier HD, Picquet J, Papon X, Lasjaunias P : Vascular microanatomy of the pontomedullary junction, posterior inferior cerebellar arteries, and the lateral spinal arteries. *Interv Neuroradiol* 14 : 49-58, 2008
 21. Mizutani T, Aruga T, Kirino T, Miki Y, Saito I, Tsuchida T : Recurrent subarachnoid hemorrhage from untreated ruptured vertebrobasilar dissecting aneurysms. *Neurosurgery* 36 : 905-911; discussion 912-913, 1995
 22. Ramgren B, Cronqvist M, Romner B, Brandt L, Holtås S, Larsson EM : Vertebrobasilar dissection with subarachnoid hemorrhage : a retrospective study of 29 patients. *Neuroradiology* 47 : 97-104, 2005
 23. Santos-Franco JA, Zenteno M, Lee A : Dissecting aneurysms of the vertebrobasilar system. A comprehensive review on natural history and treatment options. *Neurosurg Rev* 31 : 131-140; discussion 140, 2008
 24. Schievink WI : Spontaneous dissection of the carotid and vertebral arteries. *N Engl J Med* 344 : 898-906, 2001
 25. Shin YS, Kim BM, Kim SH, Suh SH, Ryu CW, Koh JS, et al. : Endovascular treatment of bilateral intracranial vertebral artery dissecting aneurysms presenting with subarachnoid hemorrhage. *Neurosurgery* 70 (1 Suppl Operative) : 75-81; discussion 81, 2012
 26. Su W, Gou S, Ni S, Li G, Liu Y, Zhu S, et al. : Management of ruptured and unruptured intracranial vertebral artery dissecting aneurysms. *J Clin Neurosci* 18 : 1639-1644, 2011
 27. Taha MM, Sakaida H, Asakura F, Maeda M, Toma N, Yamamoto A, et al. : Endovascular management of vertebral artery dissecting aneurysms : review of 25 patients. *Turk Neurosurg* 20 : 126-135, 2010
 28. Tsukahara T, Wada H, Satake K, Yaoita H, Takahashi A : Proximal balloon occlusion for dissecting vertebral aneurysms accompanied by subarachnoid hemorrhage. *Neurosurgery* 36 : 914-919; discussion 919-920, 1995
 29. Yamaura A, Watanabe Y, Saeki N : Dissecting aneurysms of the intracranial vertebral artery. *J Neurosurg* 72 : 183-188, 1990
 30. Yamaura I, Tani E, Yokota M, Nakano A, Fukami M, Kaba K, et al. : Endovascular treatment of ruptured dissecting aneurysms aimed at occlusion of the dissected site by using Guglielmi detachable coils. *J Neurosurg* 90 : 853-856, 1999
 31. Yoon WK, Kim YW, Kim SR, Park IS, Kim SD, Jo KW, et al. : Angiographic and clinical outcomes of stent-alone treatment for spontaneous vertebrobasilar dissecting aneurysm. *Acta Neurochir (Wien)* 152 : 1477-1486; discussion 1486, 2010
 32. Zhang Z, Wang H, Zhou Y, Wang J : Computed tomographic angiography of anterior spinal artery in acute cervical spinal cord injury. *Spinal Cord* 51 : 442-427, 2013
 33. Zhao WY, Krings T, Alvarez H, Ozanne A, Holmin S, Lasjaunias P : Management of spontaneous haemorrhagic intracranial vertebrobasilar dissection : review of 21 consecutive cases. *Acta Neurochir (Wien)* 149 : 585-596; discussion 596, 2007