

The Natural Course of Endobronchial Inflammatory Polyps as a Complication after Endobronchial Ultrasound-Guided Transbronchial Needle Aspiration

Kyu Min Lee, M.D.^{1,*}, Sun Mi Jang, M.D.^{1,*}, Seo Young Oh, M.D.¹, Do Young Kim, M.D.¹, Geewon Lee, M.D.², Ahrong Kim, M.D.³, Min Ji Kim, M.D.¹, Tae Hwa Kim, M.D.¹, Joon Woo Park, M.D.¹, Kwangha Lee, M.D.¹, Ki Uk Kim, M.D.¹, Min Ki Lee, M.D.¹ and Jung Seop Eom, M.D.¹

Departments of ¹Internal Medicine, ²Radiology, and ³Pathology, Pusan National University School of Medicine, Busan, Korea

We presented a case of unusual endobronchial inflammatory polyps as a complication following endobronchial ultrasound-guided transbronchial needle aspiration (EBUS-TBNA) in a patient with tuberculous lymphadenitis. EBUS-TBNA of the right hilar lymph node was performed in a 29-year-old, previously healthy man. The patient was confirmed with tuberculous lymphadenitis and received antituberculosis medication over the course of 6 months. Chest computed tomography, after 6 months of antituberculosis therapy following the EBUS-TBNA showed nodular bronchial wall thickening of the right main bronchus. Histological and microbiological examinations revealed inflammatory polyps. After 7 months, the inflammatory polyps regressed almost completely without need for removal.

Keywords: Needles; Complications; Lymphadenitis; Polyps; Tuberculosis

Introduction

Endobronchial ultrasound-guided transbronchial needle aspiration (EBUS-TBNA) is a useful technique for investigating patients with various mediastinal diseases¹⁻³. Although EBUS-TBNA is generally considered to be safe, various com-

plications are occasionally reported with the recent widespread use of EBUS-TBNA, including hemorrhage, infection, and inflammatory polyps⁴⁻⁶.

Reports have described the successful removal of inflammatory polyps, which had developed after EBUS-TBNA, using biopsy forceps⁶. However, the natural clinical course of inflammatory polyps after EBUS-TBNA is still unclear. We report a patient with tuberculous lymphadenitis who developed inflammatory polyps 6 months after EBUS-TBNA, but did not undergo polyp removal, and discuss the natural progression of the polyps over the course of 7 months.

Case Report

A 29-year-old man visited our clinic with a 1-month history of a dry cough and night sweats. He had been healthy and had no specific family medical history related to these symptoms. Chest computed tomography (CT) showed conglomerated, enlarged lymph nodes with central necrosis in the right upper paratracheal, both lower paratracheal, subcarinal, and right

Address for correspondence: Jung Seop Eom, M.D.

Department of Internal Medicine, Pusan National University School of Medicine, 179 Gudeok-ro, Seo-gu, Busan 49241, Korea

Phone: 82-51-240-7889, **Fax:** 82-51-254-3127

E-mail: ejspulm@gmail.com

*Kyu Min Lee and Sun Mi Jang contributed equally to this work.

Received: May 10, 2015

Revised: Jun. 11, 2015

Accepted: Jun. 29, 2015

© It is identical to the Creative Commons Attribution Non-Commercial License (<http://creativecommons.org/licenses/by-nc/4.0/>).

Copyright © 2015

The Korean Academy of Tuberculosis and Respiratory Diseases.

All rights reserved.

hilar areas (Figure 1A). Since no endobronchial lesion was visible on flexible bronchoscopy (BF-1T260; Olympus, Tokyo, Japan) (Figure 1B), we performed EBUS-TBNA (BF-UC260F-OL8; Olympus) to examine the right lower paratracheal and hilar lymph nodes histologically and microbiologically (Figure 1C). Chronic granulomatous inflammation with necrosis was evident (Figure 1D), and the EBUS-TBNA samples stained

positively for acid-fast bacilli (AFB). As the histological findings of tuberculosis and positive AFB staining were compatible, we prescribed standard anti-tuberculosis treatment. Subsequently, although the post-bronchoscopy sputum specimen stained negatively for AFB, *Mycobacterium tuberculosis* was cultured. Sputum tests performed 1 month after initiating anti-tuberculosis treatment were AFB staining- and culture-

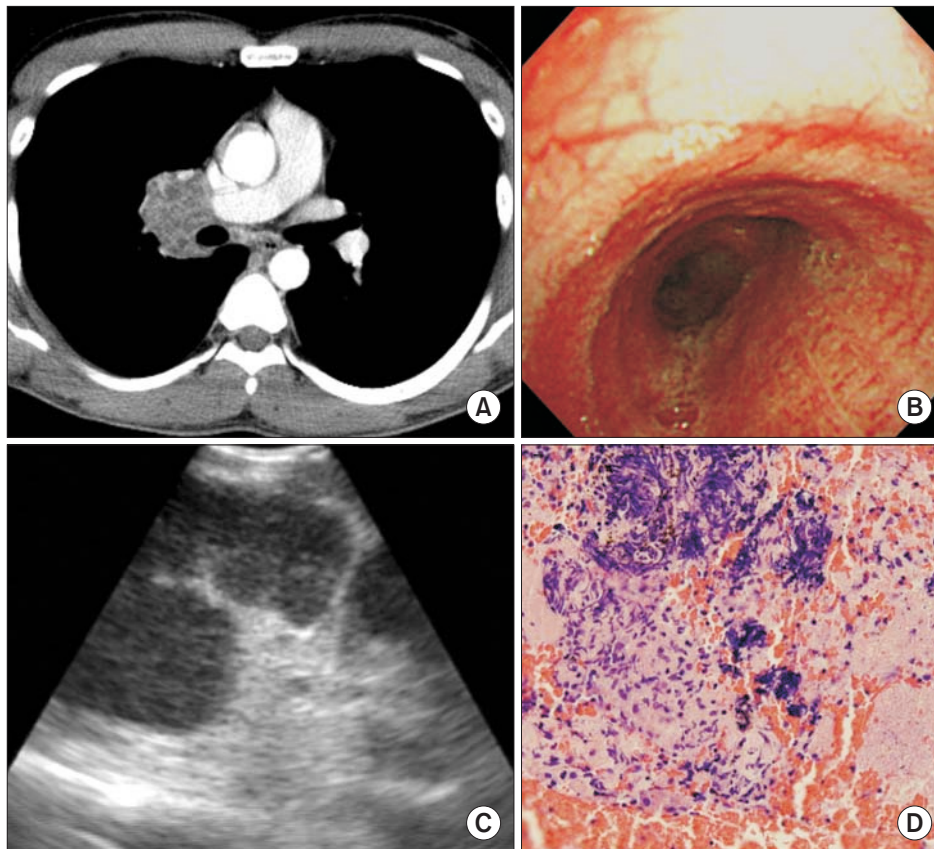


Figure 1. A 29-year-old male with tuberculous lymphadenitis of the right upper paratracheal, both lower paratracheal, subcarinal, and right hilar lymph nodes. (A) Initial chest computed tomography shows conglomerated, enlarged lymph nodes with central necrosis in the right hilar area. (B) No endobronchial lesion was found at the right main bronchus or secondary carina on initial flexible bronchoscopy. (C) An endobronchial ultrasound image of the right lower paratracheal and hilar lymph nodes showed a hypoechoic texture, and transbronchial needle aspiration was performed under real-time ultrasound guidance. (D) The histopathology showed chronic granulomatous inflammation with necrosis (H&E stain, $\times 400$).

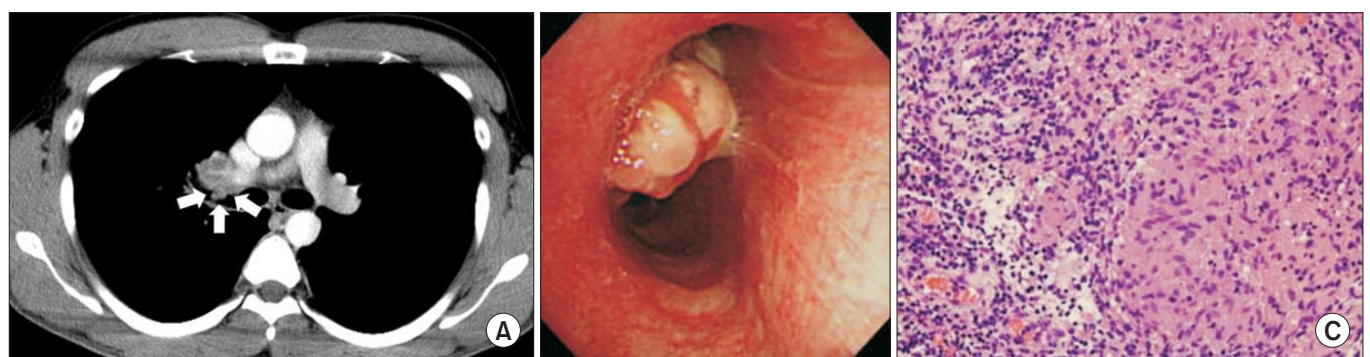


Figure 2. Computed tomography was performed to assess the treatment response after 6 months of antituberculosis treatment. (A) A newly developed endobronchial lesion was found on computed tomography (arrows). (B) Lobulating nodular lesions at the distal right main bronchus and right secondary carina were noted on flexible bronchoscopy. (C) Forceps biopsy of the newly developed endobronchial lesions revealed chronic granulomatous inflammation (H&E stain, $\times 400$).

negative.

After 6 months of antituberculosis treatment, CT was performed to assess the patient's response to treatment. Although the lymph nodes had decreased in size in comparison with the baseline CT, new endobronchial lesions were discovered in the right main bronchus (Figure 2A). Flexible bronchoscopy showed lobulating endobronchial lesions in the distal right main bronchus and right secondary carina (Figure 2B). A forceps biopsy of the endobronchial lesions revealed chronic granulomatous inflammation (Figure 2C). AFB cultures and tuberculosis–polymerase chain reaction using bronchial washing and tissue samples were negative. The lobulating endobronchial lesions were therefore diagnosed as endobronchial inflammatory polyps.

Since the patient was asymptomatic, we observed the natural course of the polyps without resorting to their removal. Flexible bronchoscopy was performed 3 months later and the size of the endobronchial inflammatory polyps was found to have significantly decreased (Figure 3A, B). Moreover, the endobronchial inflammatory polyps had almost disappeared on bronchoscopy after 7 months (Figure 3C, D).

Discussion

No report has followed the natural course of endobronchial inflammatory polyps following EBUS-TBNA. Our case showed that endobronchial inflammatory polyps, as a complication of EBUS-TBNA, could regress spontaneously without treatment. Therefore, this report may help in the management of asymptomatic endobronchial inflammatory polyps following EBUS-TBNA.

According to Dixit et al.⁷, the stroma of inflammatory polyps has a variable appearance depending on the number of blood vessels, the nature of the connective tissue, and the severity of the inflammatory cellular infiltrate. Samter proposed a process explaining the development of the polyps; a variety of injuries including trauma, secondary infection, and sensitization to bacteria or to other agents leads to increased capillary permeability and the immigration of inflammatory cells, causing vascular congestion and tissue edema. The pressure of this fluid pushes the mucous membrane forward, giving rise first to folds and projections and then to massive mucosal herniates in the respiratory tract⁸.

Compatible bronchoscopic and histological findings are re-

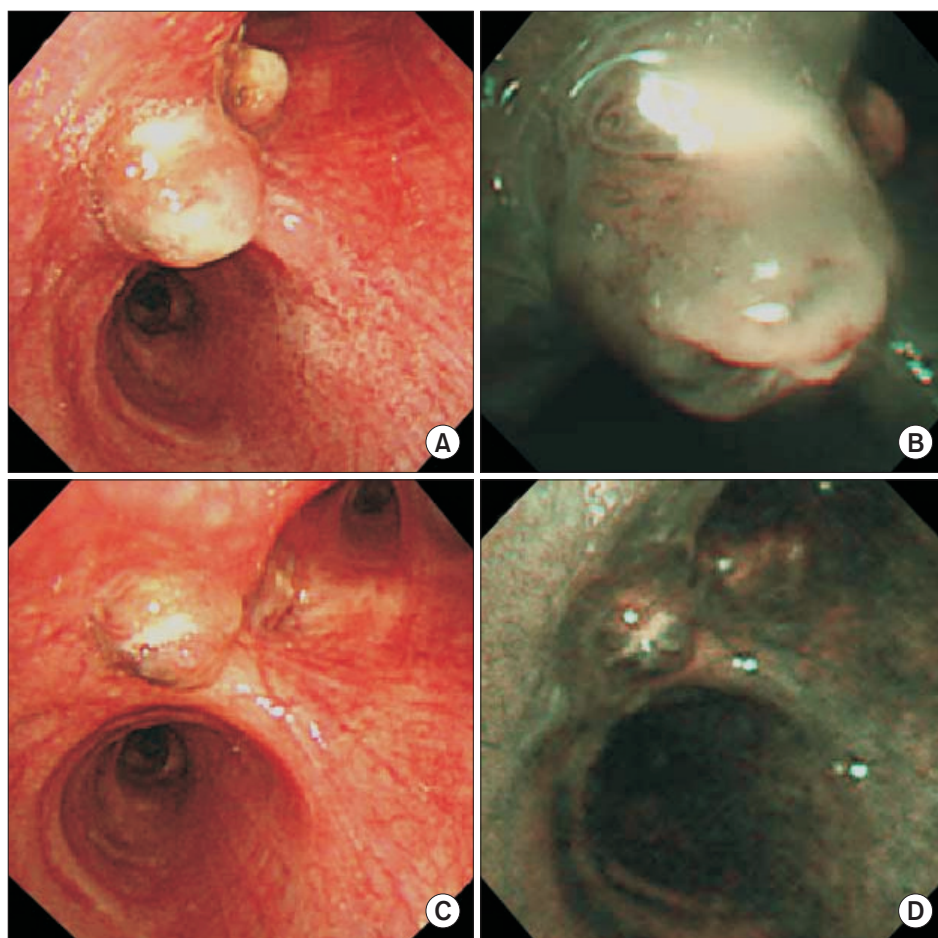


Figure 3. The natural course of the inflammatory polyps. (A) After 3 months, flexible bronchoscopy indicated a decreased size of the endobronchial inflammatory polyps. (B) A narrow-band imaging bronchoscopic scan taken after 3 months. (C) After 7 months, the endobronchial inflammatory polyps had spontaneously regressed almost completely. (D) A narrow-band imaging bronchoscopic scan taken after 7 months.

quired to diagnose an inflammatory polyp^{9,10}. In addition, both tuberculosis and inflammatory polyps show granulomatous inflammation histologically, making them difficult to distinguish using this technique alone. We observed that a polypoid lesion developed in the right bronchial tree after EBUS-TBNA. Staining of forceps biopsy material revealed chronic granulomatous inflammation. However, AFB cultures of polypoid tissue and a polymerase chain reaction for detecting *M. tuberculosis* were negative. Moreover, the inflammatory polypoid lesions essentially disappeared in the absence of further anti-tuberculosis treatment. This means that the inflammatory polyps were attributable to EBUS-TBNA, and not tuberculous inflammation.

Cases of inflammatory polyps following EBUS-TBNA are rare. In a previous case, because the patient had symptoms, including cough and dyspnea, the inflammatory polyps had to be removed. Therefore, it was difficult to recognize the natural progression of the inflammatory polyps⁶. However, our patient was asymptomatic and so we were able to observe the natural course over several months without removing the polyps. As a result, the polyps spontaneously regressed.

In conclusion, we found that endobronchial inflammatory polyps after EBUS-TBNA can regress spontaneously without treatment. Unless endobronchial inflammatory polyps lead to respiratory symptoms, observation without removal of the polyps is a reasonable treatment option.

Conflicts of Interest

No potential conflict of interest relevant to this article was reported.

Acknowledgements

This study was supported by a clinical research grant from the Biomedical Research Institute, Pusan National University Hospital (2015).

References

1. Navani N, Molyneaux PL, Breen RA, Connell DW, Jepson A, Nankivell M, et al. Utility of endobronchial ultrasound-guided transbronchial needle aspiration in patients with tuberculous intrathoracic lymphadenopathy: a multicentre study. *Thorax* 2011;66:889-93.
2. Kokkonouzis I, Strimpakos AS, Lampaditis I, Tsimpanoukis S, Syrigos KN. The role of endobronchial ultrasound in lung cancer diagnosis and staging: a comprehensive review. *Clin Lung Cancer* 2012;13:408-15.
3. Kang HJ, Hwangbo B. Technical aspects of endobronchial ultrasound-guided transbronchial needle aspiration. *Tuberc Respir Dis* 2013;75:135-9.
4. Asano F, Aoe M, Ohsaki Y, Okada Y, Sasada S, Sato S, et al. Complications associated with endobronchial ultrasound-guided transbronchial needle aspiration: a nationwide survey by the Japan Society for Respiratory Endoscopy. *Respir Res* 2013;14:50.
5. von Bartheld MB, van Breda A, Annema JT. Complication rate of endosonography (endobronchial and endoscopic ultrasound): a systematic review. *Respiration* 2014;87:343-51.
6. Gupta R, Park HY, Kim H, Um SW. Endobronchial inflammatory polyp as a rare complication of endobronchial ultrasound-transbronchial needle aspiration. *Interact Cardiovasc Thorac Surg* 2010;11:340-1.
7. Dixit R, George J, Dave L, Rai SM. Endobronchial inflammatory polyp. *J Indian Acad Clin Med* 2010;11:312-5.
8. Samter M. Nasal polyps: an inquiry into the mechanism of formation. *Arch Otolaryngol* 1961;73:334-41.
9. Smith RE. Endobronchial polyp and chronic smoke injury. *Postgrad Med J* 1989;65:785-7.
10. Rosenberg JC. Bronchial polyps of inflammatory origin. *J Thorac Cardiovasc Surg* 1969;57:848-52.