

Lung Disease Caused by *Mycobacterium malmoense* in an Immunocompetent Patient

Min Kyung Jeon, M.D.¹, Jung A Yoon, M.D.¹, Junhwan Kim, M.D.¹, Sangyoung Yi, M.D.¹, Heungsup Sung, M.D. Ph.D.², Tae Sun Shim, M.D. Ph.D.³ and Kyung-Wook Jo, M.D.³

¹Department of Internal Medicine, ²Department of Laboratory Medicine, and ³Division of Pulmonary and Critical Care Medicine, Asan Medical Center, University of Ulsan College of Medicine, Seoul, Korea

Mycobacterium malmoense is a very rare cause of lung disease in South Korea. We reported the first case of lung disease caused by *M. malmoense* in an immunocompetent patient. The patient was successfully treated with a 14-month course of antibiotics.

Keywords: Mycobacterium Infections; Nontuberculous Mycobacteria; Therapy

Introduction

Because non-tuberculous mycobacteria (NTM) are increasingly recognized as human pathogens, NTM disease is an emerging public health threat. *Mycobacterium avium* complex is the most common lung disease-causing NTM pathogen in South Korea; the second most common is *M. abscessus* complex^{1,2}. Although *M. malmoense*, a slow-growing non-photochromogenic mycobacterium, is the second most common cause of NTM lung disease in northern Europe³, there have been no reported cases in South Korea. Here, we report the first case of *M. malmoense* pulmonary infection in an immunocompetent patient.

Address for correspondence: Kyung-Wook Jo, M.D.

Division of Pulmonary and Critical Care Medicine, Asan Medical Center, University of Ulsan College of Medicine, 88 Olympic-ro 43-gil, Songpa-gu, Seoul 138-736, Korea

Phone: 82-2-3010-5783, **Fax:** 82-2-3010-6968

E-mail: heathcliff6800@hanmail.net

Received: Feb. 23, 2015

Revised: Apr. 7, 2015

Accepted: Apr. 21, 2015

©It is identical to the Creative Commons Attribution Non-Commercial License (<http://creativecommons.org/licenses/by-nc/4.0/>).

Copyright © 2015

The Korean Academy of Tuberculosis and Respiratory Diseases.

All rights reserved.

Case Report

A 66-year-old man visited our hospital, Asan Medical Center, due to a cough persisting for 5 months. Seven years earlier, he had been treated for pan-susceptible pulmonary tuberculosis (TB), which lasted for 9 months. This treatment was successful but a chest X-ray (CXR) at the time of treatment completion showed parenchymal destructive lesions, with fibrotic changes in the right upper lung field (Figure 1). He also suffered from a mild chronic cough. He remained relatively well thereafter. A CXR taken about 1 year earlier showed no significant changes in the TB-destroyed lung. However, his cough became aggravated 6 months prior to presentation at our clinic.

Physical examination revealed that the patient was alert and not in distress. His vital signs were as follows: temperature, 35.6°C; blood pressure, 123/78 mm Hg; pulse, 63 beats per minute (with a regular rhythm); and respiratory rate, 20 breaths per minute. Auscultation revealed decreased breath sounds in the right upper anterior chest. Blood tests showed a white blood cell count of 7,500/mm³ (67% neutrophils); hemoglobin, 12.6 g/dL; and a platelet count of 268,000/mm³. Routine chemical laboratory data were all within the normal ranges. The patient was negative for antibodies to human immunodeficiency virus.

Compared with the CXR taken 6 years earlier, his CXR showed increased infiltration of the right middle lung field, with small nodular densities (Figure 2A). A chest computed tomography (CT) scan revealed a newly developed segmental centrilobular nodular lesion in the right lung (Figure 2B, C).

Smears and cultures of multiple sputum specimens were positive for acid-fast bacilli, which a GenoType Mycobacterium Assay (Hain Diagnostika, Nehren, Germany) identified as *M.*

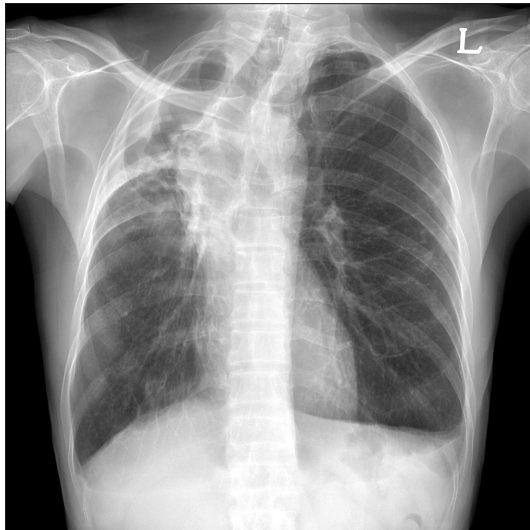


Figure 1. Chest X-ray taken 7 years earlier showing parenchymal destruction, fibrotic lesions, and bullous changes in the right upper lung field caused by a previous episode of pulmonary tuberculosis.

malmoense (Table 1).

Based on these clinical and laboratory data, the patient was given a diagnosis of lung disease caused by *M. malmoense*, according to the American Thoracic Society (ATS) criteria. *M. malmoense* was subjected to several rounds of drug susceptibility testing; however, all failed due to contamination. The patient was treated with oral isoniazid, rifampicin, ethambutol, moxifloxacin, and clarithromycin, and his symptoms improved rapidly. Sputum culture conversion was observed after 2 months. Due to the improved clinical course, moxifloxacin was stopped 8 months after initiation. Also, we had to discontinue ethambutol after 10 months due to the onset of optic neuropathy. Treatment was completed 12 months after achieving sputum culture conversion (i.e., treatment lasted 14 months in total). A CXR and CT scan taken 12 months after the start of treatment showed an improvement in the lung lesions (Figure 3). The patient received regular follow-up for 3 months after treatment completion with no relapse of *M. malmoense* infection.

Discussion

Although the incidence of NTM lung disease is rising, *M. malmoense* is a rare lung disease-causing pathogen in South

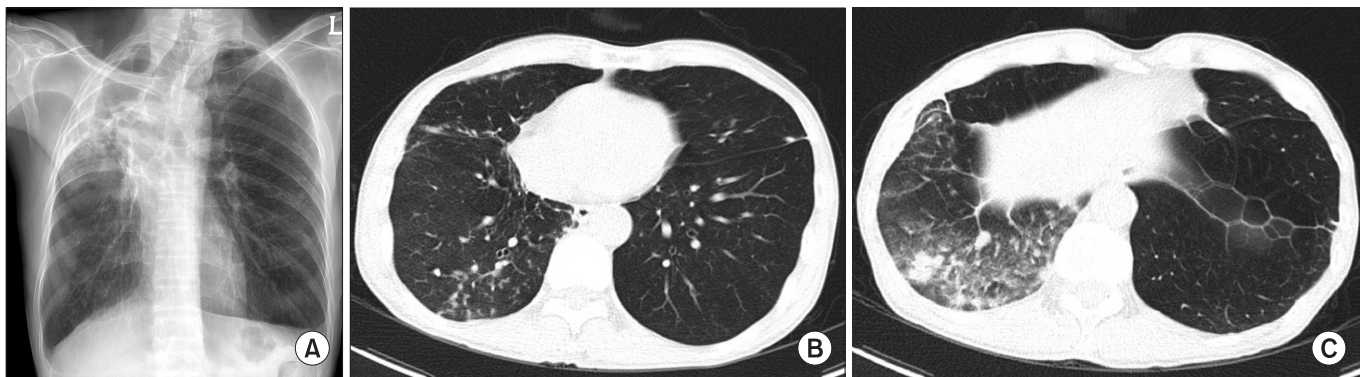


Figure 2. (A) Chest X-ray showing newly developed infiltrative lesions in the right middle lung area. (B) Low-dose chest computed tomography image showing newly developed segmental centrilobular nodules in the right lung. (C) Low-dose chest computed tomography image showing multifocal patches of consolidation and nodules in the right lung.

Table 1. AFB smear and culture results before and after treatment for *Mycobacterium malmoense* lung disease

	Before treatment				After treatment initiation				
	6 mo ago	5 mo ago	4 mo ago	3 mo ago	After 2 mo	After 4 mo	After 8 mo	After 12 mo	After 14 mo
AFB smear	Trace	1+	2+	2+	Trace	-	-	-	-
AFB culture	NTM	NTM	NTM	NTM	NG	NG	NTM	NG	NG
Identification	<i>M. malmoense</i>	<i>M. malmoense</i>	ND	<i>M. malmoense</i>	NA	NA	<i>M. peregrinum</i>	NA	NA

AFB: acid-fast bacillus; NTM: non-tuberculous mycobacteria; NG: no growth; ND: not done; NA: not applicable.

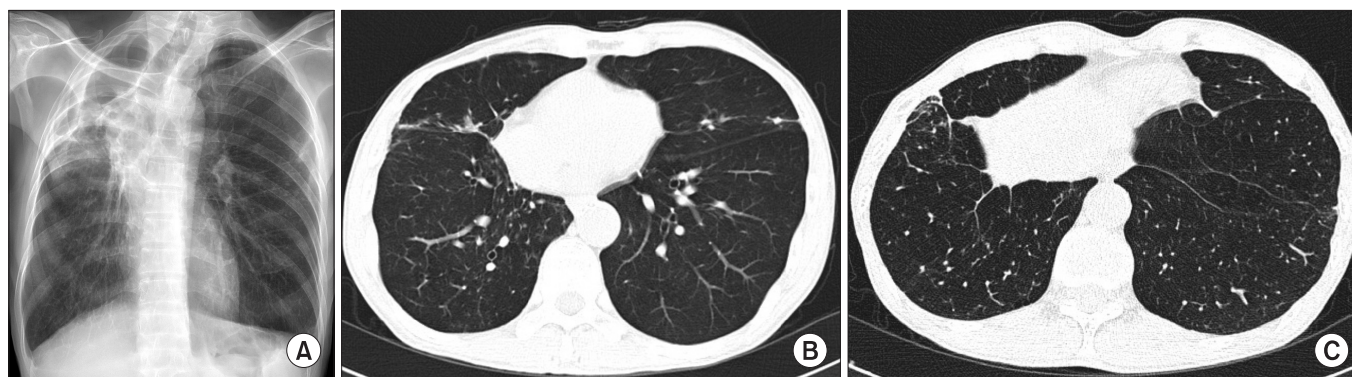


Figure 3. Chest X-ray (A) and low-dose chest computed tomography (B, C) images taken 12 months after the start of treatment showing reduced number and extent of nodules.

Korea. Here, we describe a very rare case of *M. malmoense* infection in an immunocompetent Korean male patient. To the best of our knowledge, this is the first reported case of lung disease caused by *M. malmoense* in South Korea. The patient was successfully treated with antibiotics.

There is marked geographic variability in the incidence of *M. malmoense* disease. For example, *M. malmoense* is the second most frequently isolated NTM in northern Europe⁴, but is rare in North America⁵. Accordingly, clinically relevant infections were identified in 70% of cases in northern Europe⁴, but only in 10% of cases in North America⁵. The reason for this discrepancy is unclear, although environmental factors are one possible explanation. Disease caused by *M. malmoense* has not previously been reported in South Korea. Moreover, Ryoo et al.⁶ reported previously that they failed to isolate *M. malmoense* from 17,915 NTM organisms in their reference laboratory at a single South Korean institution over a 14-year period. Although our current case is the first documented patient with *M. malmoense* lung disease in South Korea, it should be noted that we only identified the pathogen using a commercial line probe assay kit. We could not perform sequencing analysis because we were unable to obtain NTM isolates of our case, since they had been disposed of long before.

NTM lung disease develops more frequently in patients with pre-existing lung disease; this is because regional factors within the damaged areas impair the host immune response, disrupt normal defense mechanisms, influence the relationship between ventilation and perfusion, and distort the lung architecture⁷. Hoefsloot et al.³ reported that the majority of patients that contracted *M. malmoense* lung disease in the Netherlands were male and had pre-existing pulmonary disease (most often chronic obstructive pulmonary disease). Our current case also had a pre-existing pulmonary condition: a TB-destroyed lung, although *M. malmoense* disease mainly affected the normal lung parenchyma.

Approximately two thirds of patients with *M. malmoense*

lung disease show a good therapeutic response^{3,4}. ATS guidelines recommend combination therapy with isoniazid, rifampin, and ethambutol, either with or without quinolones and macrolides⁸. However, a British Trial Society (BTS) trial showed that adjuvant clarithromycin or ciprofloxacin during a 24-month regimen of rifampin and ethambutol had no additional benefit for the treatment of *M. malmoense* pulmonary disease⁹. In addition, another BTS trial reported that a 2-year regimen comprising rifampin and ethambutol was better tolerated than rifampin and ethambutol combined with isoniazid and had a similar outcome¹⁰. However, we successfully treated our current patient with a combination of isoniazid, moxifloxacin, and clarithromycin in addition to rifampin and ethambutol over a short period of time. It may be that, in this case, the addition of moxifloxacin resulted in a successful treatment outcome within a short time. A previous study revealed that a combination of moxifloxacin, clarithromycin, and ethambutol showed therapeutic efficacy against *M. avium*¹¹. Moreover, moxifloxacin is more effective against mycobacterial disease than older quinolone^{1,12}. However, although moxifloxacin has a favorable therapeutic effect against *M. avium*, it is unclear whether it also has a favorable effect against *M. malmoense* because no studies have examined this issue. Further studies are needed to fully understand the role of moxifloxacin in the treatment of lung disease caused by *M. malmoense*.

In summary, we report the first case of pulmonary infection in South Korea caused by *M. malmoense*, which was successfully treated with antibiotics.

Conflicts of Interest

No potential conflict of interest relevant to this article was reported.

References

1. Koh WJ, Kwon OJ, Jeon K, Kim TS, Lee KS, Park YK, et al. Clinical significance of nontuberculous mycobacteria isolated from respiratory specimens in Korea. *Chest* 2006;129:341-8.
2. Park YS, Lee CH, Lee SM, Yang SC, Yoo CG, Kim YW, et al. Rapid increase of non-tuberculous mycobacterial lung diseases at a tertiary referral hospital in South Korea. *Int J Tuberc Lung Dis* 2010;14:1069-71.
3. Hoefsloot W, Boeree MJ, van Ingen J, Bendien S, Magis C, de Lange W, et al. The rising incidence and clinical relevance of *Mycobacterium malmoense*: a review of the literature. *Int J Tuberc Lung Dis* 2008;12:987-93.
4. Hoefsloot W, van Ingen J, de Lange WC, Dekhuijzen PN, Boeree MJ, van Soolingen D. Clinical relevance of *Mycobacterium malmoense* isolation in The Netherlands. *Eur Respir J* 2009;34:926-31.
5. Buchholz UT, McNeil MM, Keyes LE, Good RC. *Mycobacterium malmoense* infections in the United States, January 1993 through June 1995. *Clin Infect Dis* 1998;27:551-8.
6. Ryoo SW, Shin S, Shim MS, Park YS, Lew WJ, Park SN, et al. Spread of nontuberculous mycobacteria from 1993 to 2006 in Koreans. *J Clin Lab Anal* 2008;22:415-20.
7. Aksamit TR. *Mycobacterium avium* complex pulmonary disease in patients with pre-existing lung disease. *Clin Chest Med* 2002;23:643-53.
8. Griffith DE, Aksamit T, Brown-Elliott BA, Catanzaro A, Daley C, Gordin F, et al. An official ATS/IDSA statement: diagnosis, treatment, and prevention of nontuberculous mycobacterial diseases. *Am J Respir Crit Care Med* 2007;175:367-416.
9. Jenkins PA, Campbell IA, Banks J, Gelder CM, Prescott RJ, Smith AP. Clarithromycin vs ciprofloxacin as adjuncts to rifampicin and ethambutol in treating opportunist mycobacterial lung diseases and an assessment of *Mycobacterium vaccae* immunotherapy. *Thorax* 2008;63:627-34.
10. Pulmonary disease caused by *M. malmoense* in HIV negative patients: 5-yr follow-up of patients receiving standardised treatment. *Eur Respir J* 2003;21:478-82.
11. Sano C, Tatano Y, Shimizu T, Yamabe S, Sato K, Tomioka H. Comparative *in vitro* and *in vivo* antimicrobial activities of sitafloxacin, gatifloxacin and moxifloxacin against *Mycobacterium avium*. *Int J Antimicrob Agents* 2011;37:296-301.
12. Fouad M, Gallagher JC. Moxifloxacin as an alternative or additive therapy for treatment of pulmonary tuberculosis. *Ann Pharmacother* 2011;45:1439-44.