

skeletal muscle metastasis are uncertain. A previous report recommended that skeletal muscle metastases be treated palliatively if they occur together with systemic metastasis, but an isolated metastatic neoplasm can be resected operatively with or without radiotherapy [3,4].

Although some authors have proposed performing contralateral prophylactic mastectomy, randomized controlled trials to assess the overall survival benefit of this procedure in breast cancer patients have never been carried out, and its efficacy is therefore unclear [5].

This report presented a rare case of a breast cancer metastasis into the gluteal muscle that was completely resected operatively after confirming the diagnosis with a preoperative needle biopsy. In patients with an intramuscular mass, it is necessary to proceed with a suspicion of metastatic cancer, even though metastasis to muscle tissue is rare.

References

1. Salemis NS. Skeletal muscle metastasis from breast cancer: management and literature review. *Breast Dis* 2015;35:37-40.
2. Soni A, Ren Z, Hameed O, et al. Breast cancer subtypes predispose the site of distant metastases. *Am J Clin Pathol* 2015;143:471-8.
3. Ogiya A, Takahashi K, Sato M, et al. Metastatic breast carcinoma of the abdominal wall muscle: a case report. *Breast Cancer* 2015;22:206-9.
4. Noda S, Kashiwagi S, Kawajiri H, et al. A case of metastatic breast carcinoma of the cervical muscles. *Gan To Kagaku Ryoho* 2013;40:2405-7.
5. Lostumbo L, Carbine NE, Wallace J. Prophylactic mastectomy for the prevention of breast cancer. *Cochrane Database Syst Rev* 2010;(11):CD002748.

Endoscopic Excision of Osteochondroma of the Mandibular Angle

Yeseul Moon, Jai-Kyong Pyon

Department of Plastic Surgery, Samsung Medical Center, Sungkyunkwan University School of Medicine, Seoul, Korea

Correspondence: Jai-Kyong Pyon
Department of Plastic Surgery, Samsung Medical Center, Sungkyunkwan University School of Medicine, 81 Irwon-ro, Gangnam-gu, Seoul 06351, Korea
Tel: +82-2-3410-2235, Fax: +82-2-3410-0036
E-mail: pspriest.pyon@samsung.com

No potential conflict of interest relevant to this article was reported.

Received: 12 Mar 2015 • Revised: 15 Apr 2015 • Accepted: 12 May 2015
pISSN: 2234-6163 • eISSN: 2234-6171
<http://dx.doi.org/10.5999/aps.2015.42.5.663> • Arch Plast Surg 2015;42:663-665
Copyright © 2015 The Korean Society of Plastic and Reconstructive Surgeons
This is an Open Access article distributed under the terms of the Creative Commons Attribution Non-Commercial License (<http://creativecommons.org/licenses/by-nc/3.0/>) which permits unrestricted non-commercial use, distribution, and reproduction in any medium, provided the original work is properly cited.

Osteochondroma makes up 35.8% of all benign bone tumors. It is rare in the craniofacial region [1]. The most common site in the craniofacial region is the mandibular condyle process. In these cases, the mass can result in morphological and functional disturbances. Local resection of the mass is more conservative for treating solitary osteochondroma with a stalk than radial condylectomy and reconstruction [1,2]. The surgical approach seems to

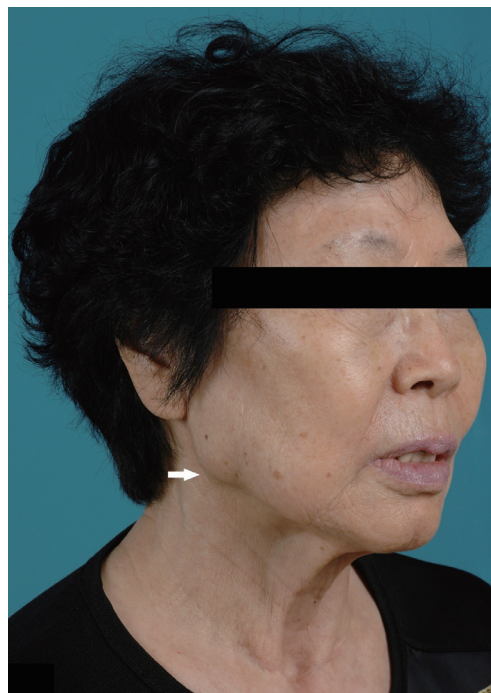

Fig. 1. Preoperative photograph. An 81-year-old female with a firm mass of the right mandibular angle (white arrow).

be limited by technical difficulties with achieving adequate exposure in cases of osteochondroma of the mandible. We report a rare case of osteochondroma of the mandibular angle that was successfully treated with endoscope-assisted surgical resection with an intraoral approach. An 81-year-old female patient came to our clinic complaining of a bony mass on her right mandibular angle. Having developed 20 years previously, the lesion had not changed since then. The patient did not have any history of trauma or surgery on her right mandible area. She had hypertension and no other general illness or diseases. On physical examination, the mass was visible on her right mandibular angle (Fig. 1). The mass was a palpable, hard, round mass 2 cm in size without pain. A computed tomography (CT) scan showed exophytic bone growth on her mandibular angle, suggesting osteochondroma (Fig. 2). We decided to perform endoscopic mass excision through intraoral incision. Under general anesthesia, an incision was made with electrocautery about 10 mm from the

lateral aspect of the molars. With a periosteal elevator, dissection was performed in the subperiosteal plane in order to avoid exposing or injuring the inferior alveolar nerve. The mandibular angle and the attached mass were exposed. The mass was a round, solitary mass with a stalk. A 30°, 10-mm-diameter endoscope was inserted through the oral incision. Under the endoscopic view, we could see the mass clearly (Fig. 3A). Osteotomy was carried out successfully along the lateral margin of the mandibular bone (Fig. 3B). The specimen removed was a round mass 2.5 × 2 cm in size. Its pathology was reported to be osteochondroma: an osteoid lesion with a focal cartilaginous area. The postoperative course was uneventful. The patient was satisfied with the result. There was no evidence of recurrence of the tumor at 6 months (Fig. 4). While osteochondroma is the most common tumor of skeletal bones, it is relatively uncommon in the jaws, occurring at the condyle or the tip of the coronoid process [3]. The lesion is slightly more common in females and tends to occur at a later age in the jaws than in the long bones [4]. There is debate whether this lesion represents a true tumor or an exostosis. Osteochondroma refers to a true neoplasm, while exostosis is considered to be reactive or developmental hyperplasia. On histologic examination, an irregularly shaped mass is considered to be a benign neoplasm, while uniform, generalized enlargement or hyperostosis is more consistent with exostosis. In this case, the patient had no history of trauma or surgery in her right mandibular angle area. Furthermore, under the endoscopic view, the mass was a solitary exophytic lesion with a stalk, which is more consistent with a benign tumor than exostosis. On CT scans, continuity between the cortex and medulla of the jaw bone with the tumor is considered diagnostic for osteochondroma. Various surgical

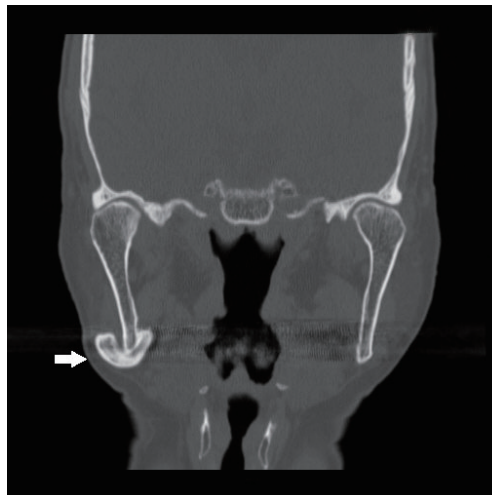


Fig. 2. Preoperative computed tomography scan showing an exophytic lesion of the right mandibular angle (white arrow).

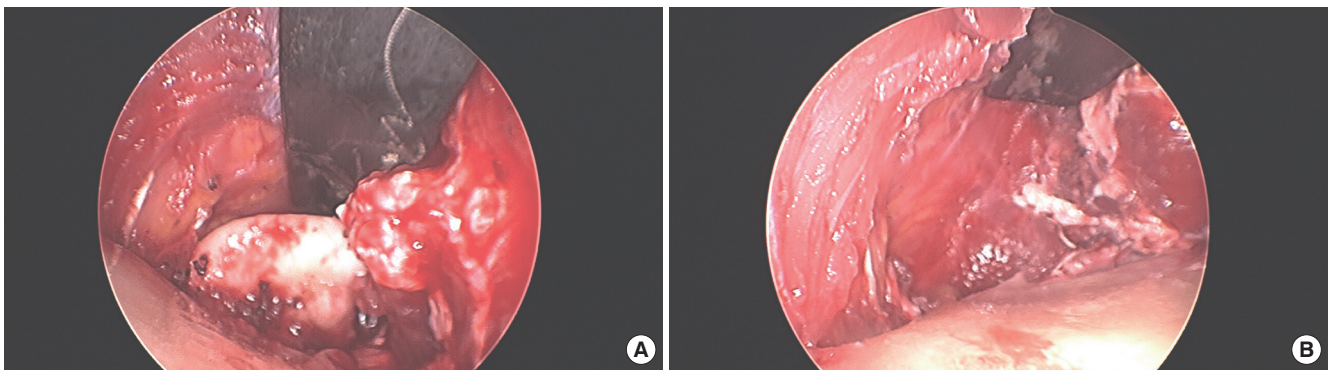


Fig. 3. Intraoperative photograph with an endoscopic view. (A) The mass is visible. (B) The mass has been completely removed.

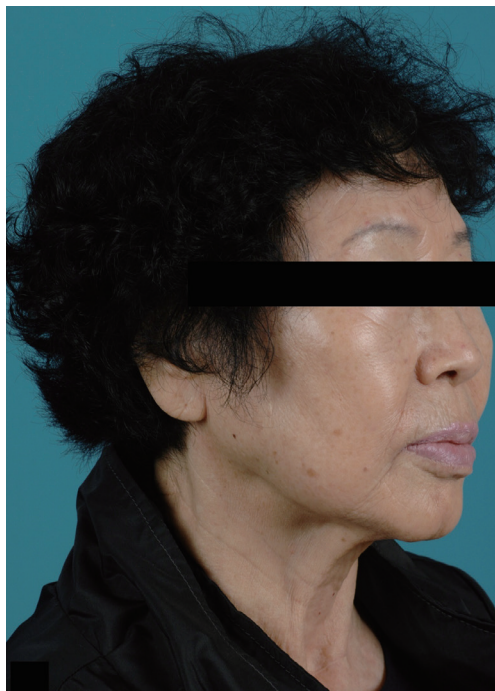

Fig. 4. Postoperative 3-month image. There is no evidence of recurrence.

approaches have been used, including a preauricular approach with or without extension to a temporal, hemicoronal incision, submandibular approach, preauricular and intraoral approach, and modified Blair incision. The preauricular approach, either on its own or in combination with cervical incisions, is the most popular approach [4]. However, the conventional surgical approach seems to be limited by technical difficulties in achieving adequate exposure. In terms of resection, the conventional approach has been condylectomy in cases of condylar osteochondroma, particularly in older case reports [3-5]. More recently, a more conservative approach to resection has been frequently reported. The recurrence rate of osteochondroma generally is 2% [1,4]. It is important to remove the tumor completely under direct vision. There is no reported endoscope-assisted complete excision of osteochondroma at the mandibular angle yet. In this rare case of osteochondroma of the mandibular angle in an 81-year-old female, the painless mass was on her mandibular angle for 20 years. In this case, with an endoscope-assisted oral incision, we were able to achieve good exposure, followed by a successful outcome. There was no evidence of recurrence at 6 months after surgery.

References

1. Lim W, Weng LK, Tin GB. Osteochondroma of the mandibular condyle: report of two surgical approaches. *Ann Maxillofac Surg* 2014;4:215-9.
2. Yu HB, Li B, Zhang L, et al. Computer-assisted surgical planning and intraoperative navigation in the treatment of condylar osteochondroma. *Int J Oral Maxillofac Surg* 2015;44:113-8.
3. Ribas Mde O, Martins WD, de Sousa MH, et al. Osteochondroma of the mandibular condyle: literature review and report of a case. *J Contemp Dent Pract* 2007;8:52-9.
4. Ord RA, Warburton G, Caccamese JF. Osteochondroma of the condyle: review of 8 cases. *Int J Oral Maxillofac Surg* 2010;39:523-8.
5. Yu HB, Sun H, Li B, et al. Endoscope-assisted conservative condylectomy in the treatment of condylar osteochondroma through an intraoral approach. *Int J Oral Maxillofac Surg* 2013;42:1582-6.

Langerhans Cell Histiocytosis with Frontal Bone Indentation by an Adjoining Primary Soft Tissue Lesion in a 17-Month-Old Asian Male Child

Seungchan Kim, Jiye Kim, Sug Won Kim

Department of Plastic and Reconstructive Surgery, Wonju College of Medicine, Yonsei University, Wonju, Korea

Correspondence: Sug Won Kim
Department of Plastic and Reconstructive Surgery, Wonju College of Medicine, Yonsei University, 20 Ilsan-ro, Wonju 26426, Korea
Tel: +82-33-741-0611, Fax: +82-33-742-3245
E-mail: sugwonkim@gmail.com

No potential conflict of interest relevant to this article was reported.

Received: 1 Apr 2015 • Revised: 20 May 2015 • Accepted: 26 May 2015
pISSN: 2234-6163 • eISSN: 2234-6171
<http://dx.doi.org/10.5999/aps.2015.42.5.665> • Arch Plast Surg 2015;42:665-668

Copyright © 2015 The Korean Society of Plastic and Reconstructive Surgeons
This is an Open Access article distributed under the terms of the Creative Commons Attribution Non-Commercial License (<http://creativecommons.org/licenses/by-nc/3.0/>) which permits unrestricted non-commercial use, distribution, and reproduction in any medium, provided the original work is properly cited.

Langerhans cell histiocytosis (LCH) is a rare disease that represents a clonal proliferation of pathologic Langerhans cells [1]. Although its clinical manifestations range from isolated bone lesions to multisystem disease, the pathological finding is