

when posterior pinna lesions are excised as the skin of the pinna is extremely thin. Reconstruction following cartilage excision can be difficult with contour deformities posing a potential problem. In this case, there was not enough redundant skin in the posterior auricular sulcus for a transposition flap.

Before now, the trap door flap has only been described for anterior pinna defects. It had to be modified slightly from the traditional trap door flap in order to reconstruct posterior pinna defects. The posterior auricular area blood supply has been well documented [4] and as a result flap loss is exceedingly rare [3].

McInerney et al. [3] reported on 45 patients with anterior pinna and conchal defects who had trap door reconstruction. They found the flap to be very reliable, producing a good cosmetic outcome. The flap provides a good colour match as it replicates the contour of the ear very well. We feel that the trap door flap should now be considered as a reconstructive option when excising skin malignancies on the posterior aspect of the pinna especially when there is a paucity of skin for a transposition flap. It is an extremely safe and effective flap with an excellent and predictable outcome.

References

1. Pless J. Carcinoma of the external ear. *Scand J Plast Reconstr Surg* 1976;10:147-51.
2. Lynch J, Mahajan AL, Regan P. The trap door flap for reconstructing defects of the concha. *Br J Plast Surg* 2003;56:709-11.
3. McInerney NM, Piggott RP, Regan PJ. The trap door flap: a reliable, reproducible method of anterior pinna reconstruction. *J Plast Reconstr Aesthet Surg* 2013;66:1360-4.
4. Hessam S, Georgas D, Bruns N, et al. A retroauricular flap for earlobe construction. *J Am Acad Dermatol* 2014;71:e129-30.

The Oblique Rectus Abdominis Musculocutaneous Flap for Reconstruction after Resection of a Spermatic Cord Liposarcoma

Jeremy Mingfa Sun¹, Jonah Ee-Hsiang Kua¹,
Lui Shiong Lee², Kah Woon Leo¹

Departments of ¹Plastic and ²Urology, Singapore General Hospital, Singapore, Singapore

Correspondence: Jeremy Mingfa Sun
Department of Plastic Reconstructive and Aesthetic Surgery, Singapore General Hospital, Outram Road, Singapore 169608, Singapore
Tel: +65-98768991, Fax: +65-98768991, E-mail: zatyricall@gmail.com

No potential conflict of interest relevant to this article was reported.

Received: 20 Apr 2015 • Revised: 2 Jul 2015 • Accepted: 14 Jul 2015
pISSN: 2234-6163 • eISSN: 2234-6171
<http://dx.doi.org/10.5999/aps.2015.42.5.647> • Arch Plast Surg 2015;42:647-650

Copyright © 2015 The Korean Society of Plastic and Reconstructive Surgeons
This is an Open Access article distributed under the terms of the Creative Commons Attribution Non-Commercial License (<http://creativecommons.org/licenses/by-nc/3.0/>) which permits unrestricted non-commercial use, distribution, and reproduction in any medium, provided the original work is properly cited.

A 62-year-old Chinese man presented with a painless swelling in the right inguinal region that had been increasing in size for over a year. After ultrasound imaging, a provisional diagnosis of a spermatic cord lipoma was made, and the inguinal mass was excised. The histological examination revealed a well

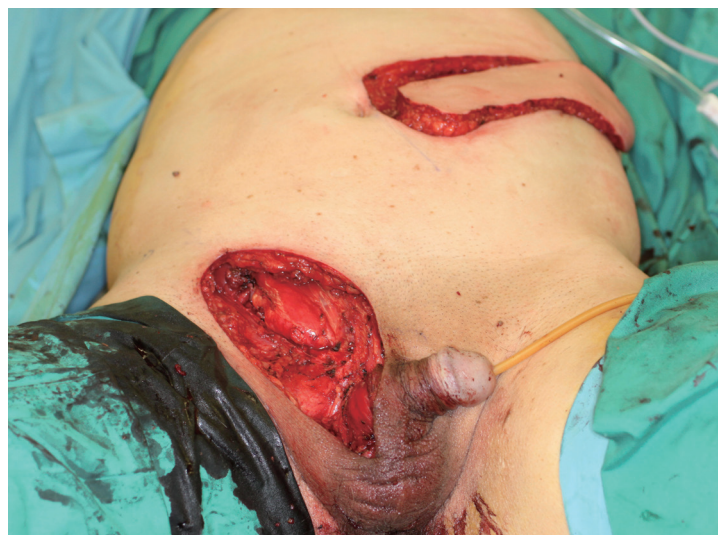

Fig. 1.

Surgical resection of the right inguinal region and the right hemiscrotum, together with right orchidectomy, resulted in a 15 × 7-cm skin defect and a 5 × 3-cm anterior abdominal wall defect involving the external oblique aponeurosis, internal oblique muscle, and conjoint tendon. The oblique rectus abdominis myocutaneous flap was raised based on the paraumbilical perforators of the rectus abdominis muscle.

differentiated liposarcoma with involved margins.

The patient was referred to a urologist at our institution for further management. On examination, a right inguinal scar was noted over a 7-cm swelling in the right inguinal region. The right testis was firm, enlarged, and fixed to the surrounding right hemiscrotal skin.

Surgical resection of the right inguinal region and the right hemiscrotum, in combination with right

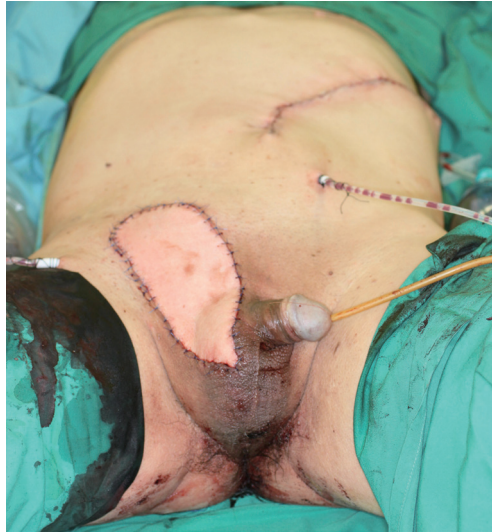

Fig. 2.

The skin and subcutaneous defect were closed with the oblique rectus abdominis myocutaneous) skin paddle and the excess length at the distal end of the skin paddle was de-epithelised and folded onto itself to obliterate the potential hemiscrotal dead space and create fullness in the scrotum after the orchidectomy.

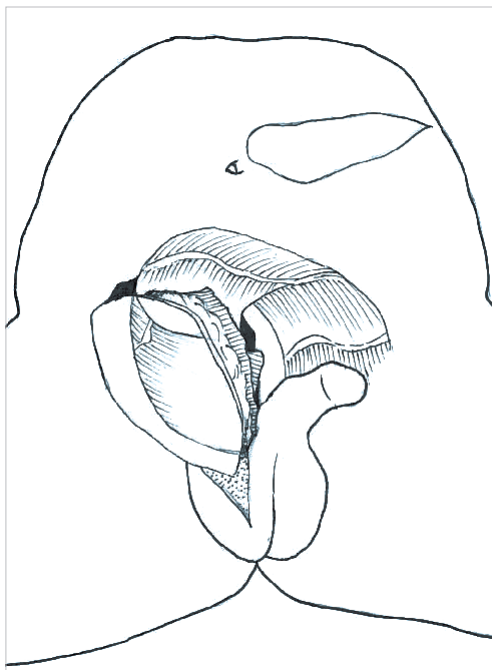


Fig. 3.

This schematic figure shows how the oblique rectus abdominis myocutaneous flap was tunnelled and folded over, so that the anterior rectus sheath in the flap was used to reconstruct the fascial component of the inguinoscrotal defect.

orchidectomy, resulted in a 20 × 8-cm skin defect and a 5 × 3-cm anterior abdominal wall defect involving the external oblique aponeurosis, internal oblique muscle, and conjoint tendon, and extending along the inguinal canal (Fig. 1). A contralateral oblique rectus abdominis myocutaneous (ORAM) flap was raised based on the left deep inferior epigastric vessels. The inguinal fascial defect was reconstructed with the size-matched anterior rectus sheath of the ORAM flap by sequential mattress stitching that opposed the edges of the inguinal fascial defect to the rectus sheath of the flap (Fig. 2). The skin and subcutaneous defect were closed with a skin paddle. Excess length at the distal end of the skin paddle was de-epithelised and folded onto itself to obliterate the potential hemiscrotal dead space and create fullness in the scrotum after the orchidectomy (Fig. 3). An inlay prolene mesh was used to reconstitute the defect in the donor site rectus sheath followed by meticulous closure of soft tissue and the skin in layers. The patient had an uncomplicated recovery. A follow-up examination three months later showed that his wounds had recovered well, with good aesthetic results (Fig. 4). Clinical and radiological investigations did not show any recurrence or complications, such as inguinal hernia (Fig. 5).

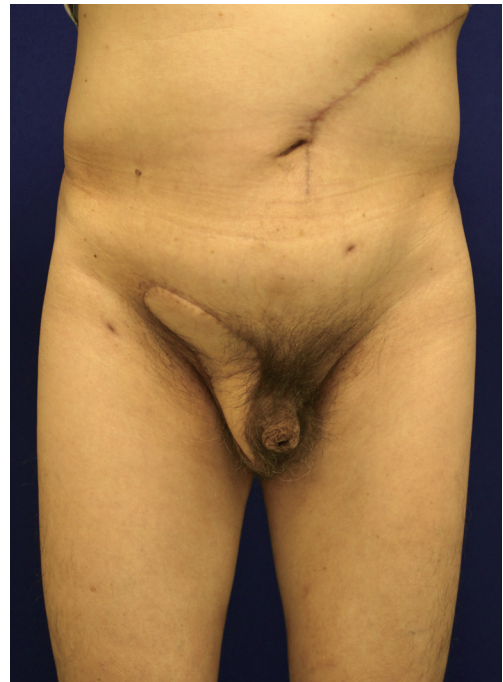

Fig. 4.

This figure contains a frontal view three months after the operation showing that the wounds had healed well and that a good aesthetic result was achieved.

Liposarcoma of the spermatic cord is a rare disorder, and only approximately 100 cases have been reported worldwide [1]. Surgical management usually involves radical excision, and a large composite skin and soft tissue defect is created at or near Hesselbach's triangle, a naturally weakened area of the abdominal wall. A sizable dead space is also created after resection. Defects in the inguinal ligament, lacunar ligament, or conjoint tendon weaken the inferior or posterior border of the inguinal canal, further predisposing the patient to direct inguinal hernias if unrepaired. With these deficiencies in mind, our flap choice was based on the principle of replacing like with like. We required a moderately sized flap with a large reliable skin paddle to fill the dead space and resurface the 20 × 8-cm skin defect. Primary closure would have resulted in seroma formation in the dead space as well as tightness of the area of the groin crease on hip extension, which can lead to complications involving wound breakdown due to the high tension of the closure. Sufficient fascia should be present on the flap to repair the fascial defect at the inguinal region. Little information on postoperative complications has been published, but we believe that they would include poor wound healing due to excessive wound tension, development of a seroma, infections secondary to a large dead space, flexion contractures of the hip if skin grafts are used, and inguinal hernias due to the loss of the fascial integrity of the inguinal canal.

Careful preoperative assessment of the composite defect and an understanding of the characteristics of each flap allowed us to narrow our flap options to a pedicled anterior-lateral thigh (ALT) flap or a pedicled ORAM flap. The ALT flap is often used to reconstruct defects in the head and neck, perineum, and lower limb, and involves a reliable blood supply that can be raised with a large skin paddle with minimal donor site morbidity. The ORAM flap is a myocutaneous flap based on the periumbilical perforators exiting the rectus abdominis muscle. Cadaveric studies have shown that when the periumbilical perforators were injected with dye, preferential filling was observed in a lateral and superio-lateral-oblique fashion [2]. Skin paddles of up to 43 × 8 cm in size are reported to have been safely raised [3].

A unique characteristic of the ORAM flap is the differential flap thickness of the skin paddle. It is thick near its origin at the periumbilical perforators, as it includes the full thickness layer of the rectus muscle,

and becomes progressively thinner at the distal end. This was ideal for our reconstruction, as we required bulk in the proximal portion of the flap to obliterate the groin and inguinal dead space, while the thin and pliable distal end was used to reconstruct the thinner scrotal and perineal skin. The final results indicated that the soft tissue thickness was a good match to the surrounding skin. The length of the ORAM flap also allowed the tension-free resurfacing of the large longitudinal skin defect from the inguinal ring to the ipsilateral hemiscrotum. The excess skin paddle was de-epithelised and rolled up to fill the remaining area of the scrotal sac. We chose the ORAM flap over the ALT flap for three main reasons. First, a subcutaneous tunnel was created with an oblique projection into the right inguinal scrotal area. It is important to consider the posterior boundary of the subcutaneous tunnel. If this boundary is fixed, it forms a compression point on the vascular pedicle, increasing the risk of flap necrosis. The pliable transversalis fascia and the soft bowel loops form the posterior wall of the subcutaneous tunnel of the ORAM flap, while the relatively thick and inexpandable thigh muscles, femur, and iliac bone form the posterior wall of the tunnel of the pedicled ALT flap. The ALT flap undergoes greater compression in the subcutaneous tunnel than the ORAM flap.

Second, by choosing the pedicled ORAM flap over the pedicled ALT flap, we were able to raise the ORAM flap simultaneously on the contralateral side

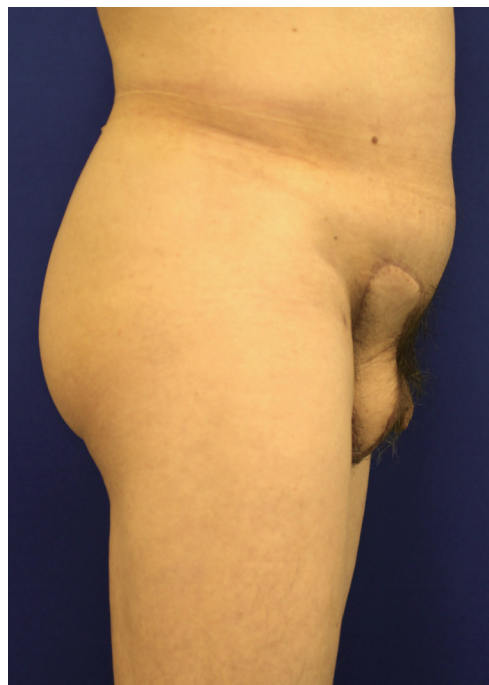

Fig. 5. This figure contains a lateral view three months after the operation showing that the wounds had healed well and that a good aesthetic result was achieved.

while the sarcoma was being resected. This resulted in a shorter operative time, less blood loss, and a faster postoperative recovery.

Finally, the arc of rotation of the ORAM flap was preferable to that of the ALT flap, which would have required a 'U-turn' to project the flap into the scrotum.

It is critical to repair the fascial defect at and around the deep and superficial ring of the inguinal canal, as this fascia layer reduces the risk of future inguinal hernias. After measuring the fascial defect over the deep inguinal ring (5 × 3 cm), we harvested equal dimensions of the left anterior rectus sheath as part of the myocutaneous flap. This anterior rectus sheath was then used after tunneling the flap to close the fascial defect over the deep inguinal ring, replacing like with like. This avoided the use of a synthetic mesh, which would have carried a risk of implant infection as well as being more expensive. Instead of using a mesh to close inguinal fascial defects of this type, it would be more prudent to make use of the fascial component of the flap to reconstruct such defects.

In conclusion, the contralateral pedicled ORAM flap is an attractive reconstructive option after the radical excision of a spermatic cord liposarcoma.

References

1. Taylor GI, Corlett R, Boyd JB. The extended deep inferior epigastric flap: a clinical technique. *Plast Reconstr Surg* 1983;72:751-65.
2. Villa M, Saint-Cyr M, Wong C, et al. Extended vertical rectus abdominis myocutaneous flap for pelvic reconstruction: three-dimensional and four-dimensional computed tomography angiographic perfusion study and clinical outcome analysis. *Plast Reconstr Surg* 2011;127:200-9.
3. Koul AR, Nahar S, Prabhu J, et al. Free boomerang-shaped extended rectus abdominis myocutaneous flap: the longest possible skin/myocutaneous free flap for soft tissue reconstruction of extremities. *Indian J Plast Surg* 2011;44:396-404.

Technical Considerations to Avoid Microvascular Complications during Groin Lymph Node Free Flap Transfer

Pedro Ciudad¹, Georgios Orfaniotis¹, Juan Socas², Rory Dower¹, Kidakorn Kiranantawat¹, Fabio Nicoli¹, Stamatis Sapountzis¹, Michele Maruccia¹, Hung-Chi Chen¹

¹Department of Plastic Surgery, China Medical University Hospital, Taichung, Taiwan; ²Department of Plastic and Reconstructive Surgery, Indiana University School of Medicine, Indianapolis, IN, USA

Correspondence: Hung-Chi Chen
Department of Plastic Surgery, China Medical University Hospital,
2 Yuh-Der Road, Taichung 40447, Taiwan
Tel: +88-6975682158, Fax: +88-6975682158
E-mail: D19722@mail.cmuh.org.tw

No potential conflict of interest relevant to this article was reported.

Received: 28 May 2015 • Revised: 14 Jun 2015 • Accepted: 15 Jun 2015
pISSN: 2234-6163 • eISSN: 2234-6171
<http://dx.doi.org/10.5999/aps.2015.42.5.650> • Arch Plast Surg 2015;42:650-652

Copyright © 2015 The Korean Society of Plastic and Reconstructive Surgeons
This is an Open Access article distributed under the terms of the Creative Commons Attribution Non-Commercial License (<http://creativecommons.org/licenses/by-nc/3.0/>) which permits unrestricted non-commercial use, distribution, and reproduction in any medium, provided the original work is properly cited.

Groin lymph node free flap (G-LNF) transfer is a well-known technique for the treatment of lymphedema. Despite promising early and long-term results, concerns regarding postoperative donor site lymphedema and adequacy of the G-LNF vessels have limited the popularity of G-LNF transfer amongst microsurgeons.

G-LNF can be based either on the superficial circumflex iliac artery (SCIA), the superficial inferior epigastric artery (SIEA), or a small, unnamed medial branch of the femoral artery (MBFA) [1].

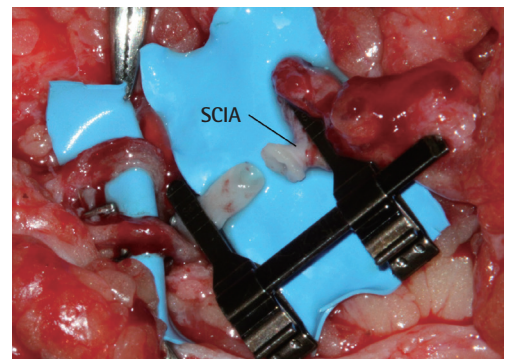


Fig. 1.

A patch of the femoral artery was harvested to increase the caliber of the superficial circumflex iliac artery (SCIA).