

Short-Term Strength Deficit Following Zone 1 Replantations

Si Young Roh¹, Woo Cheol Shim¹, Kyung Jin Lee¹, Dong Chul Lee¹, Jin Soo Kim¹, Jae-Won Yang²

¹Department of Plastic and Reconstructive Surgery, Gwangmyeong Sungae Hospital, Gwangmyeong; ²Gangnam Jaejun Plastic Clinic for Hand and Plastic Surgery, Pyeongtaek, Korea

Original Article

Background Hand strength deficit following digital replantation is usually attributed to the mechanical deficiency of the replanted digit. Zone 1 replantation, however, should not be associated with any mechanical deficit, as the joint and tendon are intact. We evaluate short-term motor functions in patients who have undergone single-digit zone 1 replantation.

Methods A single-institution retrospective review was performed for all patients who underwent zone 1 replantation. Hand and pinch strengths were evaluated using standard dynamometers. Each set of measurements was pooled according to follow-up periods (within 1 month, 1 to 2 months, 2 to 3 months, and after 3 months). The uninjured hand was used as reference for measurements.

Results The review identified 53 patients who had undergone zone 1 replantation and presented for follow-up visits. Compared to the uninjured hand, dynamometer measurements revealed significantly less strength for the hand with replanted digit at one month. The relative mean grip, pulp, and key pinch strength were 31%, 46%, and 48% of the uninjured hand. These three strength measurements gradually increased, with relative strength measurements of 59%, 70%, and 78% for 4-month follow up.

Conclusions Despite the lack of joint or tendon injury, strength of the injured hand was significantly lower than that of the uninjured hand during the 4 months following replantation. Improved rehabilitation strategies are needed to diminish the short-term negative impact that an isolated zone 1 replantation has on the overall hand strength.

Keywords: Hand strength / Pinch strength / Replantation / Range of motion, articular

Correspondence: Si Young Roh
Department of Plastic and Reconstructive Surgery,
Gwangmyeong Sungae General Hospital, 36 Digital-ro, Gwangmyeong 14241, Korea
Tel: +82-2-2680-7238
Fax: +82-2-2615-7218
E-mail: psczero@gmail.com

The authors thank Dr. Aram Harijan for his insight and assistance in the preparation of this manuscript.

No potential conflict of interest relevant to this article was reported.

Received: 17 Mar 2015 • Revised: 18 May 2015 • Accepted: 1 Jun 2015
pISSN: 2234-6163 • eISSN: 2234-6171 • <http://dx.doi.org/10.5999/aps.2015.42.5.614> • Arch Plast Surg 2015;42:614-618

INTRODUCTION

Strength and range of joint motion are the two most commonly evaluated functional outcomes following digital injury [1]. Total active motion (TAM) is the sum of active arc of flexion at the interphalangeal and metacarpophalangeal joints, and has been used as a good general metric for joint and tendon function [2].

Grip strength is another simple and standardized method of evaluating motor function. Measurement of grip strength is inexpensive and reliable, and has been widely used to evaluate nutritional status and hand function [3,4].

Post-replantation functional outcomes are most commonly evaluated using TAM and grip strength. In a study comparing various replantation levels, Walaszek and Zyluk [5] reported

that these functional outcomes were better for zone 1 replantations. Despite the lack of tendon injuries, zone 1 replantations result in hand functions that are significantly worse than those of the contralateral, non-injured hand [6]. Additionally, short-term functional evaluations are not widely available for zone 1 injuries, with the implied assumption that such surviving digits are without any strength deficit. Hence, this study investigates short-term functional outcomes following Tamai [7] zone 1 replantation.

METHODS

A single-institution retrospective review was performed for all patients who had undergone zone 1 replantation between January 2011 and June 2014. The study excluded those patients who had multiple digit amputations, thumb amputations, bilateral hand injuries, and/or for reconstruction work in addition to the replantation. Demographic information, postoperative grip strength, and range of motion were collected.

The hand with replanted finger was kept in volar splint for 2 weeks, after which free finger movements were allowed. Physical therapy was started at 3 weeks. The physical therapist at our institution routinely measures hand strengths with a Jamar grip dynamometer (Patterson Medical, Bolingbrook, IL, USA) and a pinch dynamometers (Saehan Corp., Masan, Korea), using an established protocol [8]. Patients are seated with the shoulder adducted and neutrally rotated, elbow flexed at 90° with the forearm in neutral position, and wrists between 0° and 30° of flexion and between 0° and 15° of ulnar deviation. Hand strength is evaluated in the order of grip, key pinch, and pulp pinch. The same dynamometer and pinch gauge is used for all participants. Each

examination is performed for three consecutive times at 1-minute intervals to reduce fatigue-induced measurement bias. Range-of-motion is measured by the physical therapist at the same time [9].

Each postoperative measurement was used as an independent data set, and the measurements were analyzed in 4 groups according to the postoperative period (within 1 month, 1 to 2 months, 2 to 3 months, and after 3 months). Hand dominance was found to have no significant correlation with variations in grip strength measurements [4,10], and hand strengths were compared to those measurements from contralateral hand. Strength measurements were expressed in lbs (% of contralateral hand). All statistical analyses were performed using SPSS ver. 20.0 (IBM Corp., Armonk, NY, USA). We provided P-values using the independent two-samples t-test or one-way analysis of variance (ANOVA) test to signify outcome differences across the groups. Statistical significance was set at $P < 0.05$.

RESULTS

Out of the 322 patients with zone 1 amputation identified in the review, 41 patients were excluded for thumb replantations and 228 patients were excluded for multiple finger amputations or the need for additional reconstructive surgery. The remaining 53 patients consisted of 36 males and 17 females. The mean age was 45 years old (range, 20–70 years old). The mean duration of follow-up period was 9 weeks (range, 3–48 weeks). There were a total of 78 postoperative measurements (36 single visits, 9 double visits, and 8 triple visits) (Table 1). Grip strength was significantly different between men (37.22 ± 18.50 lbs) and women ($M = 15.88 \pm 1.62$ lbs) ($P < 0.01$). Patient age was not significantly related to grip strength ($P = 0.40$).

The mean hand strength of the injured hand was all significantly lower, compared to the contralateral hand. Also, the mean range of motion for distal interphalangeal (DIP) joint was less for the

Table 1. Baseline characteristics for patients who have undergone zone 1 replantation

Characteristic	n (%)
Sex	
Male	36 (68)
Female	17 (32)
Age (yr)	
20–29	6 (11)
30–39	7 (13)
40–49	22 (42)
50–70	18 (34)
Injured hand	
Right hand	23 (43)
Left hand	30 (57)
Injured finger	
Index finger	17 (32)
Middle finger	14 (26)
Ring finger	11 (21)
Little finger	11 (21)

Table 2. Mean hand strengths and range of motion for all measurements

Variable	Injured hand	Contralateral hand	%
Hand function (lbs)			
Grip strength	32.4 ± 19.1	68.4 ± 24.4	47
Pulp pinch strength	4.9 ± 4.1	9.9 ± 3.1	49
Key pinch strength	11.1 ± 5.6	17.5 ± 4.6	63
Range of motion (°)			
Metatarsophalangeal joint	73 ± 11	90	81
Proximal interphalangeal joint	74 ± 17	110	67
Distal interphalangeal joint	25 ± 17	90	27

The proportional strength measurement of the hand with replanted digit is represented as a percentage of the uninjured hand strength.

Table 3. Average hand strengths and range of motion by monthly intervals

Variable	1 mo	2 mo	3 mo	4 mo
Grip strength (normal hand)	66.1 ± 19.1	66.9 ± 24.0	66.6 ± 24.3	74.6 ± 28.9
Grip strength (injured hand)	20.5 ± 9.8	31.9 ± 20.3	28.6 ± 13.8	43.7 ± 20.1
Pulp pinch (normal hand)	8.4 ± 2.1	10.3 ± 3.6	9.4 ± 2.8	10.2 ± 2.3
Pulp pinch (injured hand)	3.8 ± 2.8	4.7 ± 4.4	3.8 ± 2.7	7.1 ± 4.5
Key pinch (normal hand)	17.6 ± 6.2	17.4 ± 4.5	16.5 ± 4.7	18.6 ± 3.7
Key pinch (injured hand)	8.4 ± 5.2	10.5 ± 5.8	10.4 ± 4.3	14.5 ± 5.3
Range of motion (MPJ)	70 ± 12	71 ± 12	75 ± 9	78 ± 6
Range of motion (PIPJ)	66 ± 17	72 ± 18	77 ± 18	82 ± 12
Range of motion (DIPJ)	27 ± 22	21 ± 16	26 ± 18	30 ± 17
Total active motion	162 ± 51	161 ± 41	173 ± 39	182 ± 35

As opposed to pinch strength measurements, grip strength is a global measure of the hand strength. Considering the fact that all of the patients had single-digit, zone 1 replantation, this data suggests that immobilization of the whole hand may be a potential cause for significant decrease in hand function in the early recovery period. Grip strength, pulp pinch, key pinch strength (lbs); range of motion (°). MPJ, metatarsophalangeal joint; PIPJ, proximal interphalangeal joint; DIPJ, distal interphalangeal joint.

Fig. 1. Hand strength for four months

Horizontal axis indicates postoperative period. Vertical axis indicates strength in lbs.

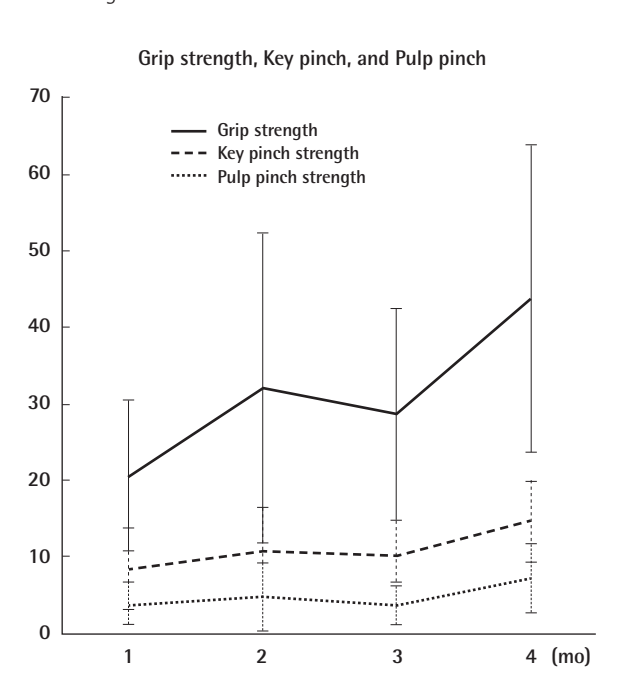
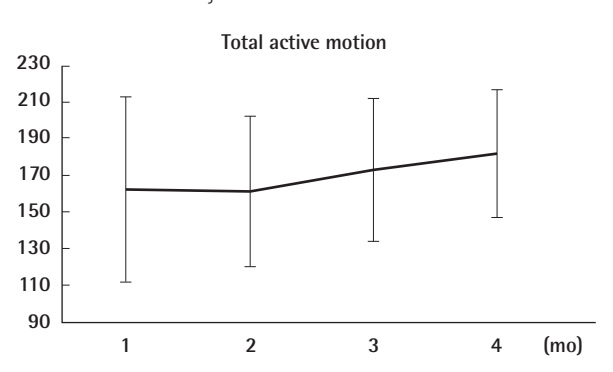


Fig. 2. Total active motion for four months

Horizontal axis indicates time after replantation, and vertical axis indicates total sum of joint motions.



than 3 months) was statistically significant (one way ANOVA test, $F = 3.52, P < 0.05$).

The average TAM was 168°, which was 65% of the contralateral finger. Overall, TAM of the replanted digit improved over the 4-month period, from 162° before 1 month to 181° after 4 months. Whereas strength measurements improved without latency, initial recovery in range of motion was fairly slow for the second month at 161° (Fig. 2).

injured finger, compared to the counterpart joint in the uninjured hand (Table 2).

Compared to the uninjured hand, dynamometer measurements revealed significantly less strength for the hand with replanted digit at four weeks. The relative mean grip, pulp, and key pinch strength were 31%, 46%, and 48% of the contralateral, uninjured hand. These three strength measurements gradually increased, with relative strength measurements of 59%, 70%, and 78% for 4-month follow up (Table 3, Fig. 1). The difference in the strength measurements between early (within 1 month) and late (more

DISCUSSION

Compared to more proximal amputations, zone 1 replantations are associated with shorter treatment duration and better functional outcomes because both the flexor tendon and DIP joint are intact. In a study comparing functional outcomes between replantation zones, Ross et al. [2] reported the total active range of motion to be 202° for zone 1 vs. 126° for zone 2. In comparison, zone 4 replantations were associated with little to no motion at the DIP joint. Additionally, significant limitations in prox-

imal interphalangeal joint motion have been observed when both profundus and superficialis tendons needed repair [11]. In a long-term follow up of 32 zone 1 replantations, Hattori et al. [12] found that the mean arc of DIP joint motion was 60°.

The grip strength of an injured hand is influenced by the number of replanted/revascularized digits and by the number of missing digits. Reported outcomes were better for single-digit replantations, especially in those patients with successfully replanted thumbs [5]. More specifically, the pinch and grip power of the replanted thumb has been reported to be 70% and 80% of the uninjured thumb, respectively [13]. Holmberg et al. [14] reported a mean total grip strength of 72% and a mean pinch grip strength of 69%, compared to the uninjured hand. However, this study included a large number of incomplete and complete amputations. In our study of exclusively single-digit amputations, the mean grip strength of the injured hands was less than one-third of the uninjured hand at one month. This functional deterioration was observed in the early portion of recovery period (1 month). Our review of zone 1 replantation had precluded any patient with tendon injuries, yet the relative grip strength of 31% at one month suggested that patients were experiencing significant reduction in the ability to generate flexor force. The near 70% deficit in strength was unexpected and warrants a close investigation.

In previous studies, individual grip strength contributions have been evaluated for each finger. The middle finger is known to generate the most amount of power—about a third of grip strength. The ring and index fingers are symmetrical in force generation, with each contributing about 25% of the total grip strength. The little finger contributes approximately 15% [15,16].

Theoretically, strength deficits should be commensurate with the loss of individual strength of the finger that is unable to transfer the flexor force of the muscle. The worst-case scenario would be proximal amputation of the middle finger, which should result in a strength loss of around 30%. However, our study has shown that distal zone 1 amputations without mechanical disruption of flexor mechanism can result in a relative grip strength deficit of 69% at 1-month post operation.

In our review of the literature, we have found that most studies have focused on grip strength as surrogate markers for nutritional status and for long-term functional outcomes following hand operations [17]. While short-term grip strength following hand operations has not been studied extensively, this is a clinically relevant issue for those patients who return to a physically demanding work environment and accept this temporary but significant decline in hand strength as a natural consequence of a finger amputation.

This study has few limitations. Because of the retrospective

study design, there may have been a selection bias towards patients with worse outcomes and for patients who wished to follow up more diligently or more frequently. However, we believe that the significant deterioration of grip strength is a real phenomenon and suspect that flexor weaknesses have resulted from the 2 weeks of splinting, by which the whole hand is immobilized to protect a single replanted digit. Pain may be a potential confounding factor.

In summary, grip strength was unexpectedly low in our group of patients who had undergone zone 1 replantation. With a recovery latency of about two months, patients experience significant limitations in generating maximal grip force for the first few months following a replantation. Further studies are necessary to evaluate whether this strength deficit is either due to a confounding variable such as pain or a clinical consequence of splinting the whole hand.

REFERENCES

1. Hume MC, Gellman H, McKellop H, et al. Functional range of motion of the joints of the hand. *J Hand Surg Am* 1990; 15:240-3.
2. Ross DC, Manktelow RT, Wells MT, et al. Tendon function after replantation: prognostic factors and strategies to enhance total active motion. *Ann Plast Surg* 2003;51:141-6.
3. Gunther CM, Burger A, Rickert M, et al. Grip strength in healthy caucasian adults: reference values. *J Hand Surg Am* 2008;33:558-65.
4. Shim JH, Roh SY, Kim JS, et al. Normative measurements of grip and pinch strengths of 21st century Korean population. *Arch Plast Surg* 2013;40:52-6.
5. Walaszek I, Zyluk A. Long term follow-up after finger replantation. *J Hand Surg Eur Vol* 2008;33:59-64.
6. Hasuo T, Nishi G, Tsuchiya D, et al. Fingertip replantations: importance of venous anastomosis and the clinical results. *Hand Surg* 2009;14:1-6.
7. Tamai S. Twenty years' experience of limb replantation: review of 293 upper extremity replants. *J Hand Surg Am* 1982; 7:549-56.
8. Mathiowetz V, Kashman N, Volland G, et al. Grip and pinch strength: normative data for adults. *Arch Phys Med Rehabil* 1985;66:69-74.
9. Haidar SG, Kumar D, Bassi RS, et al. Average versus maximum grip strength: which is more consistent? *J Hand Surg Br* 2004;29:82-4.
10. Crosby CA, Wehbe MA, Mawr B. Hand strength: normative values. *J Hand Surg Am* 1994;19:665-70.
11. Waikakul S, Sakkarnkosol S, Vanadurongwan V, et al. Results

- of 1018 digital replantations in 552 patients. *Injury* 2000;31:33-40.
12. Hattori Y, Doi K, Ikeda K, et al. Significance of venous anastomosis in fingertip replantation. *Plast Reconstr Surg* 2003;111:1151-8.
 13. Chen HC, Tang YB. Replantation of the thumb, especially avulsion. *Hand Clin* 2001;17:433-45.
 14. Holmberg J, Lindgren B, Jutemark R. Replantation-revascularization and primary amputation in major hand injuries: resources spent on treatment and the indirect costs of sick leave in Sweden. *J Hand Surg Br* 1996;21:576-80.
 15. Ohtsuki T. Inhibition of individual fingers during grip strength exertion. *Ergonomics* 1981;24:21-36.
 16. MacDermid JC, Lee A, Richards RS, et al. Individual finger strength: are the ulnar digits "powerful"? *J Hand Ther* 2004;17:364-7.
 17. Norman K, Stobaus N, Gonzalez MC, et al. Hand grip strength: outcome predictor and marker of nutritional status. *Clin Nutr* 2011;30:135-42.