

## Radiographic evaluation of the maxillary sinus prior to dental implant therapy: A comparison between two-dimensional and three-dimensional radiographic imaging

Aditya Tadinada<sup>1,\*</sup>, Karen Fung<sup>2</sup>, Sejal Thacker<sup>2</sup>, Mina Mahdian<sup>1</sup>, Aniket Jadhav<sup>1</sup>, Gian Pietro Schincaglia<sup>2</sup>

<sup>1</sup>Department of Oral and Maxillofacial Radiology, University of Connecticut School of Dental Medicine, Farmington, CT, USA

<sup>2</sup>Department of Periodontics, University of Connecticut School of Dental Medicine, Farmington, CT, USA

### ABSTRACT

**Purpose:** This study was performed to evaluate the diagnostic efficacy of panoramic radiography and cone-beam computed tomography (CBCT) in detecting sinus pathology.

**Materials and Methods:** This study was based on a retrospective evaluation of patients who had undergone both a panoramic radiograph and a CBCT exam. A total of 100 maxillary sinuses were evaluated. Four examiners with various levels of expertise evaluated the images using a five-point scoring system. Receiver operating characteristic (ROC) curve analysis was performed to evaluate the diagnostic efficacy of the two modalities. The image analysis was repeated twice, with at least two weeks between the evaluation sessions. Interobserver reliability was assessed using Cronbach's alpha, and intraobserver reliability was assessed using Cohen's kappa.

**Results:** Maxillary sinus pathology was detected in 72% of the patients. High interobserver and intraobserver reliability were observed for both imaging modalities and among the four examiners. Statistical analyses using ROC curves demonstrated that the CBCT images had a larger area under the curve (0.940) than the panoramic radiographs (0.579).

**Conclusion:** Three-dimensional evaluation of the sinus with CBCT was significantly more reliable in detecting pathology than panoramic imaging. (*Imaging Sci Dent* 2015; 45: 169-74)

**KEY WORDS:** Dental Implants; Maxillary Sinus; Cone-Beam Computed Tomography; Radiography, Panoramic

### Introduction

Restoring edentulous spaces in the mouth with endosseous dental implants is increasingly common. The success of dental implants is dependent upon several important considerations. A key challenge for implant placement is insufficient bone volume at the proposed implant site, which is a very common problem encountered in the rehabilitation of the edentulous posterior maxilla with dental implants. Bone volume in this region is limited by the presence of the maxillary sinus, its continuous pneumatization, and the progressive resorption of alveolar bone

height.<sup>1,2</sup>

One of the most effective ways to manage reduced vertical bone height in the posterior maxilla is the maxillary sinus elevation technique.<sup>1</sup> Several surgical techniques have been developed to augment the sinus floor. Regardless of the technique employed, postsurgical complications such as infections, failure of the graft, and sinus membrane perforation may ultimately lead to the failure of the surgical procedure. Evidence indicates that failure of the surgery may be associated with pre-existing sinus disease or a documented susceptibility to sinus disease.<sup>3-11</sup> Therefore, the proper preoperative evaluation of the maxillary sinuses prior to any augmentation is essential for minimizing postoperative complications and increasing the likelihood that the procedure will succeed.<sup>11</sup>

Many radiographic imaging techniques have been employed to study the maxillary sinus. The panoramic radio-

Received January 21, 2015; Revised June 3, 2015; Accepted June 9, 2015

\*Correspondence to : Dr. Aditya Tadinada

Department of Oral and Maxillofacial Radiology, University of Connecticut Health Center, 263 Farmington Avenue, Farmington, CT, 06030, USA  
Tel) 1-860-679-7527, Fax) 1-860-679-2719, E-mail) tadinada@uconn.edu

Copyright © 2015 by Korean Academy of Oral and Maxillofacial Radiology

This is an Open Access article distributed under the terms of the Creative Commons Attribution Non-Commercial License (<http://creativecommons.org/licenses/by-nc/3.0>) which permits unrestricted non-commercial use, distribution, and reproduction in any medium, provided the original work is properly cited.

Imaging Science in Dentistry · pISSN 2233-7822 eISSN 2233-7830

graph is the most common two-dimensional radiographic image projection used by a majority of dentists for a generalized evaluation of the orofacial complex.<sup>12,13</sup> Although panoramic radiographs are useful for obtaining an overview of the orofacial complex, they have certain inherent limitations, such as unequal magnification and geometric distortion across the image layer, leading to an inaccurate depiction of anatomy and pathology as well as unreliable measurement accuracy. Occasionally, the presence of overlapping structures, such as the cervical spine, can lead to misdiagnosis. Furthermore, clinically important objects may be situated outside the plane of focus (the image layer) and may appear distorted or not present. Pathology associated with the medial wall of the maxillary sinus is often not visualized on a panoramic radiograph.<sup>12,14</sup> Therefore, panoramic radiographs are not a reliable method of predicting the likelihood of sinus pathology.<sup>12</sup> Obtaining a three-dimensional view using computed tomography (CT) is a more accurate method of studying the maxillary sinus.<sup>12</sup> For many years, CT was preferred for the preoperative examination of the maxillary sinus prior to implant placement, because it enhances the evaluation of the anatomical structures and minimize the risks involved with the surgical procedure.<sup>13</sup> Although conventional CT has become the imaging modality of choice for evaluating the maxillary sinus, its high cost, radiation dose, and availability have restricted its use in routine dental practice.

The introduction of cone-beam computed tomography (CBCT) has provided a relatively low-dose and high-resolution alternative for imaging the maxillofacial region.<sup>15</sup> With its low cost, low radiation dose, and high spatial resolution, CBCT is becoming the modality of choice for evaluating potential implant sites, especially in complex cases that require three-dimensional views of the area of interest.<sup>15,16</sup>

The objective of the present study was to evaluate to evaluate the diagnostic efficacy of panoramic radiography and CBCT in diagnosing pathology in the maxillary sinus prior to dental implant therapy. We also propose a radiographic classification of sinus pathology relevant to the surgical augmentation of the floor of the maxillary sinus.

## Materials and Methods

An existing database of radiographic images from the archives of the Department of Oral and Maxillofacial Radiology of the School of Dental Medicine of the University of Connecticut was used in this study. All CBCT images were obtained with a CB MercuRay CBCT machine

(Hitachi Medical Corporation, Tokyo, Japan). The images were all acquired using a six-inch field of view at 120 kVp and 15 mA with a voxel size of 0.2 mm. The panoramic images were acquired using the standard adult setting mode on a Planmeca panoramic machine (Planmeca USA, Roselle, IL, USA). A deidentified data set of images of patients was created by using CB Works 3.0 (Cyber Med Corporation, Seoul, South Korea). All HIPAA markers were scrubbed from the Digital Imaging and Communications in Medicine (DICOM) data of the CBCT acquisitions and the panoramic images. An institutional review board exemption for the evaluation of the deidentified radiographic images was obtained. The selection criteria included patients who had undergone both a panoramic radiograph and a six-inch field of view CBCT scan for implant treatment planning.

In this study, we sought to identify any clinically relevant and radiographically evident pathology, including mucosal thickening, odontogenic sinusitis, allergic sinusitis, mucus retention cysts, antroliths, oroantral communications, partial to complete sinus obliteration, mucoceles, mucopyocele, and patency of the ostium and the osteomeatal complex.

Initially, 100 CBCT scans acquired for maxillary implant placement were obtained. However, as per the inclusion criteria, only 50 cases had both a CBCT scan and a panoramic radiograph. Ultimately, 50 cases with a total of 100 maxillary sinuses were evaluated. Each sinus (two per case) was treated as a separate and independent entity for evaluation. All CBCT images were viewed as reconstructed images from the acquired volume in the DICOM 3 (.dcm) format, and all panoramic images were viewed as JPEG images. All images were viewed on an HP Compaq DC7800 computer (Hewlett-Packard Company, 3000 Hanover Street, Palo Alto, CA, USA) under standardized lighting conditions. The examiners were given the ability to manipulate the contrast and magnification on all panoramic images. CBCT acquisitions were reviewed using the CB Works 3.0 software (CyberMed Inc., Seoul, South Korea) with the ability to view the volume acquisition in total via the multiplanar reconstruction mode showing the axial, sagittal, and coronal views. The individual examiners had the ability to adjust and control the histogram and the contrast settings in the visualization software. The examiners also had the ability to view the acquired CBCT volume as axial, sagittal, coronal, and cross-sectional images. The examiners were able to scroll through the entire volume and were given the capability to reconstruct the entire volume as corrected cross-sectional images of the

desired thickness.

Four examiners, including one experienced periodontist, one oral and maxillofacial radiologist, and two periodontists in training, evaluated the deidentified set of maxillary sinus images using the following scale to represent the presence of sinus pathology: 1, definitely present; 2, probably present; 3, uncertain if present; 4, probably not present; and 5, definitely not present.

All examiners were given a training session demonstrating the functions of the software prior to evaluating the images. They were also shown panoramic and CBCT images of the most common pathological conditions occurring in the maxillary sinus, as well as panoramic and CBCT images of normal, disease-free maxillary sinuses.

The examiners evaluated the maxillary sinus to identify any pathology associated with the sinus. The pathological conditions included thickening of the mucoperiosteal lining of the floor of the maxillary sinus, sinusitis, mucus retention cysts associated with the floor, lateral or medial walls, infections, bony septations, antroliths, mucocoeles, neoplasms, and any other unusual appearance associated with the sinus, as previously described.

All evaluations were performed twice with an interval of at least two weeks, in order to assess interobserver and intraobserver reliability. The examiners were blinded to the details of the image they were reviewing, with the exception of a random identification number attached to each image.

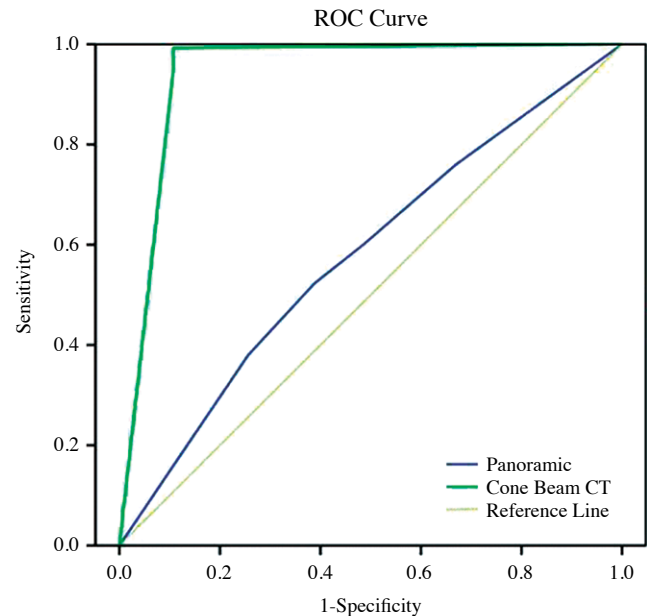
Statistical analyses of the data collected from the individual evaluation sessions were performed using SPSS version 12.0 for Windows (SPSS Corp. Chicago, IL, USA). Cronbach's alpha was calculated to assess intraobserver reliability, and Cohen's kappa was calculated to evaluate interobserver reliability. Receiver operating characteristic (ROC) curve analysis was performed to evaluate the diagnostic efficacy of the two imaging modalities and their ability to detect sinus pathology.

## Results

The analyses showed that 72% of the patients included in this study exhibited maxillary sinus pathology. High interobserver and intraobserver reliability were found for both imaging modalities and among the four examiners (Table 1). Although the panoramic radiographs scored high on the reliability scale, the examiners selected the option 'unsure if present' more frequently than they indicated the definitive presence or absence of pathology, indicating that this imaging modality is less useful clinical-

**Table 1.** Interobserver reliability in the evaluation of mucosal thickening using panoramic radiography and cone-beam computed tomography (CBCT).

Cronbach's alpha for CBCT	Cronbach's alpha on standardized items	Number of items
0.892	0.892	2
Cronbach's alpha for panoramic radiographs	Cronbach's alpha on standardized items	Number of items
0.873	0.873	2



**Fig. 1.** Receiver operating characteristic (ROC) curves for panoramic radiography and cone-beam computed tomography (CT).

ly. The ROC analysis showed that CBCT had a larger area under the curve (0.940) than the panoramic radiographs (0.579). The panoramic radiographs showed high sensitivity but low specificity, whereas CBCT showed high sensitivity and specificity for identifying maxillary sinus pathology (Fig. 1).

## Discussion

The purpose of the present study was to evaluate the diagnostic efficacy of panoramic radiography and CBCT with regard to diagnosing pathology in the maxillary sinus. A retrospective analysis of radiographic images was performed, examining the maxillary sinus using a five-point scale to score the presence or absence of pathology, ranging from mild thickening of the mucoperiosteal lining to complete obliteration of the sinus.

The maxillary posterior teeth have a higher morbidity rate than the rest of the teeth in the oral cavity.<sup>17</sup> Replacement of these teeth is important to treat occlusion and to restore function. Traditionally, removable partial dentures and fixed bridges have been used as restorative options, but it has become increasingly common to replace missing teeth with dental implants.<sup>17</sup> The long-term success of dental implants depends on the availability of bone in the proposed implant site. In situations where the bone volume is inadequate, the floor of the sinus is lifted to create the desired amount of space for the placement of a graft material.<sup>18,19</sup>

Evaluating the maxillary sinus for mucosal thickening and pathology is essential prior to implant treatment. In this study, 72% of the patients showed presence of some degree of pathology in the maxillary sinus. The most common finding was mucosal thickening of varying degrees. This is significantly higher than the range that has been reported in the literature for a normal population.<sup>20,21</sup> The presence of pathology is a potential contraindication for the procedure. Therefore, the clinician must adequately plan the procedure prior to surgery. Radiographic examination is a crucially important tool for the detection of sinus pathology.<sup>14,15</sup> In the present study, the diagnostic abilities of panoramic radiography and CBCT were evaluated using an ROC analysis. In ROC curve analyses, a larger area under the curve corresponds to a greater diagnostic ability. The panoramic images had a value of 0.579 for the detection of pathology, which reflects a performance only slightly better than chance or the flip of a coin. In comparison, CBCT was able to detect the presence of pathology with an area under the curve of approximately 0.94, indicating a very high detection capability, which corresponds to the findings of previous studies<sup>12,22</sup>.

In the present study, high interobserver and intraobserver reliability was observed for both imaging modalities. Although the panoramic radiographs scored high on the reliability scale, the examiners selected the option indicating uncertainty regarding the presence of pathology more frequently than they indicated the definitive presence or absence of pathology, underscoring the diagnostic unreliability of this imaging modality. Studies have shown that discrepancies exist in skeletal symmetry in normal adults,<sup>23</sup> and two-dimensional images are therefore far from reliable, especially when evaluating the area of interest for potential surgical augmentation. The outcomes of our study show that pathological entities may be undetected, leading to the potential failure of the procedure. Since the panoramic radiographs were unable to show

pathology in close to half of the sample size (43%), pre-operative treatment planning using this projection is not reliable. Due to the magnification of depicted anatomic structures in the image layer, the height and width measurements in the sinus floor-alveolar ridge area are grossly misrepresented. This information could be pivotal in making a decision about the length and type of implant to use, as well as the need for sinus augmentation.<sup>24,25</sup> Three-dimensional evaluation of the maxillary sinus is helpful to analyze the maxillary sinus in detail, since it provides an adequate depiction of the medial and lateral walls of the sinus along with the floor, thus showing all the anatomical boundaries of the sinus and reducing the risk of complications. The patency of the osteomeatal complex and the absence of any signs of inflammation and infection are potentially vital factors for the success of sinus augmentation procedures.

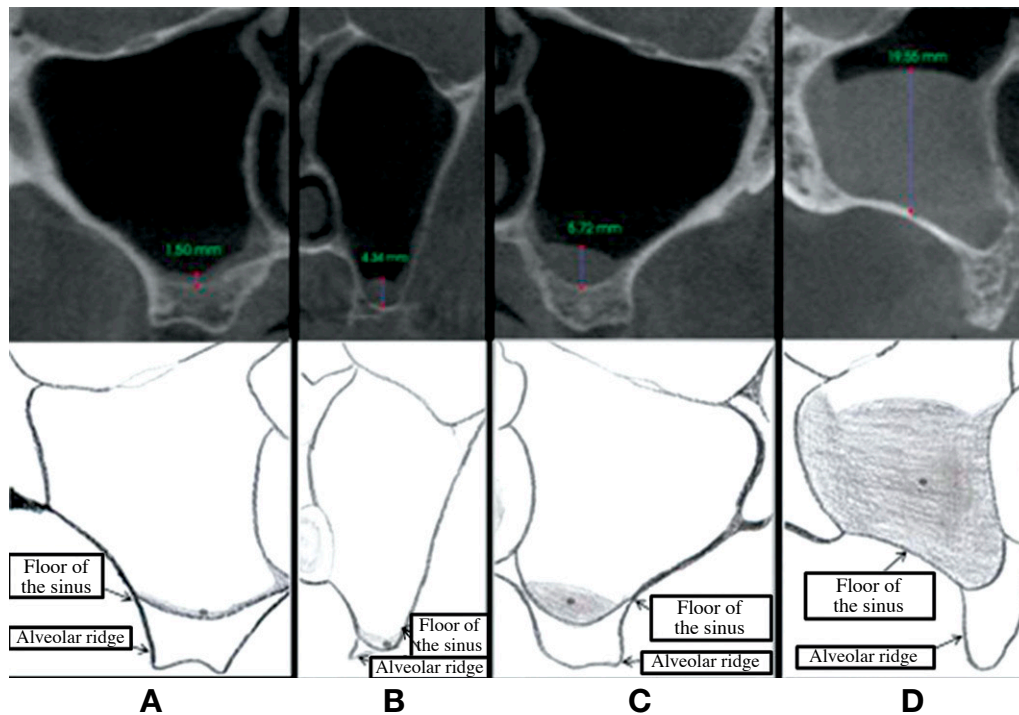
This study analyzed a sample of patients requiring implant therapy in the posterior maxilla, which was likely not a representative sample of the population at large. Nonetheless, the results of our study do pose an important question about the evaluation of the maxillary sinus prior to augmentation. Sinusitis is an extremely common chronic disease, affecting at least over a million Americans. Evidence has been found indicating that dental pathological findings are associated with mucosal thickening, and that 10%-12% of cases of maxillary sinusitis, including mucous thickening, are caused by dental infections.<sup>26-28</sup> Thus, we may hypothesize that by treating a dental infection, a dentist can prevent mucous thickening, thereby possibly prevent the development of maxillary sinusitis. It is therefore advisable to adequately examine the maxillary sinus, treat any pathology that is found, and obtain desirable results before attempting any surgical augmentation.

Although the primary question posed by this study was to evaluate the diagnostic abilities of two imaging modalities to detect pathology, the mere presence of radiographic thickening of the mucoperiosteal lining of the floor of the sinus is not necessarily a contraindication to sinus augmentation. This creates a dilemma for the clinician as to when it is safe to enter the sinus to perform augmentation and when it is contraindicated. No guidelines exist to help the clinician plan augmentation of the maxillary sinus.

In 1994, Newman et al.<sup>29</sup> presented a classification of radiographic thickening of the sinus mucosa as visualized on CT scans and its relationship with allergy and asthma. Although several classification systems of sinusitis exist,

**Table 2.** Proposed classification of sinus augmentation procedures with regard to mucosal thickening in the maxillary sinus.

	Mucosal thickening	Recommendation
Class 1	A. Absence of radiographic pathology B. 0-2 mm of radiographic thickening	Sinus augmentation can be performed without any possible risk of complications.
Class 2	2-5 mm of radiographic thickening	Sinus augmentation can be performed, but with caution.
Class 3	6-9 mm of radiographic thickening with or without partial obliteration of the maxillary sinus	Contraindicated for sinus augmentation; should be referred to ear, nose, and throat surgeon for consultation.
Class 4	>9 mm, including partial to complete obliteration of the maxillary sinus	Contraindicated for sinus augmentation, should be referred to ear, nose, and throat surgeon for consultation.

**Fig. 2.** Radiographic and schematic views of the proposed classification of mucosal thickening in the maxillary sinus. 0-2 mm (A), 2-5 mm (B), 5-9 mm (C), 9 mm (D) to complete obliteration of the sinus. Mucosal thickening is marked by \*.

no classification takes radiographic thickening into account and provides guidelines with regard to sinus augmentation. In the classification proposed in this study, we divide the radiographic findings into four classes and provide guidelines regarding maxillary sinus floor augmentation for dental implant therapy.

We propose a classification that will help the clinician decide when to attempt an augmentation procedure involving the sinus, using a sinus lift and graft procedure, and when to refrain from performing any surgical augmentation and to seek a consultation from an ear, nose, and throat (ENT) surgeon (Table 2, Fig. 2). In this classification, the absence of any radiographic pathology up to

the presence of approximately 2 mm of thickening of the sinus lining is consistent with safe surgical augmentation. Radiographic thickening of 2-5 mm is not an absolute contraindication for augmenting the sinus, but caution should be exercised in cases with that amount of radiographic thickening, especially if the numbers are in the higher end of the range. A comprehensive clinical examination along with a detailed history of the patient's allergies and previous episodes of headaches and/or other orofacial pain should be carefully recorded prior to attempting surgery. Radiographic thickening measuring 6-9 mm, with or without partial obliteration of the sinus, is a contraindication for sinus augmentation. The presence of

6-9 mm of radiographic thickening is an indication of either inflammation or infection due to a variety of causes, ranging from odontogenic sinusitis to a mucocele. Entering the sinus in the presence of active disease of that type will lead to potential complications. Referring patients with such findings to an ENT surgeon is indicated to ensure that the pathology is addressed. Complete obliteration of the sinus is an obvious contraindication for sinus augmentation and puts the patient at high risk for complications. A referral to an ENT surgeon is recommended to diagnose, manage, and resolve the situation prior to attempting any surgical augmentation. The results of this study showed that three-dimensional imaging of the maxillary sinus using CBCT proved to be significantly more reliable for detecting sinus pathology than panoramic radiography.

## References

1. Jivraj S, Chee W, Corrado P. Treatment planning of the edentulous maxilla. *Br Dent J* 2006; 201: 261-79.
2. Wallace SS, Froum SJ. Effect of maxillary sinus augmentation on the survival of endosseous dental implants. A systematic review. *Ann Periodontol* 2003; 8: 328-43.
3. Tatum H Jr. Maxillary and sinus implant reconstructions. *Dent Clin North Am* 1986; 30: 207-29.
4. Misch CE. Maxillary sinus augmentation for endosteal implants: organized alternative treatment plans. *Int J Oral Implantol* 1987; 4: 49-58.
5. Smiler DG, Holmes RE. Sinus lift procedure using porous hydroxyapatite: a preliminary clinical report. *J Oral Implantol* 1987; 13: 239-53.
6. Wood RM, Moore DL. Grafting of the maxillary sinus with intraorally harvested autogenous bone prior to implant placement. *Int J Oral Maxillofac Implants* 1988; 3: 209-14.
7. Kent JN, Block MS. Simultaneous maxillary sinus floor bone grafting and placement of hydroxyapatite-coated implants. *J Oral Maxillofac Surg* 1989; 47: 238-42.
8. Misch CE, Dietsh F. Bone-grafting materials in implant dentistry. *Implant Dent* 1993; 2: 158-67.
9. Summers RB. The osteotome technique: Part 3 - Less invasive methods of elevating the sinus floor. *Compendium* 1994; 15: 698-710.
10. Bruschi GB, Scipioni A, Calesini G, Bruschi E. Localized management of sinus floor with simultaneous implant placement: a clinical report. *Int J Oral Maxillofac Implants* 1998; 13: 219-26.
11. Fugazzotto PA, De PS. Sinus floor augmentation at the time of maxillary molar extraction: success and failure rates of 137 implants in function for up to 3 years. *J Periodontol* 2002; 73: 39-44.
12. Shahbazian M, Vandewoude C, Wyatt J, Jacobs R. Comparative assessment of panoramic radiography and CBCT imaging for radiodiagnostics in the posterior maxilla. *Clin Oral Investig* 2014; 18: 293-300.
13. Rege IC, Sousa TO, Leles CR, Mendonça EF. Occurrence of maxillary sinus abnormalities detected by cone beam CT in asymptomatic patients. *BMC Oral Health* 2012; 12: 30.
14. Nah KS. The ability of panoramic radiography in assessing maxillary sinus inflammatory diseases. *Korean J Oral Maxillofac Radiol* 2008; 38: 209-13.
15. Maillet M, Bowles WR, McClanahan SL, John MT, Ahmad M. Cone-beam computed tomography evaluation of maxillary sinusitis. *J Endod* 2011; 37: 753-7.
16. Li G. Patient radiation dose and protection from cone-beam computed tomography. *Imaging Sci Dent* 2013; 43: 63-9.
17. Hirschfeld L, Wasserman B. A long-term survey of tooth loss in 600 treated periodontal patients. *J Periodontol* 1978; 45: 225-37.
18. Esposito M, Grusovin MG, Felice P, Karatzopoulos G, Worthington HV, Coulthard P. Interventions for replacing missing teeth: horizontal and vertical bone augmentation techniques for dental implant treatment. *Cochrane Database Syst Rev* 2009; 4: CD003607.
19. Esposito M, Grusovin MG, Rees J, Karasoulos D, Felice P, Alissa R, et al. Effectiveness of sinus lift procedures for dental implant rehabilitation: a Cochrane systematic review. *Eur J Oral Implantol* 2010; 3: 7-26.
20. Van Cauwenberge P, Watelet J. Epidemiology of chronic rhinosinusitis. *Thorax* 2000; 55 Suppl 2: S20-1.
21. Gordts F, Clement PA, Buisseret T. Prevalence of sinusitis signs in a non-ENT population. *ORL J Otorhinolaryngol Relat Spec* 1996; 58: 315-9.
22. Baciut M, Hedesi M, Bran S, Jacobs R, Nackaerts O, Baciut G. Pre- and postoperative assessment of sinus grafting procedures using cone-beam computed tomography compared with panoramic radiographs. *Clin Oral Implants Res* 2013; 24: 512-6.
23. Sanders DA, Chandhoke TK, Uribe FA, Rigali PH, Nanda R. Quantification of skeletal asymmetries in normal adolescents: cone-beam computed tomography analysis. *Prog Orthod* 2014; 15: 26.
24. Yim JH, Ryu DM, Lee BS, Kwon YD. Analysis of digitalized panorama and cone beam computed tomographic image distortion for the diagnosis of dental implant surgery. *J Craniofac Surg* 2011; 22: 669-73.
25. Guerrero ME, Jacobs R, Loubele M, Schutyser F, Suetens P, van Steenberghe D. State-of-the-art on cone beam CT imaging for preoperative planning of implant placement. *Clin Oral Investig* 2006; 10: 1-7.
26. Brook I. Sinusitis of odontogenic origin. *Otolaryngol Head Neck Surg* 2006; 135: 349-55.
27. Mehra P, Jeong D. Maxillary sinusitis of odontogenic origin. *Curr Infect Dis Rep* 2008; 10: 205-10.
28. Mehra P, Murad H. Maxillary sinus disease of odontogenic origin. *Otolaryngol Clin North Am* 2004; 37: 347-64.
29. Newman LJ, Platts-Mills TA, Phillips CD, Hazen KC, Gross CW. Chronic sinusitis. Relationship of computed tomographic findings to allergy, asthma, and eosinophilia. *JAMA* 1994; 271: 363-7.