

Arthroscopic Treatment of Isolated Teres Minor Tendon Tear: A Case Report

Se-Won Lee, Sang-Eun Park, Min-Gyu Park, Jong-Hun Ji[✉]

Department of Orthopedic Surgery, The Catholic University of Korea, Daejeon St. Mary's Hospital, Daejeon, Korea

Arthroscopic repair of an isolated teres minor tendon tear without associated shoulder joint pathology has not been reported in the literature. We report on a case of isolated teres minor tendon tear after trauma. The patient complained of severe shoulder pain and progressive limited range of motion 4 months after the injury. Magnetic resonance imaging showed a full-thickness tear of the teres minor tendon at its musculotendinous junction and arthroscopic repair was performed. At 2 years follow-up, satisfactory clinical and radiological outcomes were observed with return to pre-injury level. Here, the authors report this case and provide a review of literature.

(*Clin Shoulder Elbow* 2015;18(3):159-161)

Key Words: Teres minor tear; Musculotendionus junction; Arthroscopic repair

The teres minor, which functions primarily in external rotation of the arm and secondarily in depression of the humeral head, provides up to 45% of external rotation power to the glenohumeral joint. Teres minor tendon tears are usually associated with other rotator cuff tendon tears,^{1,2)} particularly with infraspinatus tendon tears. Only a few studies describing teres minor injuries treated conservatively in a situation of combined other rotator cuff injuries have been reported. Isolated teres minor tendon tear is a rare disease entity. Hottya et al.³⁾ reported two cases with isolated teres minor tear at its tendinous portion but they did not describe their treatment and outcomes.

There are no reports on treatment and outcomes of an isolated teres minor tear, therefore, the purpose of the current case study is to report on arthroscopic treatment and its outcome of the isolated teres minor tear and to review the literature.

Case Report

A 52-year-old right handed woman visited Daejeon St. Mary's Hospital with a complaint of right posterior shoulder pain for 4 months after trauma. She had fallen on the outstretched arm due to a slippery poolside. Although she could not precisely

remember her trauma, she initially felt that her shoulder was dislocated and then reduced. She underwent physical therapy and received medication during a period of 4 months in local clinics; however, her symptoms were not improved. She demonstrated tenderness at the posterior aspect of her right shoulder and painful limitation of range of motion (ROM). Instability tests including anterior drawer and posterior drawer test were negative. Neer and Hawkin tests were positive. Shoulder ROM was as follows: 120° forward flexion, 120° abduction, 10° external rotation, and internal rotation up to buttock. Normal findings were observed on plain radiographs. Her shoulder magnetic resonance imaging (MRI) was already previously checked in a local hospital at the time of the visit, revealing an isolated teres minor tear with edema at its musculo-tendinous junction (Fig. 1). Diagnostic arthroscopy was scheduled with consideration for characteristics of severe progressive pain. Her preoperative clinical scores were as follows: American Shoulder Elbow Society (ASES) score: 1.5, University of California at Los Angeles (UCLA) score: 11, simple shoulder test (SST) score: 0, Constant score (CS): 45.

After a standard posterior portal and anterior portal were made, diagnostic arthroscopy was performed. Although no labral injury was found, a posterior capsular rupture was observed. The

Received April 14, 2015. **Revised** May 16, 2015. **Accepted** July 4, 2015.

[✉]**Correspondence to:** Jong-Hun Ji

Department of Orthopedic Surgery, The Catholic University of Korea, Daejeon St. Mary's Hospital, 64 Daeheung-ro, Jung-gu, Daejeon 34943, Korea
Tel: +82-42-220-9530, **Fax:** +82-42-221-0429, **E-mail:** jijh87@gmail.com

Financial support: None. **Conflict of interests:** None.

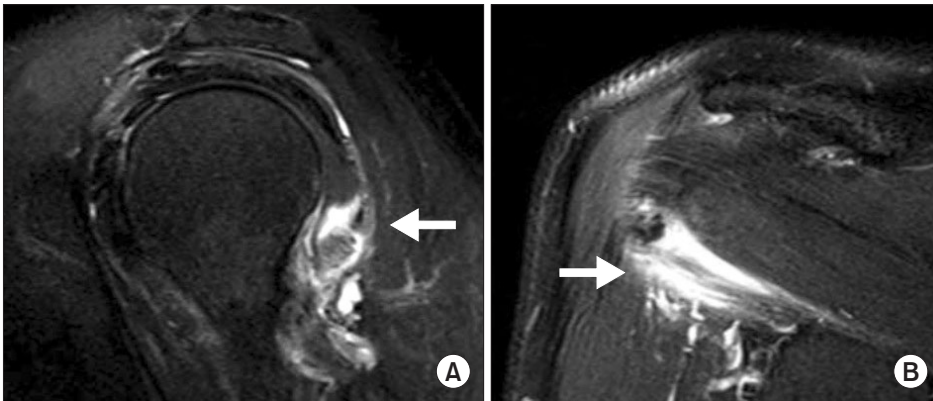


Fig. 1. Preoperative magnetic resonance imaging showing a teres minor tear at its musculotendinous junction (arrows). (A) Sagittal view. (B) Oblique coronal view.

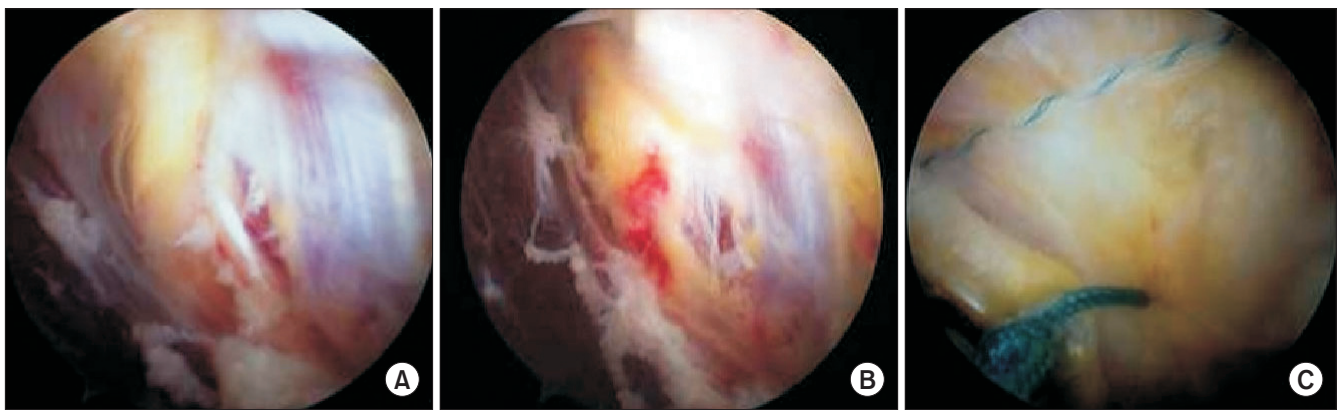


Fig. 2. (A) Arthroscopic picture of an isolated teres minor tear at its musculotendinous junction. (B) Hematoma within the substance of the teres minor muscle. (C) Final repair status.

arthroscope was moved into the subacromial space. The bursal surfaces of the supraspinatus and the subscapularis were normal. A full thickness tear of the teres minor tendon was found at its musculotendinous junction. Hematoma and torn muscle fibers were found in the substance of the teres minor tendon (Fig. 2A, B). In the glenohumeral joint, a suture anchor (5.5 mm Twin Fix Ti; Smith & Nephew, Andover, MA, USA) was inserted into the posterior margin of the bare area through the posterior portal, and then threads of the suture anchor were passed into the teres minor tendon. Accordingly an additional posterolateral portal was made. The torn edge of the teres minor tendon was debrided, and then repaired using a previously inserted suture anchor loaded with 2 No. 2 Ultrabraid (Teleflex Medical, Wayne, PA, USA) suture threads and side to side repair using Ethibond No. 2 (Ethicon, Somerville, NJ, USA) for the tear (Fig. 2) through an additional posterolateral portal while viewing from the standard posterior portal. We had to be careful to protect the neurovascular structures such as the posterior circumflex humeral artery and the axillary nerve in the quadrilateral space during passage of sutures because these are bordered with the inferior margin of the teres minor.

Pendulum exercises were started on the second day after the

operation. The patient was given a shoulder brace to be worn in 15° abduction and 10° external rotation. Active shoulder mobilization was started after 6 weeks and strengthening exercises were started after 3 months. The patient was discharged home 1 week postoperatively and advised to report regularly to the out-patient clinic for follow-up assessment. At 2 years follow-up, postoperative clinical scores were as follows: shoulder subjective score: 95, ASES score: 90, UCLA score: 33, SST score: 11, CS: 85 and shoulder ROM was as follows: Forward flexion 165°, abduction 165°, external rotation at side 20° and internal rotation up to the thoracolumbar junction. Follow-up MRI performed 9 months after the operation showed good healing of the tendon at the repair site and Sugaya type II healing status (Fig. 3).

Discussion

Despite numerous reports in the orthopedic literature on rotator cuff tears, the teres minor tendon has received little attention in the literature. Isolated tears of the teres minor tendon are relatively rare. In the current case, MRI showed an isolated teres minor tendon tear in a 52-year-old female which was treated using an arthroscopic technique. This patient was injured when

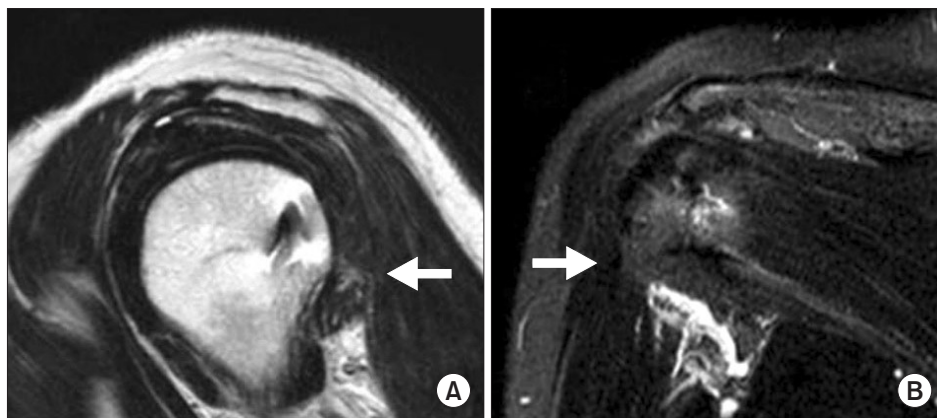


Fig. 3. Postoperative magnetic resonance imaging at 9 months showing good healing at the repair site (arrows). (A) Sagittal view. (B) Oblique coronal view.

she fell on the outstretched arm. At the time of the accident, the patient had felt a sense of shoulder dislocation. Hence, it was thought that an unrecognized posterior shoulder subluxation might have occurred when she fell, because it was the typical injury mechanism for posterior shoulder dislocation or subluxation.⁴⁾

One author reported the correlation between posterior shoulder dislocation and teres minor tear. In an experimental study, Ovesen and Sjöbjerg⁴⁾ reported that posterior shoulder dislocation was made artificially in a cadaveric model. In all specimens, total rupture of the posterior capsule and teres minor were shown and partial tear of infraspinatus was observed in most cases. It showed that when posterior shoulder dislocation occurred, the teres minor injury should be considered and vice versa. Hottya et al.,³⁾ who reported four cases of teres minor muscle injury after posterior shoulder dislocation injury, described two of four patients with a teres minor tear at its tendinous portion without other rotator cuff tendon tear. They could not suggest the exact reason for correlation between posterior shoulder dislocation and teres minor muscle, they assumed that inseparation between the underbelly of the teres minor muscle and the posterior capsule of the glenohumeral joint⁵⁾ might explain associated injuries to teres minor during posterior capsular damage. They did not describe clinical results of their follow-up and how teres minor tendon tear was treated and questioned that no consensus exists as to whether posterior capsular injuries and teres minor tear should be treated surgically or conservatively.

On the assumption that posterior shoulder dislocation had occurred with MRI showing only an isolated full-thickness teres minor tendon tear, we thought that posterior labral tear or posterior capsular tear should be considered. Although magnetic resonance arthrography is more sensitive for detection of labral tears than conventional MRI,⁶⁾ we decided to perform diagnostic arthroscopy under the consideration that the characteristics of the patient's pain were severe and progressive during a period of 4 months and high MRI cost. No concomitant posterior labral lesion which could be diagnosed as a reverse Bankart lesion was

observed, except a full-thickness teres minor tear on the arthroscopy.

Despite general consensus that the musculotendinous junction area has relatively better healing potential compared with the tendinous area,⁷⁾ in this instance the arthroscopic repair of isolated teres minor tear at the musculo-tendinous junction was performed concomitantly during diagnostic arthroscopy. When there is a diagnosis of isolated teres minor tear, posterior dislocation/subluxation or equivalent injury should be suspected. We think arthroscopy is a useful means in diagnosis and treatment of an isolated teres minor tear.

References

1. Chafik D, Galatz LM, Keener JD, Kim HM, Yamaguchi K. Teres minor muscle and related anatomy. *J Shoulder Elbow Surg.* 2013;22(1):108-14.
2. Melis B, DeFranco MJ, Lädermann A, Barthelemy R, Walch G. The teres minor muscle in rotator cuff tendon tears. *Skeletal Radiol.* 2011;40(10):1335-44.
3. Hottya GA, Tirman PF, Bost FW, Montgomery WH, Wolf EM, Genant HK. Tear of the posterior shoulder stabilizers after posterior dislocation: MR imaging and MR arthrographic findings with arthroscopic correlation. *AJR Am J Roentgenol.* 1998;171(3):763-8.
4. Ovesen J, Sjöbjerg JO. Posterior shoulder dislocation. Muscle and capsular lesions in cadaver experiments. *Acta Orthop Scand.* 1986;57(6):535-6.
5. Petersilge CA, Witte DH, Sewell BO, Bosch E, Resnick D. Normal regional anatomy of the shoulder. *Magn Reson Imaging Clin N Am.* 1993;1(1):1-18.
6. Magee T, Williams D, Mani N. Shoulder MR arthrography: which patient group benefits most? *AJR Am J Roentgenol.* 2004;183(4):969-74.
7. Hanna CM, Glennly AB, Stanley SN, Caughey MA. Pectoralis major tears: comparison of surgical and conservative treatment. *Br J Sports Med.* 2001;35(3):202-6.