

RESEARCH ARTICLE

Retrospective Study of Adjuvant Chemotherapy Effects on Survival Rate after Three-Field Lymph Node Dissection for Stage IIA Esophageal Cancer

Hua-Xia Chen, Zhou Wang*

Abstract

To determine the efficacy of postoperative adjuvant chemotherapy with paclitaxel plus cisplatin (Taxol + DDP, TP therapy) for stage IIA esophageal squamous cell carcinoma (ESCC) and to investigate the expression of RUNX3 in lymph node metastasis-negative esophageal cancer and its relationship with medical prognosis, a retrospective summary of clinical treatment of 143 cases of stage IIA esophageal squamous cell carcinoma patients was made. The patients were divided into two groups, a surgery alone control group (52 patients) and a chemotherapy group that received postoperative TP therapy (91 patients). The disease-free and 5 year survival rates were compared between the groups and a multivariate analysis of prognostic factors was performed. The same analysis was performed for cases classified as RUNX3 positive and negative, with post-operative specimens assessed by immunohistochemistry. Although the disease-free and 5 year survival rates in control and chemotherapy groups did not significantly differ and there was no significance in RUNX3 negative cases, postoperative adjuvant chemotherapy in the chemotherapy group was shown to improve disease-free and 5 year survival rate compared to the control group in RUNX3 positive cases. On Cox regression multivariate analysis, postoperative adjuvant chemotherapy ($P < 0.01$) was an independent prognostic factor for RUNX3 positive cases, suggesting that postoperative TP may be effective as adjuvant chemotherapy for stage IIA esophageal cancer patients with RUNX3 positive lesions.

Keywords: TP therapy - esophageal cancer - RUNX3 - postoperative adjuvant chemotherapy

Asian Pac J Cancer Prev, 16 (13), 5169-5173

Introduction

Esophageal squamous cell cancer (ESCC) accounts for about 90% of all esophageal cancer diagnosed in China, as technology evolves, many ESCC patients are detected cancer at early stage in China (Lu et al., 2014). Surgical resection still remains the preferred treatment and the best choice for ESCC (Mirinezhad et al., 2014). Despite of surgery alone is usually curative for early stage tumor, the 5 year survival rate of those postoperative patients remains low, even after extended surgery (Mariette et al., 2007). Therefore, a multimodal approach, including postoperative adjuvant therapy, is essential to further improve operation success rate for ESCC patients.

Paclitaxel plus Cisplatin (Taxol+DDP, TP regimen) therapy has been clearly demonstrated to be a viable option in the postoperative adjuvant chemotherapy setting for patients with lymph node metastasis from esophageal cancer (Leonard et al., 2004). However, the role of adjuvant chemotherapy for lymph node metastasis-negative esophageal cancer is still unclear. Few clinicians have studied the survival advantage conferred on patients

with stage IIA disease by Adjuvant chemotherapy (Ando et al., 2003). As an important tumor suppressor gene, RUNX3 is found in many different types of cancer, many studies have demonstrated that ESCC cells with RUNX3 up-regulated had a significantly improved chemotherapeutic sensitivity as compared with RUNX3 negative control (Hiramatsu et al., 2005).

In this study, we used the clinical data, combined with follow-up results, analyzed the efficacy of treatment with TP therapy as postoperative adjuvant chemotherapy in stage IIA middle thoracic ESCC patients who underwent Ivor-Lewis surgery with three-field lymph node dissection. The patients were also grouped according to RUNX3 expression in order to identify a subgroup that may benefit from chemotherapy therapy. The purpose of this study was to explore RUNX3 expression to predict chemotherapy sensitivity of stage IIA ESCC after esophagectomy and to provide the basis for adopting targeted adjuvant treatment in these patients, determine which patient subgroups among patients with RUNX3 expression may benefit from TP as postoperative adjuvant chemotherapy.

Department of Thoracic Surgery, Provincial Hospital Affiliated to Shandong University, Jinan, China *For correspondence: w:620226@hotmail.com

Materials and Methods

Case selection

A total of surgical specimens were collected from 143 patients with stage IIA middle thoracic ESCC who underwent Ivor-Lewis surgery with three-field lymph node dissection in the Department of Thoracic Surgery, Provincial Hospital Affiliated to Shandong University from January 2005 to January 2008. The inclusion criteria were as follows: *i*) No residual tumor cells on upper or lower cutting edge checked by pathology, lateral margins with no residual focus, the number of lymph nodes dissected was more than nine; *ii*) The tumors were diagnosed histologically as squamous cell carcinoma, disease stage redetermined according to the tumor, node, metastasis staging system (TNM) classification established by Union for International Cancer Control (UICC) in 2009, all patients had stage IIA (pT2, 3N0M0) disease; *iii*) no preoperative treatment (chemotherapy, radiotherapy or chemoradiotherapy); *iv*) complete 5 year follow-up review; *v*) no perioperative complications; *vi*) postoperative time to chemotherapy >2 weeks and <2 months; *vii*) All patients and their relatives provided the informed consent, and the protocol was approved by the ethical committee of our institution.

Immunohistochemistry

Sections (4 μm thick) were heat fixed, deparaffinized, and rehydrated by standard methods. After the formalin-fixed, paraffin-embedded tissues were deparaffinized and antigen retrieved, tissue sections were incubated overnight at 4°C with the monoclonal mouse antihuman RUNX3 antibody (1:100, Santa Cruz, USA). After washing with PBS, the slides were incubated with biotinylated second antibody (1: 100, Zhongshan Biotech, China) for 30 min at 37°C, followed by streptavidin-peroxidase incubation at 37°C for 30 min. Finally, sections were colored with diaminobenzidine tetrahydrochloride (DAB) for 2 min. For negative controls, we replaced the primary antibody with phosphatebuffered saline. All sections were examined by two independent pathologists who were blinded to the clinical data. The stands for the intensity of staining with a value of 1, 2, or 3 (weak, moderate, or strong, respectively), and 1,2,3,4 stands for the percentage of stained cells for each intensity, varying from 0 to 100% (<5%, 5%-25%, 26%-50%, 51%-75%, >75%), Hscore= staining intensity score \times staining percentage score. The expression of RUNX3 of tumor cells was graded as positive when Hscore>1. Biopsies tumor cells showing immunostaining were considered negative when Hscore \leq 1.

Grouping and Adjuvant chemotherapy regimen

The patients were divided into two groups, a surgery alone group (Control group, 91 patients) and a group that received postoperative chemotherapy (Chemotherapy group, 52 patients). The postoperative adjuvant chemotherapy included Taxol 135 mg/m² on day 1 and DDP 75 mg/m² on day 1, completed at least 4 chemotherapy cycles, 21 days as one cycle. After RUNX3 protein expression detection by immunohistochemistry studies and western-blot in postoperative tumor specimens,

patients were divided into RUNX3 positive group and RUNX3 negative group and the 5 year survival were analyzed separately.

Statistical analysis

SPSS 19.0 computer software was used to construct a database. Survival difference was compared by χ^2 test, the Kaplan-Meier method was performed to calculate the survival rate. Cox regression multivariate analyses were performed to identify independent prognostic factors.

Results

Clinicopathological factors

The clinicopathological characteristics of the 143 patients are summarized in Table 1. There were no significant differences between the Control (91 patients) and Chemotherapy (52 patients) groups regarding clinicopathological factors. By immunohistochemical staining, the positive expression of RUNX3 protein showed as yellow or brownish yellow stain in the cytoplasm and/or nucleus of tumor cells. In 143 ESCC tissue samples, 83 were detected with RUNX3-positive expression: 28 RUNX3 nuclei expression and 55 RUNX3 cytoplasmic expression (Figure 1).

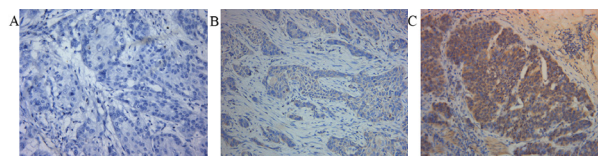


Figure 1A. Immunohistochemical Staining of RUNX3 in ESCC Tissue. A. RUNX3 negative expression in ESCC tissue; B. RUNX3 cytoplasmic expression in ESCC tissue; C. RUNX3 nuclei expression in ESCC tissue. (original magnification =200)

Table 1A. Clinical Data of 143 Patients Undergoing Ivor-Lewis Esophagectomy

Clinical characteristics	Control group patients (n=91)	Chemotherapy group patients (n=52)	pValue
Gender			0.258
Male	66	33	
Female	25	19	
Age(years)			0.312
\geq 50	70	36	
<50	21	16	
Length of tumor (cm)			0.141
<3	23	8	
3~5	31	26	
>5	37	18	
T-status			0.06
T2	38	30	
T3	53	22	
Differentiation			0.37
Well or Moderate	66	34	
Poor	25	18	
RUNX3 expression			0.068
positive	58	25	
negative	33	27	

Table 1B. Results of Cox Regression Analysis of Prognostic Factors

Risk factor	B	SE	Wald	pValue	RR	95 %CI
age	-0.118	0.254	0.217	0.641	0.888	0.540-1.461
gender	0.296	0.251	1.394	0.238	1.344	0.823-2.196
size	0.052	0.149	0.122	0.727	1.054	0.786-1.412
T-status	1.145	0.243	22.11	0	3.142	1.949-5.062
Differentiation	-0.001	0.242	0	0.996	0.999	0.621-1.606
TP therapy	-0.239	0.236	1.028	0.311	0.788	0.496-1.250
RUNX3 expression	0.487	0.229	4.532	0.033	1.628	1.039-2.550

Table 2A. Clinicopathological Factors in RUNX3 Negative Patients (n=60)

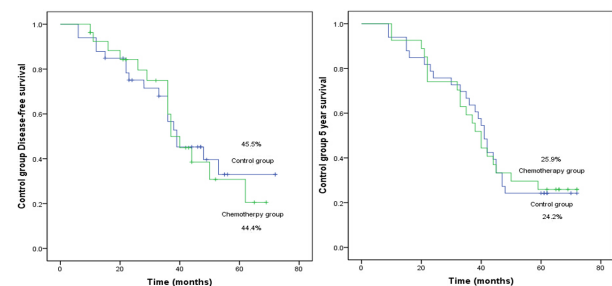
Clinical characteristics	Control group patients (n=33)	Chemotherapy group patients (n=27)	pValue
Gender			0.955
Male	23	19	
Female	10	8	
Age(years)			0.697
≥50	27	21	
<50	6	6	
Length of tumor (cm)			0.59
<3	5	2	
3~5	14	14	
>5	14	11	
T-status			0.137
T2	12	15	
T3	21	12	
Differentiation			0.466
Well or Moderate	19	13	
Poor	14	14	

Chemotherapy efficacy

The disease-free survival was 38.5% in the Control group (35/91) and 53.8% (28/52) in the Chemotherapy group, with no statistically significant difference ($P=0.099$), the overall 5 year survival was 34.1% (31/91) in the Control group and 46.2% (24/52) in the Chemotherapy group, also without a statistically significant difference ($P=0.109$) (Figure 1B). By Cox regression multivariate analyses, the T-status ($P<0.01$), RUNX3 expression ($P<0.05$) were identified as prognostic factors in all the patients (Table 1B). In RUNX3 negative subgroups ($n=60$), no significant difference was observed in disease-free survival ($P=0.870$) and the 5 year survival ($P=0.992$) between the Control and Chemotherapy groups (Figure. 2B). By Cox regression multivariate analyses, only T-status ($P<0.01$) was identified as prognostic factors in all the patients (Table 2B). On the other hand, in RUNX3 positive subgroups ($n=83$), the disease-free survival was 34.5% in the Control group (20/58) and 64.0% (16/25) in the Chemotherapy group,

Table 2B. Results of Cox Regression Analysis of Prognostic Factors in RUNX3 Negative Patients(n=60)

Risk factor	B	SE	Wald	pValue	RR	95 %CI
age	0.465	0.454	1.047	0.306	1.592	0.653-3.878
gender	-0.22	0.361	0.372	0.542	0.802	0.395-1.629
size	0.129	0.246	0.276	0.599	1.138	0.703-1.841
T-status	0.955	0.342	7.784	0.005	2.599	1.329-5.084
Differentiation	0.109	0.303	0.129	0.72	1.115	0.615-2.020
TP therapy	0.081	0.322	0.063	0.802	1.084	0.577-2.037

**Figure 2. Disease-Free Survival and 5 Year Survival in RUNX3 Negative Patients.** Cumulative survival rates in the Control group (no postoperative adjuvant therapy) and Chemotherapy group (postoperative TP therapy)**Table 3A. Clinicopathological Factors in RUNX3 Positive Patients (n=83)**

Clinical characteristics	Control group patients (n=58)	Chemotherapy group patients (n=25)	pValue
Gender			0.102
Male	43	14	
Female	15	11	
Age(years)			0.198
≥50	43	15	
<50	15	10	
Length of tumor (cm)			0.259
<3	18	6	
3~5	17	12	
>5	23	7	
T-status			0.205
T2	26	15	
T3	32	10	
Differentiation			0.747
Well or Moderate	47	21	
Poor	11	4	

with statistically significant difference ($P=0.021$). And the survival was 39.7% (23/58) in the Control group and 68.0% (17/25) in the Chemotherapy group, with a significantly better prognosis in the Chemotherapy group ($P=0.011$) (Figure 3B). By Cox regression multivariate analyses, the T-status ($P<0.01$), TP therapy ($P<0.05$) were identified as prognostic factors in all the patients (Table 3B).

Table 3B. Results of Cox Regression Analysis of Prognostic Factors in RUNX3 Positive Patients(n=83).

Risk factor	B	SE	Wald	pValue	RR	95 %CI
age	-0.565	0.354	2.548	0.11	0.568	0.284-1.138
gender	0.657	0.373	3.109	0.078	1.929	0.929-4.004
size	-0.172	0.202	0.72	0.396	0.842	0.566-1.252
T-status	1.306	0.369	12.546	0	3.692	1.792-7.606
Differentiation	-0.191	0.397	0.231	0.631	0.826	0.379-1.799
TP therapy	-0.923	0.411	5.04	0.025	0.397	0.177-0.889

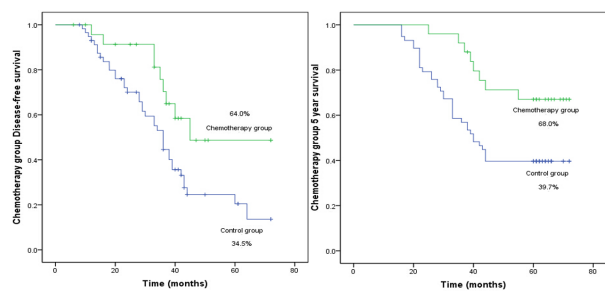


Figure 3. Disease-Free Survival and 5 Year Survival in RUNX3 Positive Patients. Cumulative survival rates in the Control group (no postoperative adjuvant therapy) and Chemotherapy group (postoperative TP therapy)

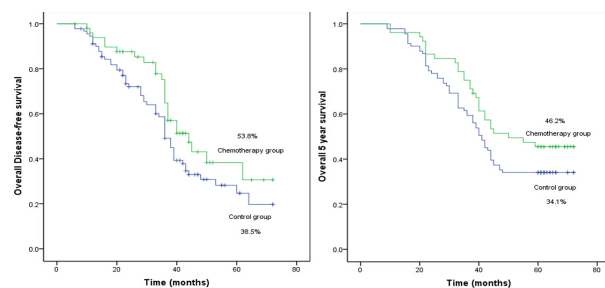


Figure 1B. Disease-Free Survival and Overall 5 Year Survival in All Patients. Cumulative survival rates in the Control group (no postoperative adjuvant therapy) and Chemotherapy group (postoperative TP therapy)

Discussion

Surgical resection with three-field lymph node dissection is the international standard treatment for many stage IIA thoracic esophageal cancer and certain results have been achieved, but the effect of the surgery alone is not satisfactory: the postoperative 5 year survival rate is only 30-50% (Lau et al., 2006). There are some surely therapeutic effects for postoperative adjuvant chemotherapy cisplatin combine with paclitaxel (TP therapy) on ESCC patients with lymph node involvement or metastases, such as stage III (Song et al., 2014), and it was confirmed that TP therapy can improve 5 year survival rate in advanced tumors (Ozcelik et al., 2010). TP therapy has been applied widely as the first-line drug of ESCC adjuvant chemotherapy, and is currently recommended as standard therapy (Raspagliesi et al., 2014). But the adjuvant chemotherapy has not been

demonstrated to take advantage in early stage of ESCC, especially stage IIA disease (tumors extending through the muscularis propria or adventitia, but without lymph node involvement or metastases), and the Current National Comprehensive Cancer Network (NCCN) of esophageal cancer guidelines suggests patients not to be received adjuvant therapy after tumor complete resection (Tadasuke et al., 2014). For patients with stage IIA esophageal cancer, the use of adjuvant chemotherapy remains controversial, many tumors with similar histopathologic features show significantly different clinical outcomes, it may be appropriate in a subset of individuals at high risk for disease recurrence. Therefore, making the identification of molecular prognostic markers to supplement conventional pathologic staging is desirable. The significance of detecting a reasonable molecule as novel biomarker has already been emphasized.

In recent years, many tumor biology studies have led to the discovery of new and potentially useful molecular markers associated with efficacy of chemotherapy and prognosis of esophageal cancer, the identification of accurate and validated predictive and prognostic markers will help guide the clinician in making informed decisions regarding the appropriate use of adjuvant chemotherapy in patients with stage IIA ESCC, it may help to define better those high risk groups who stand to benefit from adjuvant chemotherapy (Tonomoto et al., 2007).

RUNX3 is a target gene of TGF- β -mediated tumor suppressor pathway. Given the potential role of RUNX3 in TGF- β signaling, it is possible that the tumor suppressor activity of RUNX3 is realized by regulating cell migration and invasion (Ito et al., 2005). More and more studies during recent years discovered that RUNX3 inactivation is a crucial factor to determine cancer pathogenesis and clinical outcome in a variety of cancer types, such as gastric, colonic, prostate, breast, lung and bladder cancers (Araki et al., 2005; Suzuki et al., 2005; Ogino et al., 2007; Jiang et al., 2008; Hsu et al., 2009; Wongpaiboonwattana W et al., 2013). It was also reported in esophageal cancer (Sugiura et al., 2008). Much is known about the expression of RUNX3 in esophageal cancer, but less is known about the relationship between RUNX3 expression, chemotherapeutic effect and the prognosis of patients. Previous studies have shown that RUNX3 hypermethylation is related with the cisplatin tolerance of ESCC cells (Cho et al., 2014). After treated with the Methods 5-azacytidine (5-aza), restoring the expression of RUNX3 can enhance bladder cancer cells apoptosis, and the cytotoxic effect of cisplatin on bladder cancer cells was increased *in vitro* (Yan et al., 2012). The results showed that the RUNX3 plays a role in the development resistance to cisplatin of bladder cancer. In gastric cancer, paclitaxel can induce RUNX3 expression, the mechanism of paclitaxel may be related with the increasing of RUNX3 expression (Miyagawa et al., 2006).

No significant difference was observed in disease-free survival and the overall 5 year survival between the Control and Chemotherapy groups when considering the entire patient sample, which the previous study. Various clinicopathological factors were analyzed for the survival of Stage IIA esophageal cancer. Traditional

clinical indicators T-status attempting to stratify stage IIA esophageal cancer patients as high risk factor in identifying patients which were more likely to benefit from adjuvant chemotherapy. RUNX3 expression in Stage IIA esophageal cancer was also found to be significantly associated with poor prognosis factors, such as T-status. These results fit nicely with the previous studies, which revealed that the low expression of RUNX3 in primary gastric cancer was associated with a significantly shorter survival (Gao et al., 2010).

There were 83 RUNX3 positive cases and 60 RUNX3 negative cases are summarized in this research, respectively. In the RUNX3 positive cases, the treatment outcomes regarding have a significant difference of the disease-free survival and overall 5 year survival between the Control and Chemotherapy group was only observed in RUNX3 positive cases. Therefore, postoperative adjuvant therapy with Chemotherapy was shown to be beneficial in RUNX3 positive cases.

In conclusion, a loss or substantial decrease of RUNX3 expression was observed in part of stage IIA patients, and expression of RUNX3 was significantly associated with effectiveness of chemotherapy. This study concluded that postoperative adjuvant chemotherapy is useful for stage IIA RUNX3 positive ESCC patients, RUNX3 could be used as a potential molecular postoperative chemotherapy marker for early stage esophageal cancer.

References

- Ando N, Iizuka T, Ide H, et al (2003). Surgery plus chemotherapy compared with surgery alone for localized squamous cell carcinoma of the thoracic esophagus: a japan clinical oncology group study. *J Clin Oncol*, **21**, 4592-6.
- Araki K, Osaki M, Nagahama Y, et al (2005). Expression of RUNX3 protein in human lung adenocarcinoma: implications for tumor progression and prognosis. *Cancer Sci*, **96**, 227-31.
- Cho, M, Choi, E, Kim, J. H, et al (2014). Lactam-Based HDAC Inhibitors for Anticancer Chemotherapy: Restoration of RUNX3 by Posttranslational Modification and Epigenetic Control. *Chem Med Chem*, **9**, 649-56.
- Fang WT, Chen WH (2009). Current trends in extended lymph node dissection for esophageal carcinom. *Asian Cardiovasc Thorac Ann*, **17**, 208-13.
- Gao J, Chen Y, Wu KC, et al (2010). RUNX3 directly interacts with intracellular domain of Notch1 and suppresses Notch signaling in hepatocellular carcinoma cells. *Exp Cell Res*, **316**, 149-57.
- Hiramatsu T, Osaki M, Ito Y, et al (2005). Expression of RUNX3 protein in human esophageal mucosa and squamous cell carcinoma. *Pathobiol*, **72**, 316-24.
- Hsu PI, Hsieh HL, Lee J, et al (2009). Loss of RUNX3 expression correlates with differentiation, nodal metastasis, and poor prognosis of gastric cancer. *Ann Surg Oncol*, **6**, 1686-94.
- Ito K, Liu Q, Salto-Tellez M, et al (2005). RUNX3, a novel tumor suppressor, is frequently inactivated in gastric cancer by protein mislocalization. *Cancer Res*, **65**, 7743-50.
- Jiang Y, Tong D, Lou G, et al (2008). Expression of RUNX3 gene, methylation status and clinicopathological significance in breast cancer and breast cancer cell lines. *Pathobiol*, **75**, 244-51.
- Lau QC, Raja E, Salto-Tellez M, et al (2006). RUNX3 is frequently inactivated by dual mechanisms of protein mislocalization and promoter hypermethylation in breast cancer. *Cancer Res*, **66**, 6512-20.
- Leonard GD, Reilly EM (2004). Post-operative chemotherapy improves disease-free survival, but not overall survival in people with oesophageal squamous cell carcinoma. *Cancer Treat Rev*, **30**, 473-7.
- Lu YF, Liu ZC, Li ZH, et al (2014). Esophageal/gastric cancer screening in high-risk populations in Henan Province, China. *Asian Pac J Cancer Prev*, **15**, 1419-22.
- Mariette C, Piessen G, Triboulet JP (2007). Therapeutic strategies in oesophageal carcinoma: role of surgery and other modalities. *Lancet Oncol*, **8**, 545-53.
- Mirinezhad SK, Jangjoo AG, Seyednejad F, et al (2014). Impact of tumor length on survival for patients with resected esophageal cancer. *Asian Pac J Cancer Prev*, **15**, 691-4.
- Miyagawa K, Sakakura C, Nakashima S, et al (2006). Down-regulation of RUNX1, RUNX3 and CBF-beta in hepatocellular carcinomas in an early stage of hepatocarcinogenesis. *Anticancer Res*, **26**, 3633-43.
- Ogino S, Meyerhardt JA, Kawasaki T, et al (2007). CpG island methylation, response to combination chemotherapy, and patient survival in advanced microsatellite stable colorectal carcinoma. *Virchows Arch*, **450**, 529-37.
- Ozcelik B, Turkyilmaz C, Ozgun MT, et al (2010). Prevention of paclitaxel and cisplatin induced ovarian damage in rats by a gonadotropin-releasing hormone agonist. *Fertility Sterility*, **93**, 1609-14.
- Raspagliesi F, Zanaboni F, Martinelli F, et al (2014). Role of paclitaxel and cisplatin as the neoadjuvant treatment for locally advanced squamous cell carcinoma of the vulva. *J Gynecol Oncol*, **25**, 22-9.
- Song W, Tang Z, Li M, et al (2014). Polypeptide-based combination of paclitaxel and cisplatin for enhanced chemotherapy efficacy and reduced side-effects. *Acta Biomaterialia*, **10**, 1392-402.
- Sugiura H, Ishiguro H, Kuwabara Y, et al (2008). Decreased expression of RUNX3 is correlated with tumor progression and poor prognosis in patients with esophageal squamous cell carcinoma. *Oncol Rep*, **19**, 713-9.
- Suzuki M, Shigematsu H, Shames DS, et al (2005). DNA methylation associated inactivation of TGF beta-related genes DRM/Gremlin, RUNX3, and HPP1 in human cancers. *Br J Cancer*, **93**, 1029-37.
- Tadasuke Hashiguchi, Motomi Nasu, Takashi hashimoto, et al (2014). Docetaxel, cisplatin and 5-fluorouracil adjuvant chemotherapy following three-field lymph node dissection for stage II/III N1, 2 esophageal cancer. *Molecular Clin Oncol*, **2**, 719-24.
- Tonomoto Y, Tachibana M, Dhar D.K, et al (2007). Differential expression of RUNX genes in human esophageal squamous cell carcinoma: downregulation of RUNX3 worsens patient prognosis. *Oncol*, **73**, 346-56.
- Wongpaiboonwattana W, Tosukh Wong P, Dissayabuttra T, et al (2013). Oxidative stress induces hypomethylation of LINE-1 and hypermethylation of the RUNX3 promoter in a bladder cancer cell line. *Asian Pac J Cancer Prev*, **14**, 3773-8.
- Yan C, Kim YW, Ha YS, et al (2012). RUNX3 methylation as a predictor for disease progression in patients with non-muscle-invasive bladder cancer. *J Surg Oncol*, **105**, 425-30.