

## RESEARCH ARTICLE

# Value of the Platelet to Lymphocyte Ratio in the Diagnosis of Ovarian Neoplasms in Adolescents

Gulnur Ozaksit, Aytekin Tokmak\*, Hatice Kalkan, Huseyin Yesilyurt

### Abstract

**Background:** Relationships between poor prognosis of ovarian malignancies and changes in complete blood count parameters have been proposed previously. In this work, we aimed to evaluate clinicopathologic features in adolescents with adnexal masses and sought to establish any predictive value of the platelet to lymphocyte ratio (PLR) in diagnosis. **Materials and Methods:** This retrospective study was conducted on 196 adolescent females with adnexal masses. Three groups were constituted with respect to clinical or histopathology results: group 1, non-neoplastic patients (n:65); group 2, neoplastic patients (n:68); and group 3 expectantly managed patients (n:63). The main parameters recorded from the hospital database and patient files were age, body mass index (BMI), chief symptoms, diameter of the mass (DOM), tumor marker levels, complete blood count values including absolute neutrophil, lymphocyte, and platelet counts, mean platelet volume, platelet distribution width, and platecrit, surgical features, and postoperative histopathology results. **Results:** The expectantly managed patients were younger than the other groups ( $p=0.007$ ). The mean body mass index (BMI) was higher in the neoplastic group ( $p=0.016$ ). Preoperative DOM, CA125, mean platelet volume and PLR were statistically significantly different between the groups ( $p<0.05$ ). ROC curve analysis demonstrated that increased PLR (AUC, 0.609;  $p=0.011$ ) and BMI (AUC, 0.611;  $p=0.011$ ) may be discriminative factors in predicting ovarian neoplasms in adolescents preoperatively. When the cut-off point for the PLR level was set to 140, the sensitivity and specificity levels were found to be 65.7% and 57.6%, respectively. **Conclusions:** We suggest that beside a careful preoperative evaluation including clinical characteristics, ultrasonographic features and tumor markers, PLR may predict ovarian neoplasms in adolescents.

**Keywords:** Adolescents - females - ovarian neoplasms - platelet to lymphocyte ratio - diagnostic potential

*Asian Pac J Cancer Prev*, 16 (5), 2037-2041

### Introduction

The exact prevalence of adnexal masses in adolescents is unknown, but they are relatively uncommon in this population. Adnexal masses can arise from the ovaries and other pelvic structures, and they are the most common indication for gynecologic surgery in adolescents. The differential diagnosis includes ovarian masses, tubal pathologies, uterovaginal anomalies, and other reasons such as gastrointestinal and urinary system disorders. Ovarian masses classified as non-neoplastic and neoplastic are the most common cause of adnexal masses. Functional cysts, ovarian torsion, and benign neoplasms are the most common ovarian masses in young adolescents (Liu et al., 2013). Ovarian neoplasms are estimated to occur at a rate of approximately 2.6 in 100,000 girls per year (Ki et al., 2013) and malignant ovarian tumors in children and adolescents are rare, accounting for 0.9% of all malignancies (Deligeoroglou et al., 2004). Most ovarian masses are non-neoplastic or benign neoplasms; fewer than 10 percent of ovarian malignancies occur in this age

group (Zhang et al., 2014). In a review of females under the age of 21 undergoing surgery for an adnexal mass, 57.9% of the cases were diagnosed with an ovarian cyst (Templeman et al., 2000).

Adolescents with adnexal masses usually present with abdominal pain which was followed by nausea and vomiting, abdominal distention, palpable abdominal or pelvic masses, and endocrine manifestations such as abnormal uterine bleeding, amenorrhea, or virilization. A carefully obtained history and physical examination are essential in the differential diagnosis. The characteristic of pain, menstrual cycle regularity, and sexual activity should be questioned. The pelvic examination is usually impossible due to virginity or severe pain in this population. Therefore, ultrasonography is the preferred imaging modality for ovarian cyst diagnosis. CT and MRI are usually reserved for difficult cases. Morphologic scoring systems to assess malignant potential may be used (Arab et al., 2014), but they have not been validated in adolescents. A complete blood count (CBC), quantitative human chorionic gonadotropin (HCG) test, and tumor

markers panel should be obtained, as indicated, based upon clinical assessment.

Management of adolescent adnexal masses is done by considering individual patient characteristics and varies between surgical management and expectant or medical management. The definitive diagnosis of an ovarian mass is typically determined by surgical and histological means. Laparoscopic surgery is the accepted gold standard for management of adnexal masses. Indeed, benign ovarian neoplasms are treated via laparotomy by many gynecologists and pediatric surgeons, a gynecologic oncologist should be involved when imaging suggests a malignancy.

Recently certain blood cells or inflammatory markers were studied in the diagnosis and prognosis of different malignancies (Acmaç et al., 2014; Kemal et al., 2014). The platelet to lymphocyte ratio (PLR) is a simple blood test associated with poor prognosis when elevated in patients suffering from various oncologic disorders. An elevated PLR was also reported in ovarian epithelial tumors associated with poor prognosis (Kokcu et al., 2014). The relationship of poor prognosis and the elevation of white blood cells, platelets, or their ratio have been tried to be explained through an inflammatory process elicited by neoplastic cells. It was suggested that an inflammatory process including blood cells, cytokines, damaged cell components initiate angiogenesis around the neoplastic area (Raungkaewmanee et al., 2012). Similarly, platelets may release some growth factors which function as a potent mitogen for different cell types including ovarian surface epithelium. And these growth factors may stimulate ovarian tumor cells proliferation.

In this study we aimed to evaluate the predictive value of the PLR which is a simply applicable blood test in the diagnosis of ovarian neoplasm in adolescents to prevent unnecessary surgical interventions.

## Materials and Methods

After an ethical approval for the entire study was obtained from the local Ethics Committee of the Institution, we researched the archive of our Infertility and Gynecologic Oncology Departments to identify adolescents with adnexal mass aged between 10-21 years old and managed in our hospital between January 2010 and December 2013. Our hospital is a tertiary referral research and education hospital located in the capital city of Turkey, Ankara. Due to the retrospective design of our study, informed consent was not obtained. A total of two hundred and forty two adolescent females with adnexal mass were identified from the hospital records. Forty patients, who had incomplete laboratory data particularly preoperative complete blood count values and operative notes, had no available medical records or surgico-pathological reports were excluded from the study. We also excluded the six patients with ectopic pregnancy. The study included a total of 196 adolescent females with adnexal mass managed at our infertility and gynecological oncology departments during the study period. Three groups were constituted with respect to clinic or histopathologic results. The patients were treated

surgically in both groups 1 and 2. Group 1 consisted of non-neoplastic patients (n:65), patients with neoplastic ovarian masses constituted group 2 (n:68), and expectantly managed patients (n:63) were included in group 3. The data of the cases were collected from hospital database and patient files. The clinical and laboratory characteristics evaluated were age, BMI, gravidity, parity, number of abortion, chief symptom, virginity and smoking status, comorbidities, previous abdominal surgery, the longest diameter of the mass (DOM) detected on preoperative ultrasound imaging, preoperative tumor markers panel, and complete blood count values, surgical features, and postoperative histopathology result of the operation specimens.

A careful physical and pelvic examination was performed to all patients after the initial evaluation that included a gynecological and general history. For all patients ultrasound scan was performed by expert radiologists and/or gynecologists of our institution. Hematology parameters were investigated using the Coulter LH-780 hematology blood analyzer (Beckman Coulter Inc., Brea, CA, USA). These parameters were hemoglobin, absolute neutrophil and lymphocyte count, platelet count, mean platelet volume (MPV), platecrit (PCT), red cell distribution width (RDW), platelet distribution width (PDW). We also calculated neutrophil to lymphocyte ratio (NLR), and PLR. NLR was defined as the absolute neutrophil count divided by the absolute lymphocyte count. PLR was defined as the absolute platelet count divided by the absolute lymphocyte count. Tumor markers including alpha-feto protein (AFP), CA125, CA19.9, CA15.3, carcinoembryonic antigen (CEA) were measured using commercially available immunoassay kits (Immulite 2000 Immunoassay System by Siemens).

Management decision was made according to physical examination, ultrasound findings, and laboratory parameters. If the cyst did not resolve or decrease in size after 2-3 months, caused severe symptoms such as acute abdomen, suspected hemorrhage, torsion, and malignancy, or greater than 8-10 cm surgical intervention was made. If the patient's complaints resolved during the clinical observation or aforementioned findings did not exist, she managed expectantly. Laparoscopy was the preferred procedure as also considering each patient's individual characteristic in the surgical management. Also cystectomy, fenestration or aspiration of the cyst with the removal of the cyst wall was the preferred methods for the benign cysts. Frozen section was performed in suspicious of malignancy, and oophorectomy was performed in case of malignancy. Histopathology results of all patients were recorded postoperatively.

### Statistics

Means and standard deviations (SD) were calculated for continuous variables. Subject characteristics and demographics were analyzed descriptively. The normal distribution of the variables was analyzed by the Kolmogorov-Smirnov test. The Kruskal-Wallis test was used to test the null hypothesis between groups. The Chi-square ( $X^2$ ) test and the one-way ANOVA were

used to evaluate associations between the categorical and continuous variables. ROC curve analysis was used to assess the discriminative role of PLR. Two-sided P values were considered statistically significant at  $p < 0.05$ . Statistical analyses were carried out using the statistical package SPSS 15.0 for Windows (SPSS Inc., Chicago, IL, USA).

## Results

A total of 196 adolescent females with adnexal masses were included in the current study. Sixty five patients with non-neoplastic masses were classified as group 1, 68 patients with neoplastic masses classified as group 2, and group 3 were consisted of 63 expectantly managed patients. Table 1 depicted the demographic and clinical parameters between the groups. The mean age of the patients was  $17.7 \pm 2.2$  and ranged from 10 to 21. There were statistically significant differences among the three groups in terms of age ( $p = 0.007$ ). The mean BMI and DOM was  $22.3 \pm 3.9$  kg/m<sup>2</sup>,  $6.8 \pm 3.4$  cm, respectively, and the differences between groups in term of these parameters were statistically significant ( $p < 0.05$ ). Serum levels of CA125, MPV, and PLR were also significantly different parameters between the groups ( $p < 0.05$ ) (Table 2).

The ovaries were the most common source of the masses in all groups. There was a right sided dominance among the ovarian masses (56.6% vs 32.1%). Laparoscopy had been preferred method for the surgical treatment (72.2% vs 27.8%). Ovarian masses were treated with cystectomy or aspiration in the majority of patients. 88 patients were treated with cystectomy, 30 patients were treated with aspiration and fenestration, and 12 patients underwent ooforectomy. Abdominal pain was the most common clinical manifestation in adolescents with an adnexal mass. The most common non-neoplastic lesions were endometrioma and functional cyst (hemorrhagic cyst, follicle cyst, corpus luteum cyst) in group 1, while mature cystic teratoma (MCT) was the most common neoplastic lesion in group 2. Histopathology results are shown in Table 3.

ROC curve analysis demonstrated that increased PLR (AUC, 0.609; 95% CI: 0.526-0.693;  $p = 0.011$ ) and BMI (AUC, 0.611; 95% CI: 0.529-0.693;  $p = 0.011$ ) are the

**Table 1. Comparison of the Demographic and Clinical Parameters Among the Groups**

Variables	Group 1 (n:65)	Group 2 (n:68)	Group 3 (n:63)	p value
Age (years)	$18.1 \pm 2.1$	$18.0 \pm 2.0$	$17.0 \pm 2.2$	0.007
Gravidity	0 (0-1)	0 (0-1)	0 (0-1)	0.789
Parity	0 (0-1)	0 (0-1)	0	0.260
Abortion	0	0 (0-1)	0 (0-1)	0.448
Weight (kg)	$58.0 \pm 13.0$	$59.9 \pm 9.6$	$54.4 \pm 8.8$	0.015
BMI (kg/m <sup>2</sup> )	$22.5 \pm 4.5$	$22.9 \pm 3.7$	$21.0 \pm 3.1$	0.016
DOM(cm)	$7.3 \pm 3.1$	$7.7 \pm 3.2$	$4.6 \pm 2.1$	<0.001
Smoking	4 (6.2%)	7 (10.4%)	9 (14.3)	0.317
Virgino	51 (78.5%)	58 (85.3%)	55 (87.3%)	0.364

\*BMI, body mass index; DOM, diameter of the mass; Data are presented as mean  $\pm$  standard deviation, median (minimum-maximum), and n (%);  $p < 0.05$  is considered statistically significant

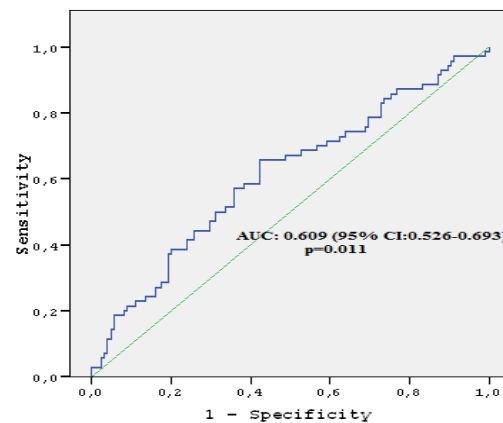
**Table 2. Comparison of the Laboratory Parameters Among the Groups**

Variables	Group 1 (n:65)	Group 2 (n:68)	Group 3 (n:63)	p value
AFP*	$1.5 \pm 1.6$	$1.3 \pm 1.3$	$1.3 \pm 1.7$	0.744
CA125*	$22.2 \pm 29.4$	$15.2 \pm 8.5$	$12.5 \pm 14.1$	<0.001
CA15.3	$12.5 \pm 5.9$	$11.7 \pm 5.6$	$10.7 \pm 5.1$	0.181
CA19.9*	$15.6 \pm 26.2$	$16.3 \pm 23.9$	$15.1 \pm 17.6$	0.903
CEA*	$0.5 \pm 0.7$	$0.5 \pm 0.7$	$0.3 \pm 0.5$	0.268
HGB	$12.9 \pm 1.4$	$12.6 \pm 1.4$	$12.5 \pm 1.7$	0.159
Neutrophil	$5.0 \pm 2.3$	$5.7 \pm 3.3$	$5.7 \pm 2.2$	0.192
Lymphocyte	$2.1 \pm 0.5$	$1.9 \pm 0.6$	$2.0 \pm 0.9$	0.265
NLR	$2.6 \pm 1.9$	$3.9 \pm 4.7$	$3.4 \pm 2.5$	0.057
PLT	$270.1 \pm 67.9$	$296.5 \pm 76.9$	$276.5 \pm 70.7$	0.091
MPV	$10.1 \pm 1.2$	$9.5 \pm 1.1$	$9.8 \pm 1.2$	0.034
PDW	$14.9 \pm 2.2$	$14.5 \pm 2.2$	$14.7 \pm 2.3$	0.491
PCT	$0.26 \pm 0.6$	$0.27 \pm 0.7$	$0.27 \pm 0.6$	0.525
RDW	$13.4 \pm 1.3$	$13.7 \pm 1.5$	$13.8 \pm 1.5$	0.167
PLR	$130.4 \pm 39.4$	$175.7 \pm 103.3$	$156.9 \pm 79.3$	0.004

Data are presented as mean  $\pm$  standard deviation, and median  $\pm$  interquartile range\*;  $P < 0.05$  is considered statistically significant

**Table 3. Histopathology Results for the Masses**

Group 1 (n:65)	n	Group 2 (n:68)	n
Functional cyst	24	Dermoid cyst	30
Endometrioma	20	Serous cystadenom	16
Serous cyst	8	Mucinous cystadenom	8
Paratubal	3	Ovarian stromal tumor	4
Mucinous cyst	2	Sertoli-Leydig cell tumor	3
Abscess	2	Borderline serous tumor	2
Torsion	2	Immature teratoma	1
Rudimentary horn	1	Dysgerminoma	1
Hematometra	1	Mixed germ cell tumor	1
Peritoneal cyst	1	Granulosa cell tumor	1
Tuberculosis	1	Fibroma	1



**Figure 1. ROC Curve Analysis for PLR in Prediction of Adolescent Ovarian Neoplasms**

statistically significant discriminative factors in predicting ovarian neoplasm in adolescents preoperatively. When the cut-off point for the PLR level was set to 140, the sensitivity and specificity levels were found to be 65.7% and 57.6%, respectively (Figure 1).

## Discussion

Adnexal masses are relatively uncommon in adolescent females. It is sometimes difficult to distinguish the

neoplastic masses from the non-neoplastic ones. Herein, we designed a retrospective study of adolescents with adnexal masses who were managed at our clinic. At first the patients were divided into surgically and expectantly managed groups, then surgically managed cases were classified as non neoplastic and neoplastic groups according to histopathology reports. The main finding of our study performed in adolescents with adnexal masses was that PLR may predict ovarian neoplasm without distinction of benign or malignant.

Adnexal masses constituted by approximately one third of ovarian tumors may originate from the different pelvic structures. The malignant cases constitute a very small number of the adolescent patients (Hassan et al., 1999). The most common presenting symptom is abdominal pain in adolescents with adnexal masses (Deligeoroglou et al., 2004). A smaller part of patients has no symptoms or complains of having irregular menstrual cycles. In our study, the most common presenting symptom was abdominal pain which is consistent with the literature.

Ovarian torsion is a rare problem that must be considered in the differential diagnosis of any adolescent patient presenting with abdominal pain or an adnexal mass. Anish and colleagues suggested that polycystic ovary syndrome (PCOS) may be an underlying cause of unexplained ovarian torsion (Shah et al., 2009). Early diagnosis allows for conservative treatment in adolescents whom desire future fertility. Emergency ultrasound is an important diagnostic tool, but a definitive diagnosis could be made only by surgery (Rousseau et al., 2009). In our study there was two case of unexplained ovarian torsion; and there was an evidence of PCOS in both cases.

The gold standard for diagnosing ovarian masses is ultrasound. Malignant tumors may have certain sonographic features, but a validated scoring system is not present for adolescents. In this study, a portion of the patient records did not contain detailed ultrasound data. Therefore, patients could not be evaluated with regard to ultrasonographic features. Tumor markers can be helpful in the diagnosis of ovarian tumors in adolescents. AFP and CA125 are the most useful tumor markers for distinguishing patients with malignant tumor in preadolescent and adolescent females. A high level AFP level in a preadolescent girl with an adnexal mass can be indicative of an ovarian malignancy (Liu et al., 2013). However, CA125 has a limited utility for surgical exploration of persistent masses in this population (McCarthy et al., 2009). In our study, CA125 was frequently increased in patients with endometriomas, abnormal CA19.9 levels were found in patients with cystic ovarian teratomas, and an extremely high serum AFP level was detected in a patient with mixed germ cell tumor. These findings were consistent with the current literature. But also, there were some cases which did not comply with this generalization, for instance, we detected a highly elevated CA19.9 level in a patient with hematometra and elevated AFP level in a patient with Sertoli-Leydig cell tumor, or an elevated CA125 level was detected in a patient with paratubal cyst.

The true incidence of pediatric malignant ovarian tumors is unknown. Lui et al. (2013) reported that

13.6% of ovarian masses were malignant or borderline in children and adolescents aged between 2 to 18 years. Deligeoroglou et al. (2004) evaluated 44 patients with ovarian masses, aged between 12-21 years, 49% of them were non neoplastic and 51% were neoplastic. Of the neoplastic tumors, 95.8% were benign while 4.2% were malignant in his study. In the present study, malignant ovarian masses consisted of 2.5% of all masses and 51.1% of the masses were neoplastic whereas 48.9% were non-neoplastic in adolescent who managed surgically. Of the neoplastic tumors 6.1% (9/68) were malignant and 76.4% of neoplastic masses occurred in patients aged between 16 and 20 years. Mature cystic teratom and serous cystadenoma were the most common neoplastic tumors. Sex cord stromal tumors and germ cell tumors were the most common malignant ovarian tumors in our cohort of patients. Our results were more consistent with Deligeoroglou's results due to close patient groups. The difference between the results could be explained by different study populations.

Laparoscopy is the preferred surgery for treatment of adnexal masses in adolescents due to minimized adhesion formation, decreased blood loss and days of hospitalization. Performance of laparoscopy as minimally invasive surgery can be useful for both diagnosis and treatment. Mayer and colleagues previously suggested that laparoscopy is associated with satisfactory outcomes and few complications (Mayer et al., 2009). We also generally preferred laparoscopy for the surgical treatment and performed cystectomy in the majority of patients.

The predominant cancers associated with obesity have a hormonal base and include breast, prostate, endometrium, colon, and gall bladder neoplasms (Kaur et al., 2005). Olsen et al. (2007) designed a meta-analysis to determine the effect of obesity on ovarian cancer. They reported that a 16% increased risk of ovarian cancer for adult overweight and a 30% increased risk for adult obesity when compared with normal weight. Leitzmann et al. (2009) also suggested that both overweight and obesity at age 18 years positively associated with ovarian cancer. Both authors concluded that adiposity enhances ovarian cancer risk partly through the mitogenic effects of excess endogenous estrogens synthesized in the adipose tissue. We also found that adolescents with neoplastic ovarian tumor had higher BMI than the others.

Complete blood count is one of the main preoperative laboratory evaluations, and it has been recently incorporated into many studies in an attempt to evaluate the prognostic role in epithelial ovarian cancers (Raungkaewmanee et al., 2012). Also of great interest has intensified on blood components including neutrophil, lymphocyte, and platelet counts, and their ratios. Previous studies suggested that elevated platelet count is associated with adverse outcomes in different malignancies. Moreover, it was claimed that the PLR and NLR could be used as a diagnostic marker for certain gynecologic cancers (Yesilyurt et al., 2014; Yildirim et al., 2014). Raungkaewmanee et al. (2012) designed a retrospective study to determine whether preoperative PLR associated with diagnosis and prognosis of epithelial ovarian cancer. They found that a PLR of 200 yielded a good predictive value. In the present study

we aimed to evaluate the predictive value of PLR in the diagnosis of ovarian neoplasm in adolescents. We also evaluated the discriminative value of other blood parameters. However, PLR showed a better function among these blood component indicators. The results of our study were consistent with the previously mentioned study in ovarian cancers which found that PLR appeared to be a poor prognostic factor.

Our study had several limitations. A major limitation was the retrospective nature of data collection. Another limitation was that the heterogeneity of the study population. In fact, it would be better to classify the groups as malignant and benign, but our study group had a limited number of cases with malignancies. But we think that adolescents are a special group of patients and there are limited studies conducted on these patients. To our knowledge this is the first one suggested that a PLR value more than 140 might be a diagnostic marker in adolescents with neoplastic ovarian masses.

In conclusion, we suggest that gynecologists and pediatric surgeons should consider the possibility of ovarian neoplasms in any adolescent female presenting with an abdominal pain regardless of age. We think that beside a careful preoperative evaluation including clinical characteristics, ultrasonographic features, and tumor markers, PLR may predict ovarian neoplasm in adolescents. Larger further studies with more homogeneous populations are needed to validate the predictive value of PLR.

## References

- Acmaz G, Aksoy H, Unal D, et al (2014). Are neutrophil/lymphocyte and platelet/lymphocyte ratios associated with endometrial precancerous and cancerous lesions in patients with abnormal uterine bleeding? *Asian Pac J Cancer Prev*, **15**, 1689-92.
- Arab M, Honarvar Z, Hosseini-Zijoud SM (2014). Ovarian malignancy probability score (OMPS) for appropriate referral of adnexal masses. *Asian Pac J Cancer Prev*, **15**, 8647-50.
- Deligeoroglou E, Eleftheriades M, Shiadoes V, et al (2004). Ovarian masses during adolescence: clinical, ultrasonographic and pathologic findings, serum tumor markers and endocrinological profile. *Gynecol Endocrinol*, **19**, 1-8.
- Hassan E, Creatsas G, Deligeoroglou E, Michalas S (1999). Ovarian tumors during childhood and adolescence. A clinicopathological study. *Eur J Gynaecol Oncol*, **20**, 124-6.
- Kaur T, Zhang ZF (2005). Obesity, breast cancer and the role of adipocytokines. *Asian Pac J Cancer Prev*, **6**, 547-52.
- Kemal Y, Yucel I, Ekiz K, et al (2014). Elevated serum neutrophil to lymphocyte and platelet to lymphocyte ratios could be useful in lung cancer diagnosis. *Asian Pac J Cancer Prev*, **15**, 2651-4.
- Ki EY, Byun SW, Choi YJ, et al (2013). Clinicopathologic review of ovarian masses in Korean premenarchal girls. *Int J Med Sci*, **10**, 10611-7.
- Kokcu A, Kurtoglu E, Celik H, Tosun M, Malatyalioglu E, Ozdemir AZ (2014). May the platelet to lymphocyte ratio be a prognostic factor for epithelial ovarian cancer? *Asian Pac J Cancer Prev*, **15**, 9781-4.
- Leitzmann MF, Koebnick C, Danforth KN, et al (2009). Body mass index and risk of ovarian cancer. *Cancer*, **115**, 812-22.
- Liu H, Wang X, Lu D, Liu Z, Shi G (2013). Ovarian masses in children and adolescents in China: analysis of 203 cases. *J Ovarian Res*, **6**, 47.
- Mayer JP, Bettolli M, Kolberg-Schwerdt A, et al (2009). Laparoscopic approach to ovarian mass in children and adolescents: already a standard in therapy. *J Laparoendosc Adv Surg Tech A*, **1**, 111-5.
- McCarthy JD, Erickson KM, Smith YR, Quint EH (2010). Premenarchal ovarian torsion and elevated CA-125. *J Pediatr Adolesc Gynecol*, **23**, 47-50.
- Olsen CM, Green AC, Whiteman DC, et al (2007). Obesity and the risk of epithelial ovarian cancer: a systematic review and meta-analysis. *Eur J Cancer*, **43**, 690-709.
- Raunkaewmanee S, Tangjitgamol S, Manusirivithaya S, Srijaipracharoen S, Thavaramara T (2012). Platelet to lymphocyte ratio as a prognostic factor for epithelial ovarian cancer. *J Gynecol Oncol*, **23**, 265-73.
- Rousseau V, Massicot R, Darwish AA, et al (2008). Emergency management and conservative surgery of ovarian torsion in children: a report of 40 cases. *J Pediatr Adolesc Gynecol*, **21**, 201-6.
- Shah AA, Likes CE, Price TM (2009). Early polycystic ovary syndrome as a possible etiology of unexplained premenarcheal ovarian torsion. *J Pediatr Adolesc Gynecol*, **22**, 265-9.
- Templeman C, Fallat ME, Blinchevsky A, Hertweck SP (2000). Noninflammatory ovarian masses in girls and young women. *Obstet Gynecol*, **96**, 229-33.
- Yesilyurt H, Tokmak A, Guzel AI, et al (2014). Parameters for predicting granulosa cell tumor of the ovary: a single center retrospective comparative study. *Asian Pac J Cancer Prev*, **15**, 8447-50.
- Yildirim MA, Seckin KD, Togrul C, et al (2014). Roles of neutrophil/lymphocyte and platelet/lymphocyte ratios in the early diagnosis of malignant ovarian masses. *Asian Pac J Cancer Prev*, **15**, 6881-5.
- Zhang M, Jiang W, Li G, Xu C (2014). Ovarian masses in children and adolescents-an analysis of 521 clinical cases. *J Pediatr Adolesc Gynecol*, **27**, 73-7.