

## Orchiectomy in the Asiatic Black Bear (*Ursus thibetanus*)

Dong-Hyuk Jeong<sup>\*†</sup>, Seung-Yong Lee<sup>†</sup>, Jeong-Jin Yang<sup>\*</sup>, Seong-Hoon Seok, Ju-Yeon Kong<sup>\*</sup>, Se-Jin Park, So-Young Jin, Min-Hyang Kim, Bae-Keun Lee<sup>\*</sup>, Hee-Chun Lee<sup>\*\*</sup> and Seong-Chan Yeon<sup>1</sup>

Laboratory of veterinary surgery & behavior, College of Veterinary Medicine, Gyeongsang National University, Jinju 660-701, Republic of Korea

<sup>\*</sup>Species Restoration Technology Institute of Korea National Park Service, Gurye 542-853, Republic of Korea

<sup>\*\*</sup>Laboratory of veterinary medical imaging, College of Veterinary Medicine, Gyeongsang National University, Jinju 660-701, Republic of Korea

(Accepted: June 26, 2015)

**Abstract :** The Asiatic black bear (*Ursus thibetanus*) is globally protected species and involved in a species restoration program by the Korea National Park Service. However, the bears could not be released into the wild were required regulation of population due to the limited space of breeding facility, so surgical castration was performed in two males. Bears were immobilized with a combination of 2 mg/kg tiletamine-zolazepam and 40 µg/kg medetomidine, and general anesthesia was maintained with isoflurane via endotracheal tube intubation. Orchiectomy was carried out by the closed method using the LigaSure vessel sealing device through pre-scrotal incision. Subcutaneous tissues of the incision site were sutured by continuous pattern with absorbable suture material, and the skin incision was closed with tissue glue. The bears recovered uneventfully from general anesthesia after a duration of 58 min (bear A) and 53 min (bear B). Total surgical time was 26 min (bear A) and 24 min (bear B). No postoperative swelling or complications were observed. This is the first report that describes the use of the LigaSure for orchiectomy in the Asiatic black bear.

**Key words :** Asiatic black bear, *Ursus thibetanus*, testicle, orchiectomy, castration, LigaSure.

### Introduction

The Asiatic black bear (*Ursus thibetanus*), known as moon bear and white-chested bear, is classified as “Vulnerable” by the International Union for Conservation of Nature (IUCN), mostly because of poaching and habitat loss (2). This condition is similar in the Republic of Korea. Asiatic black bears inhabited Mt. Jiri forming largest free-living population, even in the early 1980s. However, its free-living population has decreased continuously, and Korea National Park Service has conducted the species restoration program of Asiatic black bear since 2004 yr (9). Since then, they released 34 bears on Mt. Jiri, and achieved birth of cubs through natural mating in the wild (4).

However, some of the released bears had to be withdrawn into captive facility because of their habituation on human. These female and male bears live together on a large area in the facility. As the number of them increased in the limited space, the fights broke out among individuals frequently and some bears mated between kinship. Therefore, regulation of the bear population is required in the facility, and control of their reproductive function is highly desirable. In males, surgical castration is the best choice in captive wildlife because of technical simplicity and efficiency. Castration also decreases male aggressiveness, roaming and androgen-related diseases (3).

This case report describes the orchiectomy for sterilization in the Asiatic black bear by the closed technique using the LigaSure vessel sealing device.

### Case

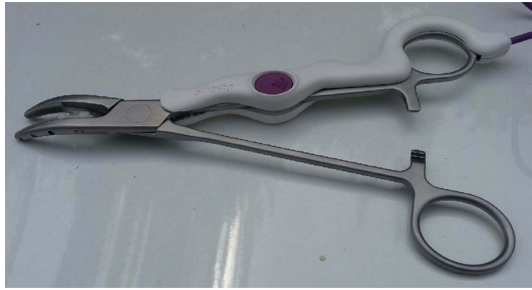Two male Asiatic black bears, excluded from the species restoration program of the Korea National Park Service, were presented for orchiectomy. Bear A was a 138 kg 7-year-old male, and bear B was a 215 kg 13-year-old male.

Food and water were withheld from each bear for 12 h. Bears were immobilized with intramuscular administration of 2 mg/kg tiletamine-zolazepam (Zoletil 50, Virbac, France) and 40 µg/kg of medetomidine (Domitor, Pfizer, USA) combination via remote injection (PICO 2, Daninject, Denmark). The bears were transported to the surgical room and positioned dorsal recumbency on a surgical table. A physical examination was performed and presence of both testicles in the scrotum was verified. An intravenous catheter was placed in the right jugular vein and venous blood samples were collected for CBC and plasma biochemistry analysis. The results were unremarkable. After 8.5 mm endotracheal tube intubation, general anesthesia was maintained with isoflurane (Terrell, Piramal Critical Care Inc., USA) in 100% O<sub>2</sub> (4 L/min) via a circle rebreathing system. Each bear received drug injections of 0.01 mg/kg glycopyrrolate (Mobinul, Myungmoon Pharm. Co., Ltd., Korea) and 0.2 mg/kg meloxicam (Metacam, Boehringer Ingelheim, Germany) subcutaneously. Lactated Ringer's solution (Hartmann's Sol., Daihan Pharm.

<sup>†</sup>These authors contribute equally to this work

<sup>1</sup>Corresponding author.

E-mail : scyeon@gnu.ac.kr



**Fig 1.** The LigaSure max hand switching instrument (LS3090, Covidien, USA) is a reusable vessel sealing instrument and disposable electrode.

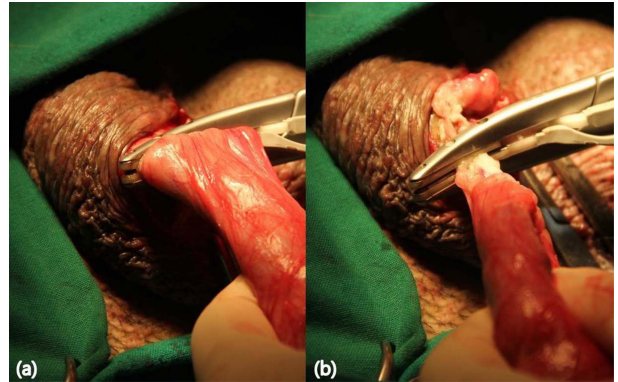
Co., LTD., Korea) was administered via the venous catheter at a rate of 10 ml/kg/h.

Throughout the anesthesia, the bears were monitored continuously by a dedicated monitor (Datex-Ohmeda S/5; GE Healthcare, FIN-00031 GE, UK). The bears breathed spontaneously without aid of mechanical ventilation. Values were recorded every 5 min and all values remained close to baseline parameters.

The operation was carried out with reference to the orchietomy of dogs (3), but modified in the suture technique. The closed method of orchietomy was used by pre-scrotal approach. Skin of the pre-scrotal and scrotal areas was clipped and aseptically prepared. Applied pressure on the scrotum to advance testicles cranially, the pre-scrotal skin and subcutaneous tissue were incised along the median raphe with 4 cm length. The testicle was exposed through external spermatic fascia incision and carefully exteriorized from the scrotum. Applied traction on the testicle, fibrous tissue and fascia were bluntly dissected from the parietal vaginal tunics with the use of sterile gauze to exteriorize the spermatic cord maximally. Then, the LigaSure vessel sealing device (LigaSure Max, Covidien, Ireland) was placed around the entire spermatic cord of 25 mm diameter for tissue fusion (Fig 1). The spermatic cord was progressively cauterized and transected with a blade at a distance of 6 to 7 cm from the testicle (Fig 2). Once the testicle was cut free, any hemorrhage was inspected from the remnant tissue. The other testicle was also removed as described.

The surgical region was rinsed with sterile saline and 2 ml of 0.5% bupivacaine (Bupivacaine HCl Myungmoon INJ 0.5%, Myungmoon Pharm. Co., Ltd.) was injected on the scrotum. Incisional site was closed with a continuous suture of 3-0 polyglyconate in the subcutaneous tissue. The skin was closed with tissue glue (Vetbond, 3M, USA), so that there was no stitch on the skin. The operation was followed by an administration of 6 mg/kg cefovecin (Convenia, Zoetis, USA) subcutaneously. The endotracheal tube was removed, the bears were transported to the individual facility, and 100 µg/kg atipamezole (Antisedan, Pfizer) were injected intramuscularly. The bears recovered uneventfully from general anesthesia after a duration of 58 min (bear A) and 53 min (bear B). Total surgical time was 26 min (bear A) and 24 min (bear B).

After operation, each bear received 0.1 mg/kg meloxicam once a day for two days orally. They were fed full rations



**Fig 2.** The vessel sealing device was placed around the entire spermatic cord of 25 mm diameter for tissue fusion (a). Using the LigaSure device, the spermatic cord was cauterized and transected with a blade. Due to the thickness of the spermatic cord, the process was carried out progressively (b).

and showed good body condition 24 h postoperatively. Surgical wound healed with no postoperative complications.

## Discussion

The anatomical information of the male reproductive system is not well-known in the Asiatic black bear, also in other species of bears. It is usually compared to that of dogs, which is well described in the literature (3). In the present cases, the operation was performed with reference to the method set out in dogs without problems, and specific anatomical differences were not observed. This condition was similar to European brown bears (7). This is the first report that describes orchietomy in the Asiatic black bear.

Previously, orchietomies were carried out on brown bears by the closed method via pre-scrotal incision (7) or two skin incisions parallel to raphe scroti (5,7) using absorbable suture materials for spermatic cord ligation. In this study, orchietomy was performed in a similar manner as did Radišić *et al.* (7), but the LigaSure vessel sealing device was used as an alternative to suture materials. This device has been approved for fusion of vessels and tissue up to 7 mm in diameter by electrical energy and pressure that liquefy and reform the collagen and elastin (1). Although the diameter of tissue bundle exceeded 7 mm, gradual cauterization on the spermatic cord of 25 mm diameter achieved successful tissue sealing without hemorrhage. The castration wounds could be left open (5) or closed with suture material (7), but we closed surgical wound with tissue glue to avoid self-trauma and subsequent removal of the stitches. The use of LigaSure saved surgical time and minimized blood loss. During the recovery period, there was no complication, such as swelling, hemorrhage, seroma formation and dehiscence.

Safe anesthesia is essential for manipulation with this animal species. Ketamine is one of the most commonly used agents in bears, which could be used with a combination of xylazine hydrochloride (7,8). A combination of tiletamine-zolazepam, being more potent than ketamine on a milligram per kilogram basis, is also used commonly to immobilize bears, but the major disadvantage of it was the lack of a

reversal agent (8). That could be reconstituted with another immobilization agent such as medetomidine (6). This tiletamine-zolazepam-medetomidine combination provides effective doses in small volumes and permits the use of atipamezole as a reversal agent (8). In the present study, the use of isoflurane via endotracheal inhalation with the combination of 2 mg/kg tiletamine-zolazepam and 40 µg/kg medetomidine provided sufficient and safe general anesthesia to perform orchiectomy. No painful reaction or resistance to manipulation was observed during the intervention. After postoperative injection of 100 µg/kg atipamezole, quick and uneventful recovery was achieved from general anesthesia.

In conclusion, orchiectomy was performed successfully in two male Asiatic black bears without major complication. The use of LigaSure alternative to suture materials was safe and effective technique for castration in bears. This technique also seemed to be applicable to other wildlife species.

## References

1. ValleyLab Technology. [Accessed March 10, 2010]. Available at: <http://www.ligasure.com/ligasure/pages.aspx>
2. Garshelis DL, Steinmetz R (IUCN SSC bear specialist group). *Ursus thibetanus*. In: IUCN 2014. IUCN Red List of Threatened Species; Version 2014. 2.
3. Hedlund CS. Surgery of the reproductive and genital systems. In: Fossum TW (ed), *Small Animal Surgery*, 3rd ed, St. Louis: Mosby. 2007: 702-774.
4. Jeong DH, Kang HN, Jeong WJ, Kim JJ, Yang JJ, Kim MW, Yang DH, Lee BK. status of Asiatic black bear restoration project in Korea. 21th International Conference on Bear Research and Management. New Delhi, India. 2012: 150.
5. Ledecký V, Nemčko J, Hluchý M, Horňák S, Holovský J. Immobilisation of the brown bear (*Ursus arctos*) during castration. *Folia Vet* 2003; 47: 83-85.
6. Pizzi R, Cracknell J, David S, Laughlin D, Broadis N, Rouffignac M, Duong DV, Girling S, Hunt M. Laparoscopic cholecystectomy under field conditions in asiatic black bears (*Ursus thibetanus*) rescued from illegal bile farming in vietnam. *Vet Rec* 2011; 169:469.
7. Radišić B, Huber D, Lipar M, Gomercic T, Kusak J. Orchiectomy in the european brown bear. *Vet Arh* 2007; 77: 271-279.
8. Ramsay EC. Ursidae and hyaenidae. In: Fowler ME, Miller RE (eds), *Zoo and Wild Animal Medicine*, 5th ed, St. Louis: Saunders. 2003: 523-538.
9. Song DJ, Lee BK, Yang DH, Jeong DH, Jeong SJ, Jeong WJ. Research and monitoring of the Asiatic black bear in Jirisan National Park. Korea National Park Service. 2009: 5-11.

## 반달가슴곰에서 시행된 고환절제술

정동혁\*<sup>†</sup> · 이승용<sup>†</sup> · 양정진\* · 석성훈 · 공주연\* · 박세진 · 진소영 · 김민향  
이배근\* · 이희천\*\* · 연성찬<sup>1</sup>

경상대학교 수의과대학 수의외과 · 행동학 연구실, \*국립공원관리공단 중북원기술원  
\*\*경상대학교 수의과대학 수의영상의학 연구실

**요 약** : 반달가슴곰 (*Ursus thibetanus*)은 국제적 멸종위기종으로, 국립공원관리공단에서 중북원 프로그램을 진행 중이다. 하지만 자연방사가 어려운 개체들은 제한된 사육 시설로 인해 곰 개체수 관리가 필요하여 수컷에서 고환절제술을 시행하였다. Tiletamine-zolazepam 2 mg/kg과 medetomidine 40 µg/kg 합제를 이용하여 곰을 포획하고, 기관 삽관을 통해 isoflurane으로 전신마취를 유지하였다. 고환절제술은 전음낭 절개를 통해 closed method로 시행되었으며, LigaSure를 사용하여 정삭을 소락·절단하였다. 절개면 피하조직은 흡수성 봉합사로 연속봉합 하였으며, 피부는 조직접착제로 봉합하였다. 별다른 부작용 없이 전신마취에서 회복되었으며, 총 마취 시간은 58분(곰 A)과 53분(곰 B)이었다. 수술시간은 26분(곰 A)과 24분(곰 B)이었으며, 술 후 부종이나 합병증은 관찰되지 않았다. 본 연구는 반달가슴곰에서 LigaSure를 이용한 최초의 고환절제술 증례이다.

**주요어** : 반달가슴곰, *Ursus thibetanus*, 고환, 고환절제술, 거세, LigaSure