

## IMAGES

## A Cystic Mass in the Popliteal Fossa and Its Differential Diagnosis

Hyun Ho Han, Ji Min Kim, Suk-Ho Moon

Department of Plastic Surgery, College of Medicine, The Catholic University of Korea, Seoul, Korea

**Correspondence:** Suk-Ho Moon

Department of Plastic Surgery, College of Medicine, The Catholic University of Korea, 222 Banpo-daero, Seocho-gu, Seoul 137-701, Korea  
Tel: +82-2-2258-6144, Fax: +82-2-594-7230, E-mail: nasuko@catholic.ac.kr

No potential conflict of interest relevant to this article was reported.

Received: 17 Dec 2014 • Revised: 26 Feb 2015 • Accepted: 27 Feb 2015  
pISSN: 2234-6163 • eISSN: 2234-6171  
<http://dx.doi.org/10.5999/aps.2015.42.4.484> • Arch Plast Surg 2015;42:484-486

Copyright © 2015 The Korean Society of Plastic and Reconstructive Surgeons  
This is an Open Access article distributed under the terms of the Creative Commons Attribution Non-Commercial License (<http://creativecommons.org/licenses/by-nc/3.0/>) which permits unrestricted non-commercial use, distribution, and reproduction in any medium, provided the original work is properly cited.

A cystic mass arising in the popliteal fossa can be either a meniscal cyst, a synovial cyst (Baker's cyst), or a ganglionic cyst [1]. Soft-tissue popliteal masses can be evaluated using physical examinations and imaging studies, such as computed tomography (CT) or magnetic resonance imaging (MRI). Thereafter, pathologic studies can be used for making a final confirmation of the diagnosis.

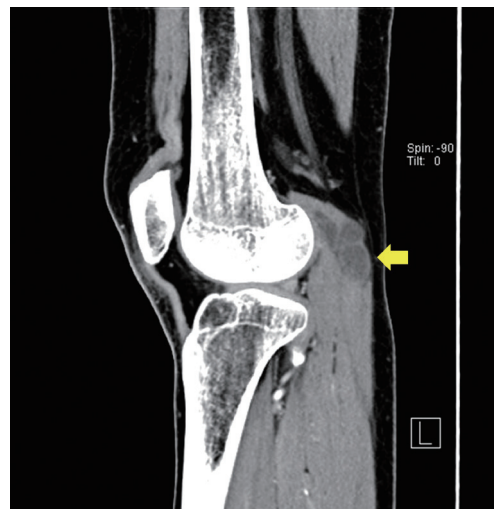
Ganglionic cysts are soft-tissue masses caused by the myxoid degeneration of the connective tissue at the joint capsules and tendon sheaths. They are filled with a gel-like material lined with a flat spindle cell membrane. They are common around the wrist or

the foot joint. When found in the popliteal fossa, they are mostly intra-articular cysts connected with the knee joint space and can rarely be intramuscular cysts [2]. Therefore, surgeons may mistake ganglionic cysts in the popliteal fossa for Baker's cysts or meniscal cysts.

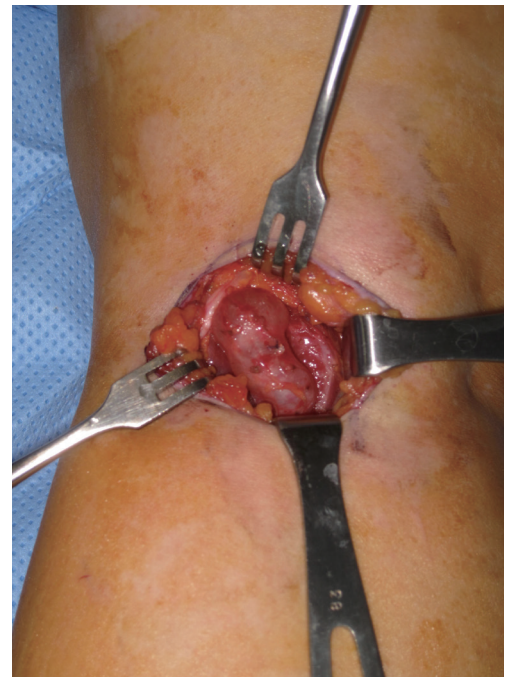A 47-year-old woman presented to our hospital with an 8-month history of a left calf mass in the popliteal fossa. She reported an increase in size and pain at palpation. She had no history of trauma or systemic diseases. Upon physical examination, we found a firm and fixed mass, measuring about 5 cm × 3 cm, over the popliteal fossa. She had a full range of motion of the knee joint and no symptoms.

Preoperative CT revealed a lobulated cystic mass measuring 5 cm × 3 cm in the proximal part of the lateral head of the gastrocnemius muscle. It was not connected within the knee joint space (Fig. 1). The mass appeared to be an intramuscular ganglionic cyst or an old hematoma; however, we were not able to rule out Baker's cyst due to the location.

Upon exploration, we opened the muscle sheath and found the mass located in the fiber of the gastrocnemius muscle. Being careful not to damage the lateral and medial sural nerve, we dissected the muscle and soft tissues around the mass and found no connection within the knee joint. Then, we



**Fig. 1.** Preoperative computed tomography scan shows a multi-lobulated hypodense lesion, measuring approximately 5 cm × 3 cm, within the proximal lateral gastrocnemius muscle (yellow arrow).



**Fig. 2.** Intraoperative field; the intramuscular ganglionic cyst is seen in the lateral head of the gastrocnemius muscle.

excised the mass with the stalk (Fig. 2). The mass was filled with a clear jelly-like fluid (Fig. 3).

Histopathology confirmed the diagnosis of an intramuscular ganglionic cyst (Fig. 4). The 8-month postoperative follow-up was uneventful.

Various types of cystic masses can develop in the popliteal fossa. Surgeons should be aware of the distinction among them, given the different treatment options, particularly for meniscal cysts, synovial cysts (Baker's cysts), and ganglionic cysts (Table 1).

A meniscal cyst is formed by the accumulation of the synovial fluid in the meniscocapsular junction leaking through the tear or degeneration of the meniscus [3]. The excision of the cyst and debridement of the damaged meniscus is a gold standard of cyst treatment. If the cyst is confined in the joint space, an arthroscopic approach is possible. A meniscal cyst is differentiated from a Baker's cyst by its lining of spindle-shaped cells, similar to a ganglionic cyst.

A synovial cyst is a common cystic mass, referred to as a Baker's cyst or a popliteal cyst when arising in the popliteal area. It is caused by the bulging of the gastrocnemio-semimembranosus bursa toward the weakest part of the posteromedial joint capsule [3]. This cyst affects the medial head of the gastrocnemius muscle and is diagnosed by the pathologic confirmation of the synovial lining. A definite treatment is a total excision and ligation of the stalk from the joint space by an arthroscopic procedure in the joint space, if needed.

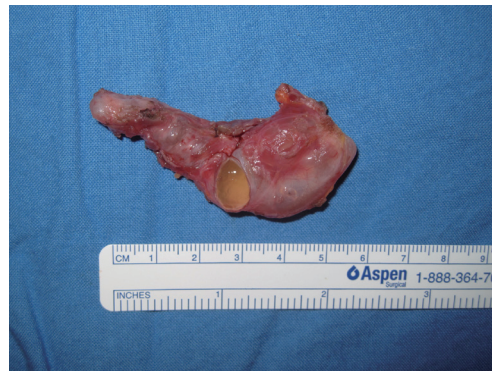A ganglionic cyst is commonly found in the wrist as an intra-articular cyst. It is thought to arise from the tendon sheath or joint capsule; however, the underlying mechanism is still unknown. There are few reports of intramuscular ganglionic cysts throughout the body. The treatment of this cyst is total excision, including the stalk from the joint ligament or tendon sheath, in order to prevent

recurrence. In our case, the cyst was located in the muscle, thereby requiring *en bloc* resection, including the surrounding muscle. Temporarily, needle aspiration can be helpful for reducing the cyst size and relieving the symptoms.

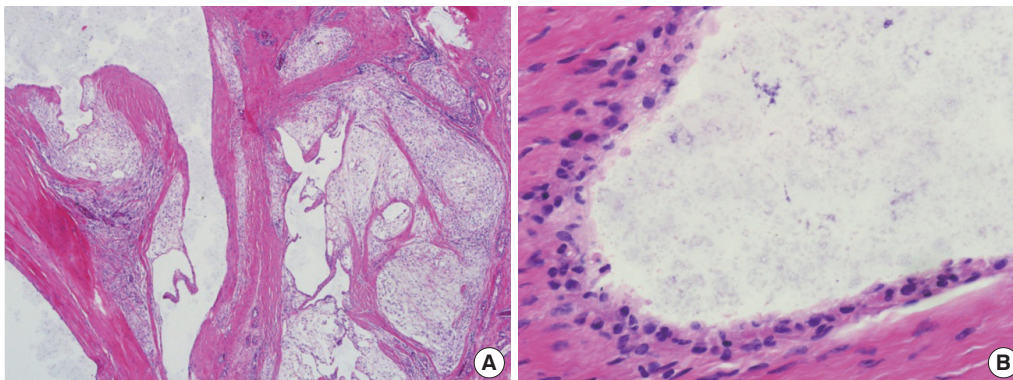
We initially thought that the cystic mass was a Baker's cyst due to the common incidence in that location, although the CT findings conveyed the possibility of an intramuscular ganglionic cyst. However, a Baker's cyst arises from the medial head of the gastrocnemius muscle and has no stalk-like structure connected with the joint space; hence, we ruled it out.

MRI is more helpful in the diagnosis of a popliteal cystic mass. In the T2-weighted image, the intramuscular ganglion shows an isodense signal intensity with the skeletal muscle or in some cases, a fibrous capsule with a low signal intensity at the peripheral margin. A Baker's cyst is a low-signal-intensity lesion on T1-weighted images and a high-signal-intensity lesion on T2-weighted images. The most important feature of a meniscal cyst in MRI is a cystic mass associated with a meniscal tear [4]. In our case, MRI might have been helpful for diagnosis, if it had been performed preoperatively.

There are many crucial structures in the popliteal fossa, namely popliteal artery and vein, tibial nerve,



**Fig. 3.** The mass is about 5 cm × 3 cm in size and has a stalk attached to the lateral ligament of the knee and contains a gelatinous material.



**Fig. 4.** (A) Pathologic findings (40×), (B) (400×) with multiple cystic chambers containing glairy material. The walls are composed of bland fibrous tissue with no specialized lining and surrounding muscle cells (H&E stain).

**Table 1. Differential diagnosis of a cystic mass arising in the popliteal area**

Characteristics	Ganglionic cyst	Synovial cyst (Baker's cyst)	Meniscal cyst
Related structure	Joint-related ligament and tendon Non-specific intramuscular origin	Gastrocneio-semimembranous bursa	Meniscal tear or degeneration
Knee joint association	±	+	+
Lining cell	Flat spindle-shaped cell (no synovial lining cell)	Synovial lining cell	Flat spindle-shaped cell (no synovial lining cell)
Induce joint limitation of motion or nerve compression	Possible	Possible	Possible
Magnetic resonance imaging finding	Hyperintense To skeletal muscle on T2-weighted image	High signal On T2-weighted and low signal on T1-weighted image	Tear of meniscus with a connection to the cyst
Recommended treatment	Excision or non-surgical option <sup>a)</sup> (e.g., needle aspiration)	Excision or arthroscopic debridement	Excision or arthroscopic debridement

<sup>a)</sup>Non-surgical option is not a definite treatment.

and medial and lateral sural nerves. A Baker's cyst in this area can cause lower leg pain, paresthesia, and muscle weakness by the compression of the tibial nerve [5]. The authors were careful not to damage the lateral and medial sural nerves while dissecting the lateral head of the gastrocnemius muscle. Surgeons should have a precise plan to explore and dissect the popliteal fossa and to not damage vital structures; further, they should explain the possibility of a nerve injury to patients, preoperatively.

A case of an intramuscular ganglionic cyst has been rarely reported. Moreover, this cyst is easily mistaken for a Baker's cyst or a meniscal cyst in the popliteal fossa. Surgeons should be aware of the differential diagnosis among cystic masses for definite treatments. The details of the differential diagnosis are provided in Table 1. Preoperative imaging studies can be helpful, particularly MRI. Here, we have reported a rare case of an intramuscular ganglionic cyst and the distinction among the popliteal cystic masses in order to help with their diagnosis and treatment.

## References

1. Sansone V, de Ponti A, Paluello GM, et al. Popliteal cysts and associated disorders of the knee. Critical review with MR imaging. *Int Orthop* 1995;19:275-9.
2. Krudwig WK, Schulte KK, Heinemann C. Intra-articular ganglion cysts of the knee joint: a report of 85 cases and review of the literature. *Knee Surg Sports Traumatol Arthrosc* 2004;12:123-9.
3. Morrison JL, Kaplan PA. Water on the knee: cysts, bursae, and recesses. *Magn Reson Imaging Clin N Am* 2000;8:349-70.
4. Tschirch FT, Schmid MR, Pfirrmann CW, et al. Prevalence and size of meniscal cysts, ganglionic cysts,

synovial cysts of the popliteal space, fluid-filled bursae, and other fluid collections in asymptomatic knees on MR imaging. *AJR Am J Roentgenol* 2003;180:1431-6.

5. McCarthy CL, McNally EG. The MRI appearance of cystic lesions around the knee. *Skeletal Radiol* 2004;33:187-209.

## Bimodal Treatment of a Huge Hypervascular Neurofibroma on the Groin

Eun Young Rha, Soo Yeon Lim, Hyung-Sup Shim

Department of Plastic and Reconstructive Surgery, Uijeongbu St. Mary's Hospital, College of Medicine, The Catholic University of Korea, Seoul, Korea

**Correspondence:** Hyung-Sup Shim  
Department of Plastic and Reconstructive Surgery, Uijeongbu St. Mary's Hospital, College of Medicine, The Catholic University of Korea, 271 Cheonbo-ro, Uijeongbu 480-717, Korea  
Tel: +82-31-820-3028, Fax: +82-31-847-0301  
E-mail: sharpshim@catholic.ac.kr

No potential conflict of interest relevant to this article was reported.

Received: 23 Jan 2015 • Revised: 10 Mar 2015 • Accepted: 20 Mar 2015  
pISSN: 2234-6163 • eISSN: 2234-6171  
<http://dx.doi.org/10.5999/aps.2015.42.4.486> • Arch Plast Surg 2015;42:486-489

Copyright © 2015 The Korean Society of Plastic and Reconstructive Surgeons  
This is an Open Access article distributed under the terms of the Creative Commons Attribution Non-Commercial License (<http://creativecommons.org/licenses/by-nc/3.0/>) which permits unrestricted non-commercial use, distribution, and reproduction in any medium, provided the original work is properly cited.

Neurofibromatosis type I (NF-I) is an autosomal dominant genetic disorder. The corresponding vascular disease is referred to as NF-I vasculopathy, which includes aneurysms, stenoses, and arteriovenous malformations (AVMs) [1-3].