

## Case Report

# Intracranial Undifferentiated Sarcoma Arising from a Low-Grade Glioma : A Case Report and Literature Review

Bum-Joon Kim, M.D., Ph.D., Jong-Hyun Kim, M.D., Ph.D., Hung-Seob Chung, M.D., Ph.D., Taek-Hyun Kwon, M.D., Ph.D.

Department of Neurosurgery, Korea University Guro Hospital, Seoul, Korea

Undifferentiated sarcomas are rarely identified in the intracranial region. A 23-year-old man was admitted with a chief complaint of headache. Initial magnetic resonance images showed signs of low-grade glioma in the frontal lobe. Stereotactic biopsy was performed, and a diagnosis of diffuse astrocytoma was confirmed. Three months later, the patient presented with a high-grade tumor as seen on imaging studies. He underwent total resection of the tumor and histopathological tests identified an undifferentiated sarcoma. The patient died eight months later due to massive tumor bleeding. To the best of our knowledge, this is the first report of undifferentiated sarcoma arising from low-grade glioma without any chemotherapy or radiotherapy.

**Key Words :** Intracranial undifferentiated sarcoma · Malignant fibrous histiocytoma · Low-Grade glioma · Malignant transformation · Stereotactic biopsy.

## INTRODUCTION

Primary intracranial undifferentiated sarcoma is an extremely rare entity. Undifferentiated sarcomas, formerly known as malignant fibrous histiocytomas (MFH), are usually identified in the soft tissue of the extremities and trunk<sup>2,10,13</sup>. A literature review of intracranial undifferentiated sarcomas, including the formerly used less-specific term MFH, identified less than three dozen cases reports since 1976<sup>6,9,12,16</sup>. Among these case reports of intracranial sarcomas, very few describe a transformation from pre-existing intracranial tumors. Intracranial sarcomas developed after radiosurgery in three cases<sup>11,12,14</sup> and after chemotherapy in one case<sup>1</sup>. These reports suggest that intracranial undifferentiated sarcomas can be derived by the transformation of other tumors of the nervous system. However, the exact mechanism and risk factors remain undefined.

Here, we report our experience in managing a rapidly growing intracranial undifferentiated sarcoma in a young adult who was initially diagnosed with a low-grade glioma. To the best of our knowledge, this is the first report of undifferentiated sarcoma arising from low-grade glioma without any chemotherapy or radiotherapy.

## CASE REPORT

A 23-year-old man presented with headache and loss of consciousness. Brain magnetic resonance (MR) imaging revealed an intra-axial, non-enhancing solitary lesion in the right frontal lobe, which was hyperintense on fluid-attenuated inversion recovery (FLAIR) imaging (Fig. 1A, B). MR spectroscopy (MRS) demonstrated a prominent choline (Cho) peak and a reduction in N-acetyl-aspartate (NAA) (Fig. 1C, D). A stereotactic biopsy specimen was obtained from the area that showed the highest Cho/NAA ratio (approximate value of 2.0). Histopathological tests identified a diffuse astrocytoma [World Health Organization (WHO) grade II]. As per the patient's wishes of postponing any further tumor removal, the patient was discharged at that point of time. Three months later, the patient presented with severe headache and was admitted. Brain MR imaging showed a right frontal mass with strong enhancement and central necrosis (Fig. 2A). The patient was scheduled to undergo surgical removal of the tumor. A hypervascular, friable, intraparenchymal mass was identified, and gross total removal was achieved (Fig. 2B). The final histopathological diagnosis was undifferentiated sarcoma. Postoperatively, the patient showed no definite neuro-

• Received : February 27, 2014 • Revised : March 14, 2014 • Accepted : June 10, 2014

• Address for reprints : Taek-Hyun Kwon, M.D., Ph.D.

Department of Neurosurgery, Korea University Guro Hospital, 148 Gurodong-ro, Guro-gu, Seoul 152-703, Korea  
Tel : +82-2-2626-1178, Fax : +82-2-2626-1179, E-mail : ns806@kumc.or.kr

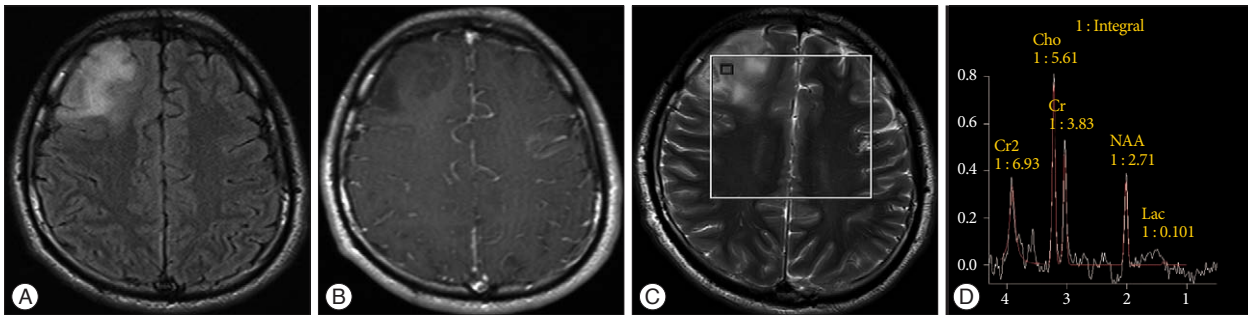
• This is an Open Access article distributed under the terms of the Creative Commons Attribution Non-Commercial License (<http://creativecommons.org/licenses/by-nc/3.0>) which permits unrestricted non-commercial use, distribution, and reproduction in any medium, provided the original work is properly cited.

logic deficit. One month later, he was discharged and was followed-up with outpatient adjuvant radiotherapy. However, five months after tumor removal, he visited the emergency room with severe headache. Brain MR imaging showed tumor recurrence. A second tumor removal operation was performed (Fig. 2C). Postoperatively, the patient suffered left hemiparesis caused

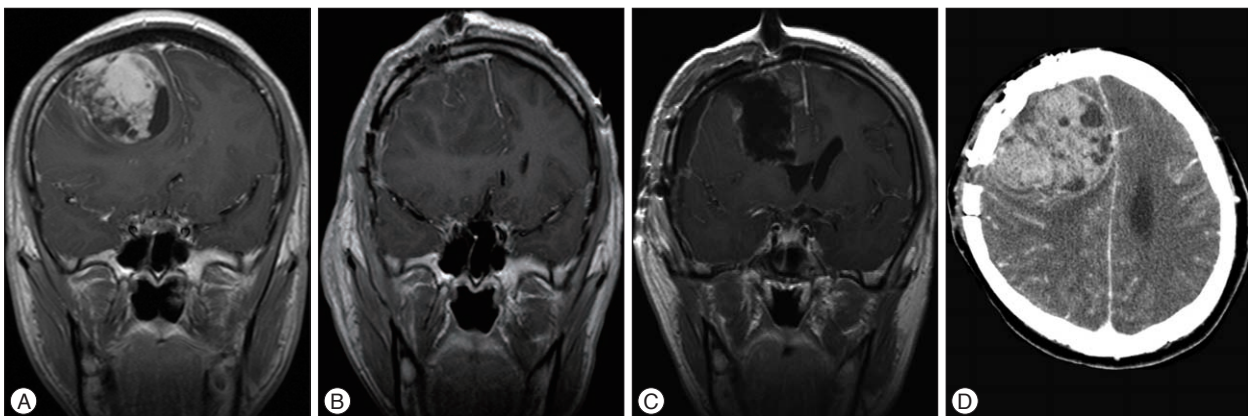
by radical tumor resection. Two months later, he died of severe brain herniation caused by extensive regrowth and bleeding of the intracranial sarcoma (Fig. 2D).

### Histopathological findings

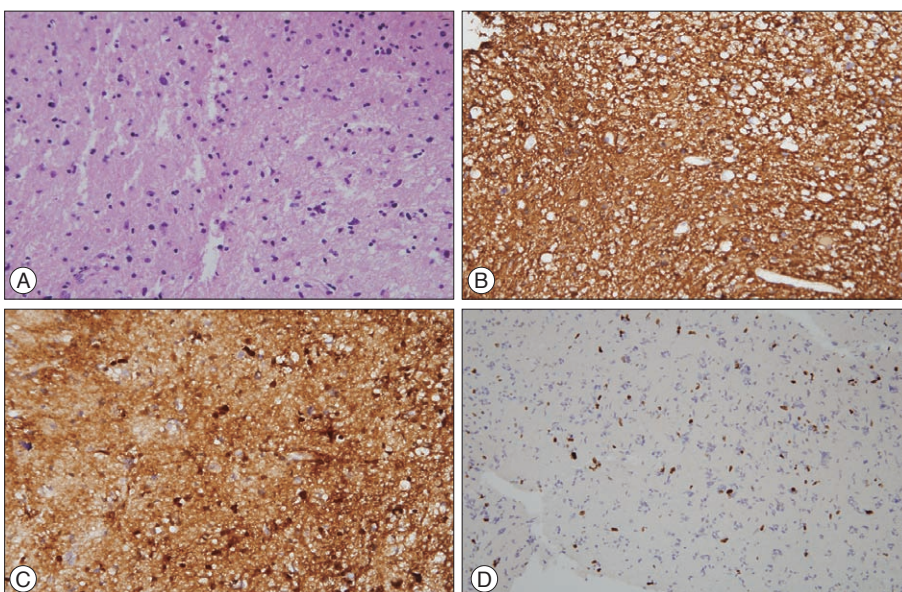
Tumor tissue was obtained by stereotactic biopsy (Fig. 3). AI-



**Fig. 1.** Fluid-attenuated inversion recovery image reveals a hyperintense solid intraaxial lesion in the right frontal lobe (A). Contrast-enhanced T1 image shows a hypointense lesion without any enhancement (B). Magnetic resonance spectroscopy was used to define the biopsy target, which showed an increased choline/N-acetyl aspartate ratio (C and D). Cho : choline, Cr : creatine, NAA : N-acetyl-aspartate, Lac : lactate.

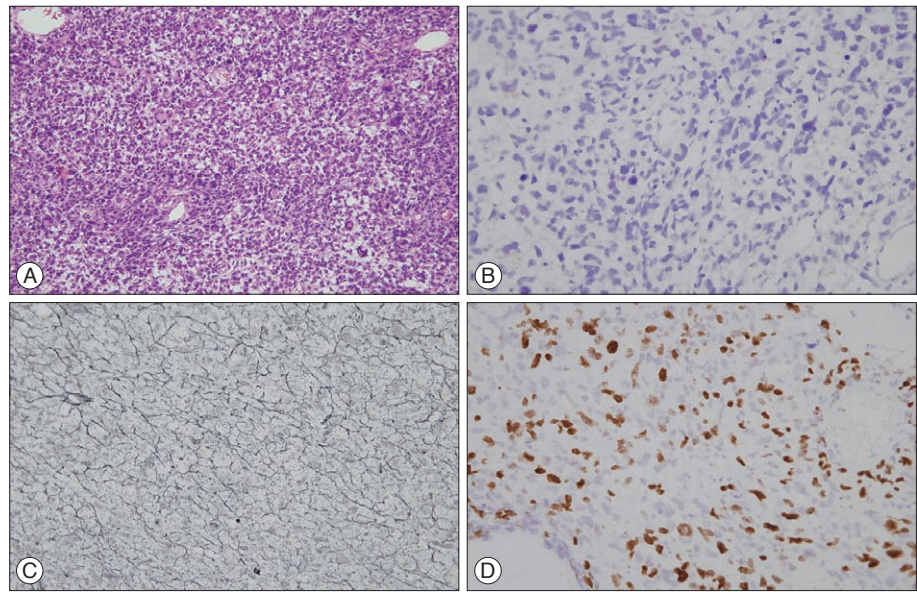


**Fig. 2.** Magnetic resonance (MR) imaging shows the heterogeneously enhancing tumor and subfalcine herniation (A). Tumor tissue obtained by gross total resection (B). Five months later, the recurred tumor was radically resected (C). Computed tomography showing large tumor regrowth with internal bleeding (D).



**Fig. 3.** Stereotactic biopsy of the initial tumor. A : Photomicrograph shows atypia without any necrosis or vascular proliferation (H-E,  $\times 400$ ). B : On immunohistochemistry, the tumor cells were immunoreactive for glial fibrillary acidic protein ( $\times 400$ ). C : Staining for S-100 protein was positive ( $\times 400$ ). D : The Ki-67 labeling index was 3% ( $\times 200$ ).





**Fig. 4.** Resection of the heterogeneously enhancing tumor. A : Photomicrograph revealed hyperchromatic pleomorphic nuclei, spindle cells, and giant cells (H-E,  $\times 200$ ). B : The tumor cells showed no immunoreactivity for glial fibrillary acidic protein ( $\times 400$ ). C : Reticulin staining shows an encapsulating pericellular reticulin network ( $\times 400$ ). D : The Ki-67 labeling index was increased to 20% ( $\times 400$ ).

though the tumor tissue showed atypism and higher cellularity than normal brain tissue, there was no mitosis, necrosis, or vascular proliferation (Fig. 3A). On immunohistochemistry, staining for glial fibrillary acidic protein (GFAP) (Fig. 3B) and S100 protein (Fig. 3C) was positive and the Ki-67 labeling index was 3% (Fig. 3D). These findings were compatible with diffuse astrocytoma, WHO grade II.

Tissue obtained from the surgical removal of the tumor (Fig. 4) showed significantly increased cellularity and pleomorphic hyperchromatic nuclei. Mitoses were frequently observed. Giant cells and spindle-shaped cells were also seen (Fig. 4A). On immunohistochemistry, staining for GFAP and S100 protein were negative (Fig. 4B). Reticulin staining revealed cells encapsulated by reticulin fibers (Fig. 4C), which is a typical finding of sarcomas. The Ki-67 labeling index was as high as 20% (Fig. 4D). There were no features characteristic of glial tumors.

## DISCUSSION

According to the latest WHO classification, the tumor case presented here can be classified as an undifferentiated sarcoma<sup>3)</sup>. Undifferentiated sarcomas can present as round cells, spindle cells, epithelioid cells, or pleomorphic cells and do not resemble any mature tissue<sup>4)</sup>. Because undifferentiated sarcoma is a novel entity, a literature search of previous reports was performed by using the formerly used term “MFH”.

Radiologically, intracranial undifferentiated sarcomas resemble high-grade gliomas, which may present with heterogeneous contrast enhancement, central necrosis, and surrounding edema<sup>15)</sup>. In our patient, perilesional edema was not severe, but the heterogeneous rim enhancing pattern and previous histopathological report suggested a high-grade glioma, and follow-up computed tomography imaging demonstrated recurrent tumor bleeding. We concluded that the MR imaging findings of the

undifferentiated sarcoma reflected the aggressive nature of the tumor.

The tumor was locally progressive without any evidence of distant metastasis. Despite the repeated tumor resections, recurrence and bleeding caused by the rapid growth of the tumor resulted in the fatal outcome. Although the histopathological findings are similar, we opine that intracranial undifferentiated sarcomas are a different entity from extracranial sarcomas. Based on the previous reports, the mean age of the intracranial sarcoma cases was 38.7 years<sup>9)</sup> while our patient was 23 years old; the mean age in the extracranial cases was reported to be approximately 60 years<sup>2,7)</sup>. Since extirpation of intracranial tumors is more difficult, the survival period of the intracranial undifferentiated sarcoma is much shorter. In the review of 32 intracranial MFHs by Mitsuhashi et al.<sup>9)</sup>, most of the patients with intracranial MFH died within 1 year from diagnosis. In contrast, the overall 5-year survival of primary undifferentiated sarcomas arising from the extremities has been reported to be over 70%<sup>2,7)</sup>.

One of the possible explanations of how this uncommon sarcoma arises from low-grade glioma is pre-existing heterogeneity of two pathologies since the initial tumor diagnosis. Minimal invasive biopsy surgery is limited in its scope, and there is a possibility of sampling error. The rapidly growing undifferentiated tumor might supersede the comparatively slow growth of low-grade glioma in later stages. Another possibility is that the malignant transformation was triggered by surgical trauma. The initial MR images and tumor tissue obtained by stereotactic biopsy did not show any findings suggesting a high-grade tumor. However, after the biopsy, the tumor underwent rapid progression. Although there are no references on this kind of mechanism in the literature, few investigators have speculated the potential role of wounds in oncogenesis. Hofer et al.<sup>5)</sup>, in an animal study, reported the increased tumor growth after surgi-

cal wounding. Meng et al.<sup>8)</sup>, described that wounds can be a risk factor for cancer by means of oncogene activation in wound healing process.

According to the literature on undifferentiated sarcomas of extremities, radical resection of the tumor is the treatment of choice and chemotherapy and radiotherapy are also helpful in lowering the recurrence rate<sup>2,10)</sup>. However, in cases of intracranial undifferentiated sarcomas, authors have reported recurrence and poor prognosis after recommended treatment. Chemoradiotherapy shows temporary improvement but does not change the prognosis dramatically<sup>6,9,11)</sup>. In our case, the patient received adjuvant radiotherapy after the first resection of the sarcoma. However, the patient showed tumor recurrence after five months.

It is known that subtotally resected low-grade gliomas can transform to high-grade tumors, and in cases of undifferentiated sarcoma, the course is rapid and fatal. Rapidly growing refractory intracranial tumors are challenging for neurosurgeons. Although it is not usual, sporadic reports about malignant transformation by radiation, chemotherapy, and surgical trauma suggest that the early tumor resection is more ideal in young adults.

## CONCLUSION

We report our experience in managing a fatal case of intracranial undifferentiated sarcoma. The tumor was locally progressive without any evidence of distant metastasis. However, the treatment strategy of intracranial undifferentiated sarcoma is not established yet. This is the first report of undifferentiated sarcoma arising from low-grade glioma without radiation or any other antitumor therapy. We hope this report will provide information for a better understanding of the pathophysiology of undifferentiated sarcomas.

## References

1. Alexandru D, Linskey ME, Kim RC, Bota D : Undifferentiated sarcoma induced by BCNU (1,3-bis(2-chloroethyl)-1-nitrosourea) wafers. *J Interdiscipl Histopathol* 1 : 163-167, 2013
2. Brennan MF, Antonescu CR, Maki RG : Undifferentiated Pleomorphic

Sarcoma (UPS; Malignant Fibrous Histiocytoma : MFH) and Myxofibrosarcoma in Brennan MF, Antonescu CR, Maki RG (eds) : **Management of Soft Tissue Sarcoma**, ed 1. New York : Springer Science & Business Media, 2013, pp129-136

3. Fletcher CD : The evolving classification of soft tissue tumours - an update based on the new 2013 WHO classification. *Histopathology* 64 : 2-11, 2014
4. Fletcher CD : Undifferentiated sarcomas : what to do? And does it matter? A surgical pathology perspective. *Ultrastruct Pathol* 32 : 31-36, 2008
5. Hofer SO, Shrayer D, Reichner JS, Hoekstra HJ, Wanebo HJ : Wound-induced tumor progression : a probable role in recurrence after tumor resection. *Arch Surg* 133 : 383-389, 1998
6. Kosucu P, Yavuz AA, Yavuz MN, Reis A, Ahmetoglu A : Primary intracranial malignant fibrous histiocytoma : case report. *Eur J Radiol Extra* 47 : 78-81, 2003
7. Lehnhardt M, Daigeler A, Homann HH, Schwaiberger V, Goertz O, Kuhnen C, et al. : MFH revisited : outcome after surgical treatment of undifferentiated pleomorphic or not otherwise specified (NOS) sarcomas of the extremities-an analysis of 140 patients. *Langenbecks Arch Surg* 394 : 313-320, 2009
8. Meng X, Zhong J, Liu S, Murray M, Gonzalez-Angulo AM : A new hypothesis for the cancer mechanism. *Cancer Metastasis Rev* 31 : 247-268, 2012
9. Mitsuhashi T, Watanabe M, Ohara Y, Hatashita S, Ueno H : Multifocal primary intracerebral malignant fibrous histiocytoma-case report. *Neurol Med Chir (Tokyo)* 44 : 249-254, 2004
10. Nascimento AF, Raut CP : Diagnosis and management of pleomorphic sarcomas (so-called "MFH") in adults. *J Surg Oncol* 97 : 330-339, 2008
11. Sasagawa Y, Tachibana O, Iizuka H : Undifferentiated sarcoma of the cavernous sinus after  $\gamma$  knife radiosurgery for pituitary adenoma. *J Clin Neurosci* 20 : 1152-1154, 2013
12. Schmitt WR, Carlson ML, Giannini C, Driscoll CL, Link MJ : Radiation-induced sarcoma in a large vestibular schwannoma following stereotactic radiosurgery : case report. *Neurosurgery* 68 : E840-E846; discussion E846, 2011
13. Weiss SW, Enzinger FM : Malignant fibrous histiocytoma : an analysis of 200 cases. *Cancer* 41 : 2250-2266, 1978
14. Yang T, Rockhill J, Born DE, Sekhar LN : A case of high-grade undifferentiated sarcoma after surgical resection and stereotactic radiosurgery of a vestibular schwannoma. *Skull Base* 20 : 179-183, 2010
15. Yoo RE, Choi SH, Park SH, Jung HW, Kim JH, Sohn CH, et al. : Primary intracerebral malignant fibrous histiocytoma : CT, MRI, and PET-CT findings. *J Neuroimaging* 23 : 141-144, 2013
16. Yun LG, Shin WH, Kim BT, Choi SK, Byun BJ, Lee DW : Malignant fibrous histiocytoma presenting as osteolytic lesion on the left temporal bone : a case report. *J Korean Neurosurg Soc* 24 : 471-476, 1995