

The surgical retrieval of a broken dental needle: A case report

Jiseon Lee¹, Min Woo Park¹, Min Keun Kim², Soung Min Kim¹, Kwang-Suk Seo³

¹Department of Oral and Maxillofacial Surgery, School of Dentistry, Seoul National University, Seoul, Korea

²Department of Oral and Maxillofacial Surgery, College of Dentistry, Gangneung-Wonju National University, Gangneung, Korea

³Department of Dental Anesthesiology, Dental Research Institute, School of Dentistry, Seoul National University, Seoul, Korea

One complication related to local anesthesia in the dental clinic is a broken needle. Although rare, a broken needle may be difficult to retrieve. Dental radiographs and 3D CT have been used in the past to confirm the location of a broken needle. We present the case of a broken needle, which was successfully removed using a careful, microscopic approach.

Key Words: Broken dental needle, Local anesthesia, Microscope, Complications.

Local anesthesia is commonly used in dental clinics for pain control. For instance, the inferior alveolar nerve block is a useful method to anesthetize the posterior mandibular area.

Needle breakage is a rare complication of inferior alveolar nerve block anesthesia [1]. Its prevalence has decreased with better materials and practitioner training [1,2].

We report the case a broken needle in the pterygo-mandibular space, and discuss preventive measures regarding this complication.

CASE REPORT

A 68-year-old woman with a past medical history of hypertension and arrhythmia (on medications) was referred by her dentist to the Department of Oral and Maxillofacial Surgery at Seoul National University Dental Hospital. She was scheduled to undergo implant installation surgery on the left mandibular posterior area

in the clinic; however, a needle broke during inferior alveolar nerve block anesthesia. Therefore, she was referred to the hospital for its removal.

The patient was told to stop taking aspirin two weeks prior to her scheduled implant surgery.

A 30-gauge needle was used to anesthetize the left inferior alveolar block. However, the needle was broken in the process. The fragment disappeared into the tissues and the dental clinician was unable to retrieve it. Therefore, the patient was referred to the Department of Oral and Maxillofacial surgery at the university dental hospital. Surgeons failed to remove the needle under general anesthesia using CT (computed tomography) images (Fig. 1A). Next, the patient was referred to our department.

Upon her arrival to our department, the patient was having difficulty opening her mouth because of pain and her previous surgery. Radiographs including a panoramic view (Fig. 1B), a posterior-anterior skull (Fig. 1C) and lateral skull view (Fig. 1D) confirmed that the fractured needle was in the left pterygomandibular space. The

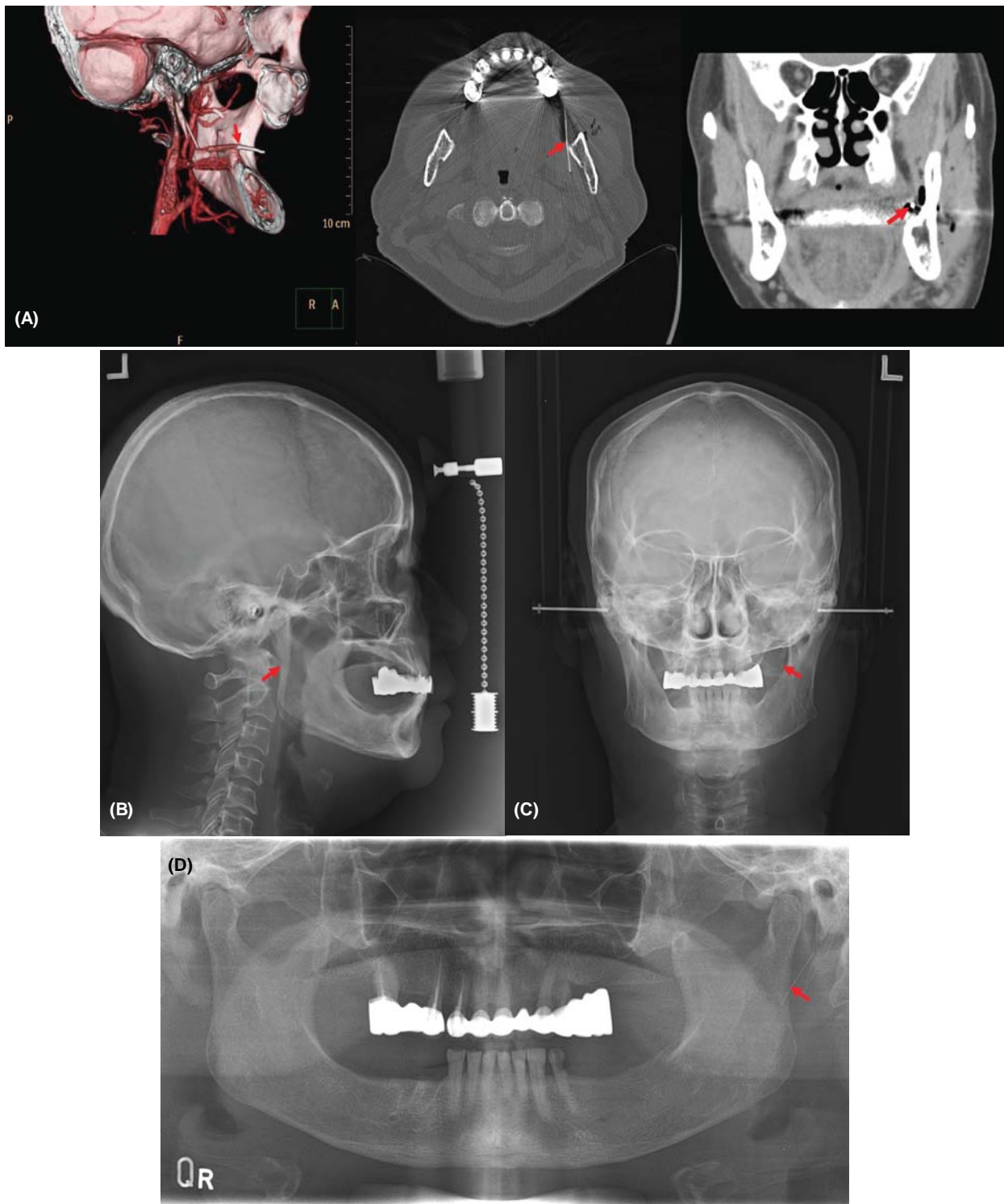


Fig. 1. Preoperative radiographic image illustrating the broken needle: (A) 3D computerized tomography, (B) lateral skull view, (C) posterior-anterior skull view, (D) panoramic view.

panoramic view revealed that the needle was on the posterior border of mandibular ramus. Based on these data, it was decided that surgical exploration under

general anesthesia was the most appropriate next step to retrieve the needle.

The patient underwent general anesthesia via naso-

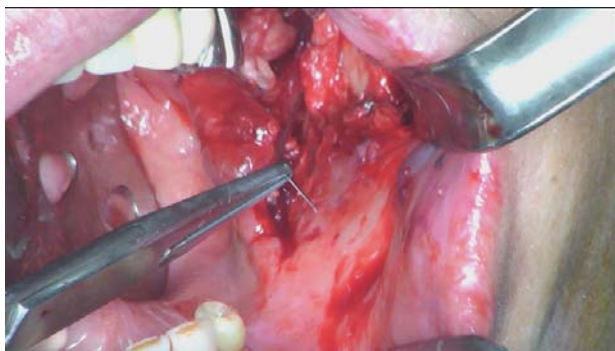


Fig. 2. The broken needle was removed using a hemostat forcep.

tracheal intubation. The patient was prepped and draped. In order to gain access, an existing suture was cut and a vertical incision was made along the existing incision from the first surgery. Blunt dissection was used medially along the ramus to expose the pterygomandibular space. A malleable retractor was used to protect the lingual and inferior alveolar nerves. Further exploration of the pterygomandibular space was performed using a microscope. The tip of the needle fragment was identified under the microscope. The broken needle was removed using a hemostat forcep (Fig. 2). This fragment was approximately 20 mm long and bent. No vital structures were injured in the process. The incision was closed using 3-0 and 4-0 Monocryl[®]. Total intraoperative time was about 2 hours. Postoperative radiographs confirmed that the broken needle had been completely removed (Fig. 3).

The patient recovered well postoperatively, without any pain or numbness. She was still interested in undergoing implant installation surgery. Therefore, she successfully underwent implant installation surgery on the left posterior mandibular area, and was discharged the next day.

DISCUSSION

Although it is possible for a needle to break in the maxillary area, it most often occurs during mandibular inferior alveolar nerve block anesthesia in the pterygomandibular space [2-6]. The pterygomandibular space

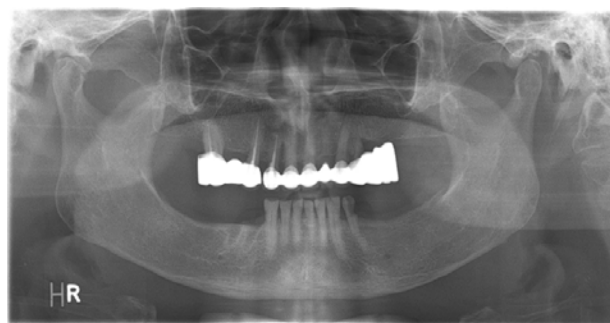


Fig. 3. A postoperative panoramic radiograph confirmed the needle's retrieval.

involves several masticatory muscles and the inferior alveolar nerve, which is targeted for inferior alveolar nerve block anesthesia [7,8]. It is very important to understand the anatomy of this space, not only for successful local anesthesia, but also for troubleshooting complications such as a broken needle.

Radiographic images are important in the localization of a broken needle. In this case, the patient was referred to our hospital several days after the needle was broken. Therefore, 3D CT images had already been taken. Nevertheless, we confirmed the change of location using additional radiographs including the standard panorama, lateral cephalogram, and skull PA images. Finally, the fragment was successfully retrieved under microscope guidance.

Needle breakage is a rare complications of local anesthesia [8]. However when it happens, like in this case, it is not always easily remedied. The retrieval process in this case required a lot of time and money. Therefore, it is important to perform local anesthesia as carefully as possible to avoid such a complication.

As previously mentioned, needles rarely break during local anesthesia because they are disposable and made with high quality material [1,9,10]. In most cases, a needle breaks at the connecting part between the metal and plastic [9]. Therefore, breakage may be a result of poor construction, rather than of material.

Most cases of breakage have occurred with 30-gauge short needles [9]. Compared to that of the 27-gauge needle, 30-gauge needles are less effective for pain relief

during needle penetration [9]. Therefore, there are no benefits to using a 30-gauge needle, especially for inferior alveolar nerve block anesthesia.

In conclusion, in order to prevent needle breakage during inferior alveolar nerve block, a 27-gauge long needle should be used. In addition, it is important to avoid inserting the hub of the needle into the soft tissue.

REFERENCES

1. Augello M, von Jackowski J, Gratz KW, Jacobsen C. Needle breakage during local anesthesia in the oral cavity—a retrospective of the last 50 years with guidelines for treatment and prevention. *Clin Oral Investig* 2011; 15: 3-8.
2. Lee TYT, Zaid WS. Broken dental needle retrieval using a surgical navigation system: A case report and literature review. *Oral Surg Oral Med Oral Pathol Oral Radiol* 2015; 119: e55-e9.
3. Bump RL, Roche WC. A broken needle in the pterygomandibular space: Report of a case. *Oral Surg Oral Med Oral Pathol* 1973; 36: 750-2.
4. Marks RB, McDonald S, Carlton DM. Management of a broken needle in the pterygomandibular space: Report of case. *J Am Dent Assoc* 1984; 109: 263-4.
5. Pogrel MA. Broken local anesthetic needles: A case series of 16 patients, with recommendations. *J Am Dent Assoc* 2009; 140: 1517-22.
6. Bedrock RD, Skigen A, Dolwick MF. Retrieval of a broken needle in the pterygomandibular space. *J Am Dent Assoc* 1999; 130: 685-7.
7. Barker BCW, Davies PL. The applied anatomy of the pterygomandibular space. *Br J Oral Surg* 1972; 10: 43-55.
8. Ogle OE, Mahjoubi G. Local anesthesia: Agents, techniques, and complications. *Dent Clin North Am* 2012; 56: 133-48.
9. Malamed SF, Reed K, Poorsattar S. Needle breakage: Incidence and prevention. *Dent Clin North Am* 2010; 54: 745-56.
10. Philbert R, Hamilton B, Zola M. Management of needle breakage using intraoperative navigation following inferior nerve block. *J Oral Maxillofac Surg* 2014; 72: 653.