

<Case Report>

Cervical lung lobe herniation in a Pekingese dog

Ran Choi^{1,2}, Sang-II Suh^{1,2}, Changbaig Hyun^{1,*}

¹Section of Small Animal Internal Medicine, College of Veterinary Medicine, Kangwon National University, Chuncheon 200-701, Korea

²Dasom Animal Medical Center, Busan 608-040, Korea

(Received: May 6, 2015; Accepted: June 6, 2015)

Abstract : An 8-year-old intact male Pekingese (weighing 13 kg) was presented for evaluation of chronic coughing. Thoracic radiography found a redundant tissue swelling (protruded on expiration and collapsed on inspiration) on the ventral neck just cranial to the thoracic inlet. Fluoroscopy also identified that the cranial portion of the right/left cranial lung lobe was seen to protrude through the thoracic inlet into the ventral neck on expiration. On the echocardiogram, there were no abnormal jets in all cardiac valves and no dilation in all cardiac chambers. Based on diagnostic imaging studies, the case was diagnosed as cervical lung lobe herniation.

Keywords : cervical lung lobe herniation, coughing, dog, lung, lung hernia

Lung lobe herniation is the protrusion of the lung beyond the thoracic cavity [3] and has rarely been reported in dogs [1, 2, 4, 5]. Although several etiologies involved in human lung lobe herniation (*e.g.* congenital, traumatic, spontaneous, pathologic, or postsurgical), spontaneous lung hernias associated with chronic respiratory diseases were most common in dogs [1-4]. Sudden increase in intrathoracic pressure was suggested as a major contributing factor for lung hernias in dogs, although congenitally weak fascia or musculature might play a minor role in the development of lung herniation [1, 4]. Although lung lobe herniation can be classified into cervical, thoracic, or diaphragmatic in humans [1], the cervical lung lobe herniation (CLLH) has only noticed in dogs [1, 2, 4]. The lung lobe herniation might be a benign pathological lesion which rarely causes clinical signs, although one study suggested complications including incarceration and strangulation of the herniated lobe, pain, hemoptysis, recurrent infection, and exercise intolerance [1]. This case report described a rare case of CLLH associated with recurrent respiratory disease.

An 8-year-old intact male Pekingese (weighing 13 kg) was presented for evaluation of chronic coughing for 2 months. According to the referring veterinarian, the dog had bacterial pneumonia, which was responded to antibiotics and antitussives. However, the coughing was on and off, although the frequency of coughing was diminished by this therapy. The reason for visit was cardiac examination for ruling out heart disease for the cause of coughing in this dog. At presenta-

tion, the dog was mildly depressed. Pulse rate was 125 beats/min and respiratory rate was 28 breaths/min. There were increased respiratory effort on expiration and marked bilateral respiratory noise on auscultation. However, there was no heart murmur both side of thorax. Systolic blood pressure measured by Doppler detector (Ultrasonic Doppler Flow Detectors Model 811-B; PARKS Medical Electronics, USA) was 150 mmHg. Electrocardiogram (ECG) found marked sinus arrhythmias with occasional sinus pause. However, there was no other abnormality on the ECG. Laboratory tests including complete blood cell count and serum biochemistry found no particular abnormalities. Right lateral thoracic radiography found a redundant tissue swelling (protruded on expiration and collapsed on inspiration) on the ventral neck just cranial to the thoracic inlet (Fig. 1A). On the ventrodorsal view of thoracic radiography, the swelling projected 12 cm cranial to the thoracic inlet at its peak (Fig. 1B). Thoracic radiography also revealed pectus excavatum. There was no cardiomegaly in this dog. Therefore, we tentatively made a diagnosis as the CLLH in this dog. To confirm the CLLH, we performed fluoroscopy. Fluoroscopy identified that the cranial portion of the right/left cranial lung lobe was seen to protrude through the thoracic inlet into the ventral neck on expiration (Fig. 2). Interestingly, the swelling of lung lobe was persisted even in inspiration, although the size of swelling was remarkably reduced in inspiration (Fig. 2A). There was no kinking/collapse of trachea and main stem bronchus in this dog. An echocardiogram was also performed to ruling

*Corresponding author

Tel: +82-33-250-8681, Fax: +82-33-259-5625

E-mail: hyun5188@kangwon.ac.kr

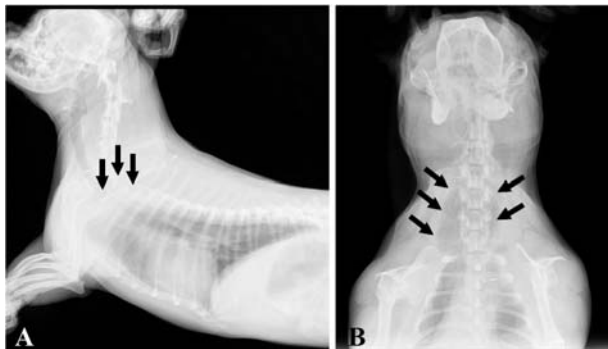


Fig. 1. Thoracic radiography in this case. (A) Right lateral projection of thoracic radiography found the protrusion (arrows) of cranial portion lung lobe beyond the thoracic inlet. (B) Ventrodorsal projection of thoracic radiography revealed the protrusion (arrows) of cranial portion lung lobe beyond the thoracic inlet. The lung lobe herniation projected 12 cm cranial to the thoracic inlet at its peak.

out cardiac disease. There were no abnormal jets in all cardiac valves and no dilation in all cardiac chambers. Treatment with prednisone (1 mg/kg PO q24h; Daemyoung, Korea) and tramadol (Ultram, 2 mg/kg PO q24h; Ortho-McNeil-Janssen Pharmaceuticals, USA) resulted in rapid alleviation of the dog's coughing and improvement continued to date.

CLLH in humans is associated with a congenital defect in Sibson's fascia [3], although it has never been reported in animals. Spontaneous CCLH in humans is often encountered in patients with chronic obstructive respiratory disease causing chronic coughing and lung hyperinflation. As noticed in other canine studies and human study [1-5], the cause of CLLH in this case study might be chronic coughing from recurrent respiratory disease. Although clear pathomechanism of CLLH has yet been clarified, sudden increase in intrathoracic pressure associated with clinical signs (e.g. chronic coughing) form chronic obstructive respiratory disease with partial weakness in the thoracic wall might play key role in pathomechanism.

Diagnosis of CLLH might be straightforward, if the large herniation is visualized in ventral neck near thoracic inlet. However, it is often hard to detect in plain thoracic radiography, because the swelling is on and off, depending on respiratory cycle. Therefore fluoroscopy is the best diagnostic method, because practitioners can evaluate lung movement during the respiratory cycle [1, 2, 4]. In addition, computed tomography may help to define the location and extent of the thoracic wall defect. In this case study, we could more easily detect the location and extent of CLLH on the fluoroscopic exam.

One retrospective study in dogs with CLLH found all affected dogs had a history of cough (4). Similar finding has also been reported in humans with CLLH [3]. There might be close association between CLLH and cough. In this case, the dog had history of chronic coughing from the early of his

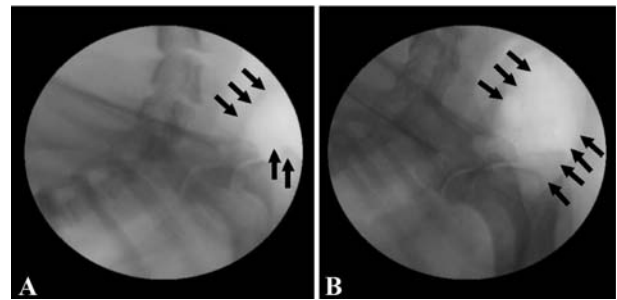


Fig. 2. Right lateral fluoroscopic images of the cranial portion of the cranial lung lobe moving through the thoracic inlet into the ventral neck (arrows) in inspiration (A) and expiration (B).

life. Although CLLH was found in various breeds of dog with various age, one study found it was more common in brachycephalic breeds (pug and Pekingese) and old dogs [1, 2]. Similarly to other reports [1, 2], our case was also old brachycephalic dog. One study also found kinking of the trachea and bronchial collapse were often seen in dogs with CLLH. Since these two diseases cause chronic coughing in dogs, the CLLH might be prone to occur in these situations. Chronic obstructive airway disease was closely related to CLLH in humans [3]. This finding strongly suggested aggressive cough control might be important to prevent CLLH in dogs. However, in this case, we could not identify any evidence of tracheal and bronchial collapse. Treatment for CLLH is generally aimed at reducing intrathoracic pressures by aggressive cough control, although surgical correction of CLLH is possible. In this case study, we used prednisolone to reduce swelling of upper airway tract and tramadol to control cough. This therapy was effective enough to prevent further deteriorating of CLLH and respiratory signs.

In conclusion, the CLLH is the protrusion of the cranial lung lobe beyond the thoracic cavity. This case study described a rare case of CLLH in dog, which was identified fluoroscopic study. To author's best knowledge, this is the first case report describing cervical lung lobe herniation in dogs in Korea.

References

1. Coleman MG, Warman CG, Robson MC. Dynamic cervical lung hernia in a dog with chronic airway disease. *J Vet Intern Med* 2005, **19**, 103-105.
2. Guglielmini C, De Simone A, Valbonetti L, Diana A. Intermittent cranial lung herniation in two dogs. *Vet Radiol Ultrasound* 2007, **48**, 227-229.
3. Minai OA, Hammond G, Curtis A. Hernia of the lung: a case report and review of literature. *Conn Med* 1997, **61**, 77-81.
4. Nafe LA, Robertson ID, Hawkins EC. Cervical lung lobe herniation in dogs identified by fluoroscopy. *Can Vet J* 2013, **54**, 955-959.
5. Weaver AD. Severe traumatic pneumothorax and lung prolapse in a Jack Russell bitch. *Vet Rec* 1982, **111**, 505.