

[5]. We experienced a rare case of a huge neurofibroma suspected as a spina bifida on the lumbar level. As neurofibromas have a tendency toward malignant development, preoperative imaging is essential for distinguishing the character of the mass and the existence of metastasis. In addition, ongoing follow-up is critical for such cases.

References

1. Nielsen GP, Stemmer-Rachamimov AO, Ino Y, et al. Malignant transformation of neurofibromas in neurofibromatosis 1 is associated with CDKN2A/p16 inactivation. *Am J Pathol* 1999;155:1879-84.
2. Ergun SS, Emel E, Karabekir S, et al. Extracranial diffuse neurofibroma with intracranial extension. *Plast Reconstr Surg* 2000;105:801-3.
3. Li WY, Reinisch JF. Cysts, pits, and tumors. *Plast Reconstr Surg* 2009;124:106e-116e.
4. Korf BR. Malignancy in neurofibromatosis type 1. *Oncologist* 2000;5:477-85.
5. Clemens MW, Murthy A, Przygodzki RM. Malignant peripheral nerve sheath tumor of the hand. *Plast Reconstr Surg* 2009;123:83e-85e.

A Rare Case of Transitional Meningioma

Joon Hyon Kim, Young Joon Kim, Hoon Kim,
Sang Hyun Nam, Young Woong Choi

Department of Plastic and Reconstructive Surgery, Inje University Sanggye Paik Hospital, Inje University College of Medicine, Seoul, Korea

Correspondence: Young Woong Choi
Department of Plastic and Reconstructive Surgery, Inje University Sanggye Paik Hospital, Inje University College of Medicine, 1342 Dongil-ro, Nowon-gu, Seoul 139-707, Korea
Tel: +82-2-950-1048, Fax: +82-2-932-6373
E-mail: pshero2@naver.com

This article was presented as a poster at the 2nd Research & Reconstructive Forum on June 1-2, 2012 on the Gwangju, Korea.

No potential conflict of interest relevant to this article was reported.

Received: 27 Mar 2014 • Revised: 1 Jun 2014 • Accepted: 9 Jun 2014
pISSN: 2234-6163 • eISSN: 2234-6171
<http://dx.doi.org/10.5999/aps.2015.42.3.375> • Arch Plast Surg 2015;42:375-377
Copyright © 2015 The Korean Society of Plastic and Reconstructive Surgeons
This is an Open Access article distributed under the terms of the Creative Commons Attribution Non-Commercial License (<http://creativecommons.org/licenses/by-nc/3.0/>) which permits unrestricted non-commercial use, distribution, and reproduction in any medium, provided the original work is properly cited.

Meningiomas are a diverse set of tumors arising from the meninges, which are the membranous layers

surrounding the central nervous system. Most meningiomas grow inward toward the brain as discrete, well-defined, dural-based masses and are spherical or lobulated. The borders between the tumor and the brain are usually smooth and clear because they preserve the histologic structures, such as the tumor capsule, cerebrospinal fluid, arachnoid mater, and pia mater [1]. Considering such a growth pattern, we report a rare case of transitional meningioma misdiagnosed as a soft tissue tumor.

A 60-year-old female patient presented with a hard and fixed mass that grew spontaneously on her forehead within one year (Fig. 1). There was no history of trauma or exposure to carcinogens, and she was otherwise fit and well. Computed tomography (CT) showed frontal cortical thickening and swelling suggestive of a type of soft tissue tumor. To determine the character of the tumor-like mass, excision was performed (Fig. 2). The pathologist confirmed the mass as a transitional meningioma. Magnetic resonance imaging (MRI) which was taken after primary excision revealed an intracranial mass that was 3.0 cm in size, ovoid and well enhanced (Fig. 3). Wide-excision osteoplastic craniotomy *via* a bicoronal approach was performed under navigation guidance by neurosurgeon.

Transitional meningiomas are also called as mixed meningiomas, and these tumors have transitional between those of meningothelial and fibrous meningioma and they are common tumors with meningothelial, fibrous, psammomatous, and angioblastic meningiomas. 90% of meningiomas are consisting of those five types of meningiomas. The brain mass was also established as a meningothelial-type meningioma, 2.5 × 2.3 cm in size. Histologically, the tumor was lobulated by intersecting collagenous fibers. Immunohistochemical staining was positive for vimentin and epithelial membrane antigen and

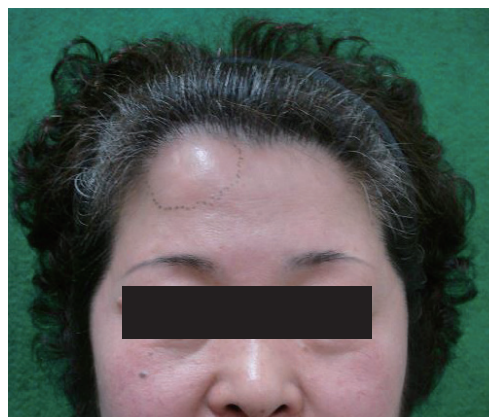

Fig. 1. Preoperative photograph showing a lesion on the right forehead.

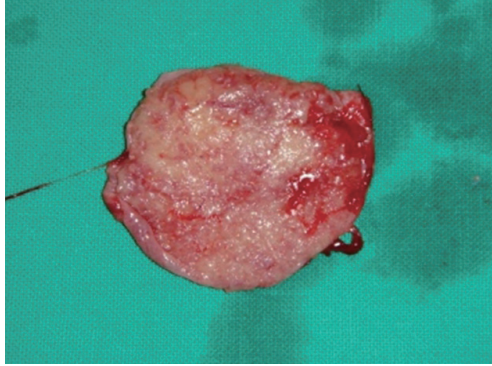


Fig. 2.
Gross appearance of the specimen.

negative for pancytokeratin. There was no recurrence of meningioma during the 6-year follow-up period.

Meningiomas are estimated to constitute between 13% and 26% of primary intracranial tumors, with an annual incidence rate of approximately 6 per 100,000 population. They are the most frequently diagnosed primary brain tumor, accounting for 33.8% of all primary brain and central nervous system tumors reported in the United States between 2002 and 2006 [2]. The exact causes of most of these tumors are not known. They result from abnormal patterns of growth that are most likely due to defects in the genetic material. The exact type of genetic defect or mutation has not been conclusively identified in meningiomas. Despite the lack of definitive evidence that clearly isolates possible causes, it has been suggested that meningiomas are associated with traumatic head injury, prolonged inflammation of the meninges following injury, viral infections, radiation, certain genes, Neurofibromatosis type 2, and hormones, particularly sex hormones, including estrogen, progesterone and androgens. Excessive use of cellular phones has also been implicated as a possible cause, but the evidence to conclusively link cell phone use to meningioma development is lacking [2].

The majority of meningiomas are benign, and they are seldom invasive. Wang et al. [1] studied 7,084 cases of meningiomas and examined the female: male ratio, patient age, subtypes, and locations. The female: male ratio of all types of meningioma is 2.34, while that of transitional meningioma is 2.11. The mean age of among all cases of meningioma is 51.45 years, and that of transitional meningioma is 50.54 years; the age of the patient in this case was 60 years. In their study, there were 323 cases of transitional meningioma among 7,084 cases, accounting for 4.56% of all meningiomas. There were 3 cases of extracranial meningioma among 7,084 cases, accounting for 0.04% of the total. Extracranial

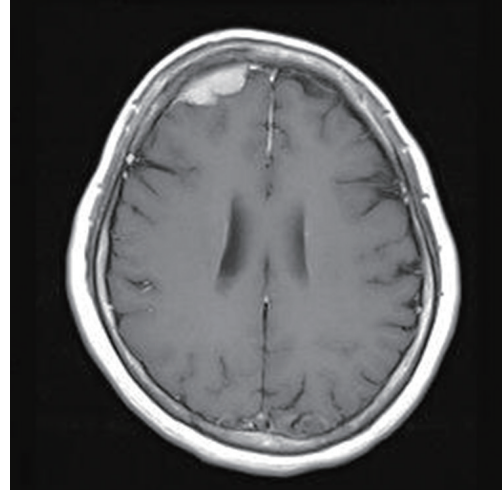


Fig. 3.
Brain magnetic resonance imaging (T1) showing a soft tissue mass 3.0 cm in size, ovoid and well enhanced under the skull. The mass shows a dural tail sign.

extension of meningiomas is very rare, and only a few cases have been reported [1].

Panchmatia et al. [3] reported an asymptomatic forehead lump that was initially diagnosed as an osteoid osteoma. CT was suggestive of an exostosis and an enostosis associated with frontal skull thickening. The mass was excised, and its histological features were consistent with intraosseous meningioma [4]. Nadarajan et al. [4] reported a similar case of unusual meningioma. An 82-year-old man was had a large deformity over the frontal area of his scalp. CT and MRI revealed an intracranial mass that extended across the frontal lobes. The mass permeated the skull and extended through the scalp. The histologic finding of the mass suggested a benign meningioma with low mitotic activity [3].

In cases of a protruding mass on the head, clinicians tend to diagnose the tumor as osteoma or lipoma because of their high prevalence. In this case, the manifestation of the mass was more similar to another soft tissue tumor rather than extracranial meningioma. Following excision, pathology and other radiologic studies such as MRI and ultrasonography indicated that the tumor was a meningioma instead of a soft tissue tumor. The high-power view reveals many whorling epithelioid cells and admixed spindle cells (Fig. 4A).

Immunohistochemical staining for epithelial membrane antigen (EMA) disclosed diffuse positivity, which was strongly supportive of meningotheial differentiation. The tumor cells were

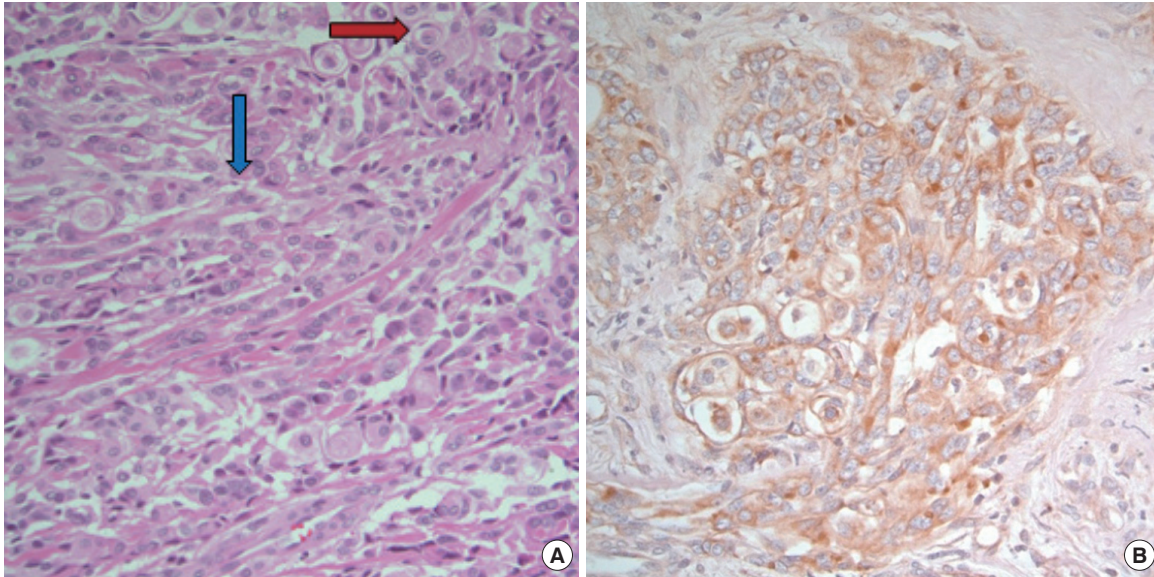


Fig. 4.

(A) The high-power view reveals many whorling epithelioid cells (red arrow) and admixed spindle cells. The tumor cells are composed of oval cells with occasional intranuclear inclusion bodies (blue arrow) (H&E, $\times 400$). (B) Immunohistochemical staining for EMA showing diffuse positivity, which is strongly supportive of meningotheial differentiation (EMA, $\times 400$).

composed of oval cells with occasional intranuclear inclusion bodies (Fig. 4B). To diagnose meningioma, initial investigations should include contrast-enhanced CT and MRI. In addition, angiography is a valuable tool that allows the surgeon to elucidate the relationship of the tumor with nearby vascular structures and to determine the vascularity of the tumor [3].

The meningioma in the present case was misdiagnosed as a soft tissue tumor because of its gross manifestation, and MRI study and punch biopsy were excluded. Unfortunately, nonenhanced brain CT cannot present characteristic feature of meningioma and gives little information to diagnose. The mechanism of extracranial extension was not yet established, but there are two possible theories. One is the proliferation of perineural cells or ectopic arachnoid tissue along the cranial nerve, and the other is misplaced embryonic rests of arachnoid cells and multipotent mesenchymal cells [5].

In conclusion, even if a mass on the forehead has an obvious clinical manifestation, thorough imaging studies are required and suspicions about rare tumors should be addressed before surgery.

References

1. Wang DJ, Xie Q, Gong Y, et al. Histopathological classification and location of consecutively operated meningiomas at a single institution in China from 2001 to 2010. *Chin Med J (Engl)* 2013;126:488-93.
2. Gil-Carcedo LM, Gil-Carcedo ES, Vallejo LA, et al. Frontal osteomas: standardising therapeutic indications. *J Laryngol Otol* 2011;125:1020-7.
3. Panchmatia JR, Arvin B, Thomas DG. Meningioma: an unusual cause of a forehead lump. *Acta Neurochir (Wien)* 2008;150:925-6.
4. Nadarajan V, Goddin J, Luder D, et al. An unusual bump on the head: intraextracranial meningioma presenting incidentally. *BMJ Case Rep* 2012;2012. <http://www.dx.doi.org/10.1136/bcr.03.2012.6134>.
5. Batsakis JG. Pathology consultation. Extracranial meningiomas. *Ann Otol Rhinol Laryngol* 1984;93:282-3.