



Relationship between squamous cell carcinoma of the tongue and the position of dental prosthesis

Huan Fan, Ki-Yong Yoon, Soung-Min Kim, Hoon Myoung*, Jong-Ho Lee, Myung-Jin Kim*

Department of Oral and Maxillofacial Surgery, Dental Research Institute, Seoul National University, Seoul, Republic of Korea

PURPOSE. Squamous cell carcinoma (SCC) of the tongue has a relatively high incidence of all oral cancers. Some studies have reported a relationship between intraoral dental prosthesis and SCC of the tongue; however, this relationship remains controversial. The purpose of this study was to investigate the relationship between SCC of the tongue and the positional aspects of dental prosthesis using a retrospective analysis. **MATERIALS AND METHODS.** A total of 439 patients with SCC of the tongue were diagnosed and treated in the Department of Oral and Maxillofacial Surgery, Seoul National University Dental Hospital. Patients were treated over a 12.5-year period ranging from January 1, 2001 to June 30, 2013. Statistical analysis was performed to examine potential differences between the groups. **RESULTS.** The number of patients with a crown and/or a bridge (134, 63.5%) was significantly different than the number of patients without a prosthesis (77, 36.5%). Even after accounting for different types of prostheses such as crowns, bridges, and dentures, no significant differences were observed between the position of the prosthesis and the location of the SCC of the tongue, with significance defined as a *P*-value less than .05 by the Pearson-Chi square test. **CONCLUSION.** Patients with crowns and/or bridges exhibited more frequent SCC of the tongue compared with patients without these prosthesis. These data support the hypothesis that mechanical trauma and galvanic phenomena play a role in the etiology of SCC of the tongue.

[J Adv Prosthodont 2015;7:129-37]

KEY WORDS: Squamous cell carcinoma (SCC) of the tongue; Dental prosthesis; Location relationship

INTRODUCTION

Oral and oropharyngeal cancers, including cancers of the lip, alveolar bone, gingiva, buccal mucosa, floor of the

mouth, oropharynx, salivary glands, maxillary sinus, and mobile tongue, are the sixth most common type of cancer in the world.^{1,2} Oral cancer accounts for 3% of all cancers in the United States with over 40,000 new cases each year and over 12,000 deaths annually. All the cases of oral cancer, 90% are squamous cell carcinomas (SCCs); moreover, 95% of these patients are older than 40 years of age, with an average age at diagnosis of 60 years. SCC of the tongue is usually observed in males between 40-50 years of age.³⁻⁵ SCC of the tongue has an incidence of 40-50% in oral and maxillofacial cancers; moreover, SCC of the tongue is associated with various complications such as difficulty of speech, swallowing, and mastication; poor nutrition; and a high risk of nerve damage after surgical resection or radiation therapy.² To date, various risk factors for SCC of the tongue have been identified, such as age, tobacco status, alcohol consumption, and human papilloma virus (HPV) infection.⁶⁻⁹ Furthermore, nutritional deficiency and poor oral hygiene with maligned dentition have been identified as causative factors.¹⁰⁻¹²

Corresponding author:
Hoon Myoung and Myung-Jin Kim
Department of Oral and Maxillofacial Surgery, School of Dentistry, Seoul National University, 62-1 Changgyeonggungno, Jongno-gu, Seoul 110-768, Republic of Korea
Tel. 82 2 2072 3059, 2632; e-mail, myoung@snu.ac.kr, myungkim@snu.ac.kr
Received July 14, 2014 / Last Revision January 28, 2015 / Accepted February 5, 2015

© 2015 The Korean Academy of Prosthodontics
This is an Open Access article distributed under the terms of the Creative Commons Attribution Non-Commercial License (<http://creativecommons.org/licenses/by-nc/3.0>) which permits unrestricted non-commercial use, distribution, and reproduction in any medium, provided the original work is properly cited.

* These two authors contributed their own works as the corresponding author.

** This study was supported by grant No 03-2010-0021 from the SNUHD Research Fund.

The relationship between dental prosthesis and SCC of the tongue remains controversial, although it has been proposed that chronic irritation or direct trauma to the oral mucosa resulting from dental prostheses can increase the risk of SCC of the tongue. One global epidemiological study, which focused on factors that contribute to SCC of the tongue, showed that ill-fitted prosthesis is a primary cause of oral cancer in groups with certain geographical characteristics and socioeconomic statuses.¹³

Therefore, the purpose of this retrospective study was to investigate the relationship between SCC of the tongue and dental prosthesis, including positional aspects.

MATERIALS AND METHODS

A total of 439 patients with SCC of the tongue were diagnosed and treated in the Department of Oral and Maxillofacial Surgery, Seoul National University Dental Hospital. Patients were treated over a 12.5-year period from January 1, 2001 to June 30, 2013 and were managed by four maxillofacial surgeons specializing in oral cancer, along with their reconstruction teams. Among the 439 diagnosed patients, 211 satisfied the inclusion criteria for this study. These criteria included a pathologic diagnosis of malignancy in the tongue, the availability of clinical information regarding intraoral prosthesis, and panoramic radiograph data revealing the type and location of the prosthesis.

These 211 patients were categorized according to sex, age, position and type of prosthesis, and primary location of the tongue malignancy. This study protocol was fully approved by the Institutional Review Board of Seoul National University Dental Hospital. Most patients exhibited advanced stage III or IV cancer and received a radical, combined-modality treatment regimen consisting of chemotherapy, surgery, and/or radiotherapy. Patients' clinical and demographic information, such as age, sex, tobacco history, previous cancer therapy, specific primary site in the tongue, histological diagnosis, and tumor staging data,

including T (tumor size), N (nodal), and M (metastatic) staging, were collected.

A thorough dental history was reviewed for each patient. This history included the frequency and presence of prosthesis, such as fixed or partial dentures. The inclusion criteria for this study were as follows: (1) diagnosed with both clinical and pathological malignancy of the tongue; (2) available clinical information regarding dentition and previous treatment; (3) available panoramic radiographs for identifying the types and locations of the prostheses. Exclusion criteria included: (1) diagnosed with clinical or pathological malignancy of the tongue; and (2) insufficient clinical and panoramic information for identifying the type and location of prosthesis.

Patients were categorized according to the following variables:

- (1) Sex
- (2) Age (0-19 years, 20-29 years, 30-39 years, 40-49 years, 50-59 years, 60-69 years, and older than 70 years)
- (3) Position of crown and/or bridge (Fig. 1)
 - Group 0: no crown or bridge
 - Group 1: right molar area (from the right first premolar to the right third molar)
 - Group 2: anterior teeth area (from the right canine to the left canine)
 - Group 3: left molar area (from the left first premolar to the left third molar)
 - Group 4: bilateral molar area
 - Group 5: right molar and anterior teeth areas
 - Group 6: anterior teeth and left molar areas
 - Group 7: right molar, anterior teeth and left molar areas
- (4) Position of dentures (maxilla, mandible, or both)
- (5) Location of SCC of the tongue [right border (type a), left border (type b), bilateral borders (type c), and other location (type d)¹⁴]

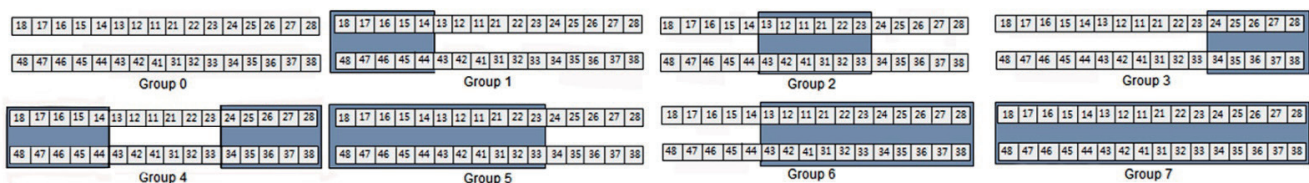


Fig. 1. Group classification according to the tooth positions of crowns and bridges used in this study. Tooth numbers are in accordance with the FDI (Federation Dentaire Internationale) system.

Group 0: no crown or bridge, Group 1: right molar area (from the right first premolar to the right third molar), Group 2: anterior teeth area (from the right canine to the left canine), Group 3: left molar area (from the left first premolar to the left third molar), Group 4: bilateral molar area, Group 5: right molar and anterior teeth areas, Group 6: anterior teeth and left molar areas, Group 7: right molar, anterior teeth, and left molar areas.

Univariate analyses were performed using the Pearson Chi-square test, Student's *t*-test, and one-way analysis of variance in SPSS for Windows, version 12. Analyses were performed in two different ways, frequency analysis and cross analysis. *P* values less than 0.05 were considered to be statistically significant. Frequency analysis was conducted to determine the relationships of SCC of the tongue with patient sex, age, location, type of prosthesis (crown and/or bridge), and prosthesis position. Cross analysis was also conducted to analyze possible relationships between the location of the SCC of the tongue and the presence of a crown and/or a bridge, the position of each prosthesis, and the presence of other removable dentures.

RESULTS

Among the 439 patients initially identified, 62 lacked sufficient clinical information for inclusion, and 166 patients were not diagnosed with a tongue lesion that was both clinically and pathologically malignant; thus, these 228 patients were excluded. The data from the remaining 211 patients, including their panoramic radiographs, clinical chart records, and pathological diagnoses, were reviewed and compared. Frequency analyses of these data are shown in Table 1.

Of the 211 patients included in the study, 80 (37.9%) were female and 131 (62.1%) were male. The mean patient age was 54.9 years; the age bracket with the most patients was 50-59 years (60 patients, 28.4%), followed by 60-69 years (40 patients, 19.0%), 70 years and above (40 patients,

19.0%), 40-49 years (33 patients, 15.6%), 30-39 years (27 patients, 12.8%), and less than 20 years (11 patients, 5.2%). Regarding the location of SCC of the tongue, 104 patients (49.3%) had a lesion located on the right lateral border of the tongue, and 93 patients (44.1%) had a lesion on the left lateral border (Table 2). The distribution of prostheses included 134 patients (63.5%) with at least one prosthesis and 77 patients (36.5%) without a prosthesis; this difference was statistically significant ($P < .05$). Fewer patients had a crown (91, 43.1%) than did not have a crown (120, 56.9%); similarly, fewer patients had a bridge (99, 46.9%) than did not have a bridge (112, 53.1%). The number of patients with both a crown and a bridge was 56 (41.8%) (Table 3).

Regarding the position of the crown and/or the bridge, group 7 had the most patients (43, 20.4%) followed by group 4 (33, 15.6%), and group 1 (19, 9.0%); regarding the location of the crown, group 1 had the most patients (29, 13.7%) followed by group 4 (21, 10.0%); regarding the location of the bridge, each group showed similar frequencies except group 7 (31, 14.7%) (Table 4). Of the patients included in the study, 73 (34.6%) wore dentures; 47 of those had both upper and lower dentures, a 22.3% overall frequency (Table 5).

Table 1. Frequencies of patients with squamous cell carcinoma of the tongue according to the year of initial diagnosis

| Year | Patients (n) | Percentage (%) |
|-------------------|--------------|----------------|
| 2001 | 16 | 7.6 |
| 2002 | 6 | 2.8 |
| 2003 | 2 | 0.9 |
| 2004 | 2 | 0.9 |
| 2005 | 6 | 2.8 |
| 2006 | 27 | 12.8 |
| 2007 | 27 | 12.8 |
| 2008 | 8 | 3.8 |
| 2009 | 35 | 16.6 |
| 2010 | 16 | 7.6 |
| 2011 | 40 | 19.0 |
| 2012 | 16 | 7.6 |
| 2013 (until 6/30) | 10 | 4.7 |
| Total | 211 | 100.0 |

Table 2. Location frequencies of squamous cell carcinoma lesions of the tongue

| Location (Type*) | Patients (n) | Percentage (%) |
|------------------|--------------|----------------|
| a | 104 | 49.3 |
| b | 93 | 44.1 |
| c | 1 | 0.5 |
| d | 13 | 6.2 |
| Total | 211 | 100.0 |

* Squamous cell carcinoma lesions of tongue were categorized as right border (type a), left border (type b), bilateral borders (type c), and other location (type d).

Table 3. Frequencies of prosthesis types in patients with squamous cell carcinoma of the tongue

| Type | Frequency (n) | Percentage (%) |
|------------------|---------------|----------------|
| None | 77 | 36.5 |
| Crown | 35 | 16.6 |
| Bridge | 43 | 20.4 |
| Crown and bridge | 56 | 26.5 |
| Total | 211 | 100.0 |

Table 4. Frequencies of crown/bridge locations in patients with squamous cell carcinoma of the tongue

| Group | Crown or bridge | | Crown | | Bridge | |
|-------|-----------------|----------------|---------------|----------------|---------------|----------------|
| | Frequency (n) | Percentage (%) | Frequency (n) | Percentage (%) | Frequency (n) | Percentage (%) |
| 0 | 77 | 36.5 | 120 | 56.9 | 112 | 53.1 |
| 1 | 19 | 9.0 | 29 | 13.7 | 12 | 5.7 |
| 2 | 11 | 5.2 | 7 | 3.3 | 19 | 9.0 |
| 3 | 10 | 4.7 | 19 | 9.0 | 6 | 2.8 |
| 4 | 33 | 15.6 | 21 | 10.0 | 13 | 6.2 |
| 5 | 10 | 4.7 | 2 | 0.9 | 10 | 4.7 |
| 6 | 8 | 3.8 | 6 | 2.8 | 8 | 3.8 |
| 7 | 43 | 20.4 | 7 | 3.3 | 31 | 14.7 |
| Total | 211 | 100.0 | 211 | 100.0 | 211 | 100.0 |

Table 5. Frequencies of denture locations in patients with squamous cell carcinoma of the tongue

| Location | Frequency (n) | Percentage (%) |
|----------------------|---------------|----------------|
| None | 138 | 65.4 |
| Maxilla | 17 | 8.1 |
| Mandible | 9 | 4.3 |
| Maxilla and mandible | 47 | 22.3 |
| Total | 211 | 100.0 |

Cross analysis was performed to investigate possible relationships between the location of the lesion and the presence of a prosthesis (Table 6), the location of the lesion and the position of the crown and/or bridge (Table 7), the location of the lesion and the presence of a prosthe-

sis (Table 8), and the location of the lesion and the position of dentures (Table 9). No significant relationship was observed between the presence of a prosthesis and the location of the lesion ($P=.723$); thus, it is still unclear why patients with a crown and/or bridge have more frequent SCC of the tongue compared with patients without prostheses. Moreover, no significant association was observed between the presence of a crown and/or bridge and the location of the lesion ($P=.230$), the presence of a crown alone and the location of the lesion, or the presence of a bridge alone and the location of the lesion ($P=.674$ and 0.066 , respectively). Regarding the position of a prosthesis, no significant relationship was observed between the position of a crown and location of the lesion ($P=.071$) or between the position of a bridge and location of the lesion ($P=.716$). Similarly, the location of the lesion was not significantly associated with the presence of dentures ($P=.409$), and the position of dentures was not associated with location of the lesion ($P=.073$).

Table 6. Cross analysis of the relationship between lesion location and presence of a crown/bridge

| Crown/bridge | | Location of the lesion | | | | Total n (%) |
|-----------------|---------|------------------------|-----------------|-----------------|-----------------|----------------|
| | | Type a n (%) | Type b n (%) | Type c n (%) | Type d n (%) | |
| Crown or bridge | None | 43 (55.8%) | 32 (41.6%) | 0 (0.0%) | 2 (2.6%) | 77 (100.0%) |
| | Present | 61 (45.5%) | 61 (45.5%) | 1 (0.7%) | 11 (8.2%) | 134 (100.0%) |
| | Total | 104 (49.3%) | 93 (44.1%) | 1 (0.5%) | 13 (6.2%) | 211 (100.0%) |
| Bridge | None | 61 (54.5%) | 48 (42.9%) | 0 (0.0%) | 3 (2.7%) | 112 (100.0%) |
| | Present | 43 (43.4%) | 45 (45.5%) | 1 (1.0%) | 10 (10.1%) | 99 (100.0%) |
| | Total | 104 (49.3%) | 93 (44.1%) | 1 (0.5%) | 13 (6.2%) | 211 (100.0%) |
| Crown | None | 61 (50.8%) | 52 (43.3%) | 0 (0.0%) | 7 (5.8%) | 120 (100.0%) |
| | Present | 43 (47.3%) | 41 (45.1%) | 1 (1.1%) | 6 (6.6%) | 91 (100.0%) |
| | Total | 104 (49.3%) | 93 (44.1%) | 1 (0.5%) | 13 (6.2%) | 211 (100.0%) |

$P=.230$ (crown or bridge), 0.066 (bridge), 0.674 (crown).

Table 7. Cross analysis to determine the relationship between lesion location and position of the crown/bridge

| Position of crown/bridge | | Location of the lesion | | | | Total n (%) |
|--------------------------|---------|------------------------|-----------------|-----------------|-----------------|----------------|
| | | Type a n (%) | Type b n (%) | Type c n (%) | Type d n (%) | |
| Crown or bridge | Group 1 | 9 (47.4%) | 9 (47.4%) | 0 (0.0%) | 1 (5.3%) | 19 (100.0%) |
| | Group 2 | 4 (36.4%) | 6 (54.5%) | 0 (0.0%) | 1 (9.1%) | 11 (100.0%) |
| | Group 3 | 6 (60.0%) | 3 (30.0%) | 0 (0.0%) | 1 (10.0%) | 10 (100.0%) |
| | Group 4 | 12 (36.4%) | 19 (57.6%) | 0 (0.0%) | 2 (6.1%) | 33 (100.0%) |
| | Group 5 | 2 (20.0%) | 7 (70.0%) | 0 (0.0%) | 1 (10.0%) | 10 (100.0%) |
| | Group 6 | 4 (50.0%) | 2 (25.0%) | 0 (0.0%) | 2 (25.0%) | 8 (100.0%) |
| | Group 7 | 24 (55.8%) | 15 (34.9%) | 1 (2.3%) | 3 (7.0%) | 43 (100.0%) |
| | Total | 61 (45.5%) | 61 (45.5%) | 1 (0.7%) | 11 (8.2%) | 134 (100.0%) |
| Bridge | Group 1 | 5 (41.7%) | 6 (50.0%) | 0 (0.0%) | 1 (8.3%) | 12 (100.0%) |
| | Group 2 | 8 (42.1%) | 10 (52.6%) | 0 (0.0%) | 1 (5.3%) | 19 (100.0%) |
| | Group 3 | 3 (50.0%) | 3 (50.0%) | 0 (0.0%) | 0 (0.0%) | 6 (100.0%) |
| | Group 4 | 3 (23.1%) | 8 (61.5%) | 0 (0.0%) | 2 (15.4%) | 13 (100.0%) |
| | Group 5 | 3 (30.0%) | 6 (60.0%) | 0 (0.0%) | 1 (10.0%) | 10 (100.0%) |
| | Group 6 | 2 (25.0%) | 4 (50.0%) | 0 (0.0%) | 2 (25.0%) | 8 (100.0%) |
| | Group 7 | 19 (61.3%) | 8 (25.8%) | 1 (3.2%) | 3 (9.7%) | 31 (100.0%) |
| | Total | 43 (43.4%) | 45 (45.5%) | 1 (1.0%) | 10 (10.1%) | 99 (100.0%) |
| Crown | Group 1 | 14 (48.3%) | 15 (51.7%) | 0 (0.0%) | 0 (0.0%) | 29 (100.0%) |
| | Group 2 | 2 (28.6%) | 4 (57.1%) | 0 (0.0%) | 1 (14.3%) | 7 (100.0%) |
| | Group 3 | 9 (47.4%) | 7 (36.8%) | 0 (0.0%) | 3 (15.8%) | 19 (100.0%) |
| | Group 4 | 11 (52.4%) | 9 (42.9%) | 0 (0.0%) | 1 (4.8%) | 21 (100.0%) |
| | Group 5 | 1 (50.0%) | 0 (0.0%) | 0 (0.0%) | 1 (50.0%) | 2 (100.0%) |
| | Group 6 | 4 (66.7%) | 2 (33.3%) | 0 (0.0%) | 0 (0.0%) | 6 (100.0%) |
| | Group 7 | 2 (28.6%) | 4 (57.1%) | 1 (14.3%) | 0 (0.0%) | 7 (100.0%) |
| | Total | 43 (47.3%) | 41 (45.1%) | 1 (1.1%) | 6 (6.6%) | 91 (100.0%) |

$P=.723$ (crown or bridge), 0.716 (bridge), 0.071 (crown).

Table 8. Cross analysis to determine the relationship between lesion location and presence of a denture

| Denture | Location of the lesion | | | | Total n (%) |
|---------|------------------------|-----------------|-----------------|-----------------|----------------|
| | Type a n (%) | Type b n (%) | Type c n (%) | Type d n (%) | |
| None | 66 (47.8%) | 62 (44.9%) | 0 (0.0%) | 10 (7.2%) | 138 (100.0%) |
| Present | 38 (52.1%) | 31 (42.5%) | 1 (1.4%) | 3 (4.1%) | 73 (100.0%) |
| Total | 104 (49.3%) | 93 (44.1%) | 1 (0.5%) | 13 (6.2%) | 211 (100.0%) |

$P=.409$.

Table 9. Cross analysis to determine the relationship between lesion location and denture position

| Position of denture | Location of the lesion (type) | | | | Total |
|----------------------|-------------------------------|------------|----------|-----------|--------------|
| | a | b | c | d | |
| None | 66 (47.8%) | 62 (44.9%) | 0 (0.0%) | 10 (7.2%) | 138 (100.0%) |
| Maxilla | 11 (64.7%) | 5 (29.4%) | 1 (5.9%) | 0 (0.0%) | 17 (100.0%) |
| Mandible | 5 (55.6%) | 3 (33.3%) | 0 (0.0%) | 1 (11.1%) | 9 (100.0%) |
| Maxilla and mandible | 22 (46.8%) | 23 (48.9%) | 0 (0.0%) | 2 (4.3%) | 47 (100.0%) |
| Total | 104 (49.3%) | 93 (44.1%) | 1 (0.5%) | 13 (6.2%) | 211 (100.0%) |

$P=.073$

DISCUSSION

Oral SCC is commonly observed in the tongue, lip, gingival tissue, palate, and floor of the mouth.¹⁵ SCC of the buccal mucosa is common among Asian populations due to cultural betel quid and tobacco chewing habits; for instance, 40% of all oral cancers in Sri Lanka are found on the buccal mucosa.^{1,9}

The tongue is the most common site of oral cancer among European and US populations and accounts for 40-50% of all oral cancers.^{1,15} Many contributing factors of SCC of the tongue have been identified, and SCC of the tongue is believed to be a multifactorial condition.^{9,16} Alcohol and tobacco have been hypothesized to exert their carcinogenic effects via a contact mechanism; for example, tobacco smoking is more strongly associated with tongue cancer when patients have been heavily exposed to inhaled smoke. On the other hand, alcohol consumption exerts a stronger effect on structures belonging to the food channel and reservoir systems, such as the tongue. This explanation is consistent with studies in animal models that have investigated the effect of ethanol on the mucosal penetration of nitrosonornicotine in the oral mucosa. The detection of DNA from HPV subtypes 6 and 16 in exfoliated oral cavity cells has been shown to be strongly associated with an elevated risk for tongue cancer; moreover, DNA-based studies of HPV isolates found in exfoliated oral tissue from case subjects showed that HPV types 16, 18, 31, 33, and 35 were the most common. However, a definitive association between tongue cancer risk and the detection of high-risk HPV types has not yet been proven.^{1,15,16}

This study was conducted to identify contributing factors in tongue cancer. The patients in this study exhibited a similar clinical/demographic distribution, including sex, age, and primary tumor site of the tongue, as has been observed in other studies of oral cancer patients. Of the patients in the study, 62.1% were male and 28.4% were female, the mean patient age was 54.9 years, and patients aged 50-59 years old were the most prevalent. No suitable studies were available against which to compare the presence and locations of intraoral prostheses. This study did have a few disadvantages; for example, the duration of the intraoral prosthesis was not included, the study did not examine whether patients received prosthetic treatment by professionals, and the study did not examine marginal adaptation to the prosthesis. Additionally, the raw materials of the dental prostheses were not examined in this study. To fully investigate the possible relationships between dental prosthesis and SCC of the tongue, more extensive data need to be obtained from patients with SCC of the tongue, and prospective studies focusing on the physical properties of these prostheses and their biochemical influences on the tongue should be performed.

Cross analysis did not reveal any significant association between location of the prosthesis and SCC of the tongue. However, the number of patients with a crown and/or a bridge (134, 63.5%) was significantly different from the

number of patients without prosthesis (77, 36.5%). These retrospective findings suggest that any prosthetic margin, crown surface, or bridge surface is capable of inflicting mechanical irritation on the tongue, and that these irritations may contribute to the development of SCC of the tongue. People who wear dentures are known to have a higher prevalence of oral mucosal lesions compared with people who do not wear dentures, crowns, or bridges; these oral mucosal lesions can develop into malignancies in the oral cavity. Among people who wear dentures, those who wear complete dentures have been shown to have a higher incidence of lesions compared with people who wear partial dentures.¹⁷ Oral cancer can also be observed in the contact area between the teeth and the prosthesis; in particular, tongue malignancies of the lateral border have been observed opposite from the flange extension of the lower denture.¹⁸ Another related study found that metallurgically-flawed gold crowns contribute to SCC of the tongue.¹⁹

However, these findings are controversial. Other studies have found no correlation between denture wearing and oral malignancies,²⁰ denture type and oral mucosal lesions, or the use of dentures and SCC of the tongue.^{21,22} Lockhart *et al.*¹⁸ observed 28 intraoral malignancies in the contact area of either the teeth or prosthetic appliances; moreover, all 10 patients with SCC of the tongue were associated with a flange extension of a lower denture. Kinnebrew *et al.*¹⁹ reviewed a case of a 25-year-old woman with SCC of the tongue and concluded that the lesion was physically associated with a metallurgically-flawed gold crown that had been used for 15 years. However, Albuquerque *et al.*²² concluded that dentures are not an etiologic factor for SCC of the tongue, since no definitive association between SCC of the tongue and denture use was demonstrated. Furthermore, Jankittivong *et al.*¹⁷ reported that no association was found between pathologic conditions of the intraoral mucous membrane and denture type.

Physical trauma has been proposed to act as a contributing factor that could determine the location of oral cancer, which may explain a possible relationship between trauma and cancer location. Inflammatory reactions in the oral cavity induced by either dental trauma or physical irritation have been considered to be important contributing factors for oral cancer. In support of this hypothesis, inflammatory changes in the thin atrophic mucous membrane have been observed.²³ Many other possible relationships have been proposed, but these relationships have not yet been confirmed.

Chronic trauma is frequently found in people who wear dentures, and other pathological conditions associated with the use of dentures such as Candida-induced denture stomatitis, denture-related hyperplasia, angular cheilitis, and traumatic ulcers are known to be related to SCC of the tongue. Unfortunately, this retrospective study did not investigate the presence of premalignant lesions in the patients. However, ulcerations of the tongue caused by chronic trauma resulting from poorly fabricated dentures, fractured restorations, sharp edges on worn teeth, and ill-

fitting crowns and/or bridges were confirmed in most cases. The tongue mucosa is thought to be more permeable to noxious substances and therefore more vulnerable to external carcinogens. Moreover, the mucosal epithelium of the tongue becomes thinner with age, and the rate of collagen synthesis by connective tissue also decreases.

Regarding trauma, chronic irritations caused by ill-fitted dentures, fractured restorations, and other erosive factors can alter the tongue mucosa. Together with other factors such as alcohol and tobacco, these factors may lead to the development of oral cancer. Some studies have reported that SCC in the anterior two-thirds of the tongue is often accompanied by local traumatic irritation. Clearly, many people with years of chronic mucosal irritation from a dental or prosthetic source do not develop cancer. However, our study suggests that, of the people who do develop cancer, a high percentage of these cancers will arise in areas that are in direct contact with teeth and appliances. Neither this study investigate the quality of the prostheses such as marginal discrepancy of crown, the duration of prostheses, or quality of occlusion, and no significant differences were observed between the position of the prosthesis and the location of the SCC of the tongue. These results may only support the hypothesis that mechanical trauma is the cause of SCC of the tongue.

One of the possible precancerous conditions for SCC is leukoplakia.²⁴ Earlier studies have indicated that oral galvanism is a contributing factor for oral leukoplakia, and that the removal of the metal prosthesis resulted in the resolution of the leukoplakia.²⁵ Oral galvanism can be generated by the presence of more than two adjacent metal prostheses, which can introduce current flow.²⁶ The intraoral electrical phenomenon of galvanism could increase the proliferation of leukoplakia cells, induce apoptosis, and simulate some morphological features of SCC. This galvanic current, which affects ornithine decarboxylase, is upregulated in many cancers, which is important because the Na^+K^+ -ATPase acts as an ion transporter.²⁵

Electrical actions from prosthetic metal materials of crowns and/or bridges should be considered an important etiologic factor of SCC of the tongue. Although the currents generated are minute, they can form a type of weak battery. Over time, this electrical battery can result in irritating injury to the tongue mucosa and the surrounding muscles.

Galvanic current is a type of miniature battery formed by electric circuits resulting from the presence of dissimilar metals in the mouth. Prosthetic metals, such as gold, silver, copper, and mercury, show different electrical potentials in the aqueous saliva of the oral cavity. Thus, if two dissimilar prostheses are placed in the mouth, a simple galvanic battery, called an electromotive series, will be formed.²⁶ As the tongue moves, the positions of the two metals (one above and the other below, one on the left and the other on the right, or one in an anterior location and the other in a posterior location) constitute a new electrolyte, resulting in peculiar taste perceptions. If these metals are connected externally, electric current flows from one metal to another

by means of an external conductor circuit. The mobile tongue mucosa is a good conductor, and saliva can be considered a solution composed of several electrolytes. Therefore, prosthetic metal, when it is bathed in saliva and placed near a tongue conductor, forms a simple galvanic battery in the oral cavity.

This electrical action of prosthetic metals has been proposed to be one of the main contributing factors to SCC of the tongue. Three different aspects - galvanometer measurement, local action, and polarization - have been proposed as mechanisms through which the electrical actions contribute to SCC of the tongue.²⁶

Firstly, galvanometer measurements of metals in situ have been shown to have a relationship with some accompanying pathologic changes. An oral cavity with more than one metallic restoration can conduct currents ranging as high as 80 microamperes, with the exception of an oral cavity containing only fillings of 24-carat gold. The value of the current dropped within five seconds to a steady minimum, which was approximately 10% of the initial value, when the contactors were held in place for an appreciable length of time. Both high and low values were obtained in oral cavities with pathologic lesions; these values were not significantly different from those obtained in mouths with no untoward symptoms. Subsurface porosity in the vicinity of the discoloration, accompanied by a thin, silvery surface layer of gold, was found in the metallurgic study. Peaks of copper, gold, silver, and palladium were also examined in the interior and on the surface of a crown. The elements identified on the discolored surface of the crown were copper, silicon, chlorine, silver, and gold. However, much more silver and much less gold were identified on the discolored surface compared with the interior of the crown. The discolored surface of the crown was found to be high in silver solder (AgCu) or to contain gold solder with a high silver content. The resultant corrosion products of silver, revealed by the chlorine and silver peaks, suggest that electrogalvanism had occurred. This electrogalvanism promotes chronic galvanism.

The second relevant finding is that metal alloys have local actions and induce pathological changes. Copper and gold alloys are physical mixtures of separate and distinct crystals. When these crystals coexist on the surface of a restoration, potential differences will exist between the crystals and the saliva, thereby constituting a miniature galvanic cell. In this instance, the external circuit is the restoration itself, and the internal circuit is completed by the saliva and related soft tissues. Any white mucosal lesions, such as leukoplakia, can be produced by this local action effect. Similar to the manner in which nickel dermatitis can be caused by wrist watches and spectacle frames, the nickel found in white gold alloys has an electrolytic battery action when it is in contact with dissimilar metals and an acid or an alkaline fluid. When an electrolyte perspires and acts upon the base, metal salts are formed. Moreover, such action is more pronounced in the presence of heat. Nickel salts cause irritations where the metal comes in contact

with the skin.

The third important finding related to galvanic currents is that of polarization. Polarization is present in the oral cavity immediately after restorations are inserted and is manifested by a reduction in the normal current. This polarization phenomenon is also known to cause a metallic taste, which is noticeable immediately after the insertion of a restoration and disappears shortly afterward. The presence of continuous or intermittent depolarizing agents can permit current to flow, resulting in damage to the tongue mucosa. These lesions can be traced to electrical causes; however, galvanometer readings bear no relation to the normal current flow in these cases. Moreover, current does not normally flow between restorations; this observation is consistent with the resistance of metals to wear. Electrical energy is produced at the expense of one of the electrodes in an ordinary battery. If currents on the order of those of a normal battery were flowing between restorations, some of the restorations would be eroded over the course of several years.^{25,26}

Among the present patients with SCC of the tongue, 63.5% more had a crown or a bridge compared with the number of patients without prosthesis. We investigated the cause of this difference but did not find any significant association between these prostheses and location of the lesion ($P=.723$). However, the precise relationship between dental prostheses and SCC of the tongue remains controversial. We did not classify dental materials used in prostheses in this study. Therefore, we could not conclude that prostheses and galvanic phenomena play a major role in the etiology of SCC of the tongue. Also, the biochemical effects of oral prostheses and their contributions to SCC of the tongue need to be addressed in future studies.

Finally, early diagnosis remains a key element for adequate therapy of oral SCC, including SCC of the tongue. Clinicians should be aware that single ulcers, tumors, red plaques, or white plaques, particularly if any of these persist for more than two weeks, may be manifestations of malignancy. In these cases, a prompt biopsy of the suspicious lesion should be performed.²⁷ Moreover, the entire oral cavity, including the tongue, should be routinely examined in all patients with any prostheses.

CONCLUSION

This clinical retrospective study included a statistical analysis of 211 patients with SCC of the tongue and investigated whether SCC of the tongue is associated with the positional aspects of dental prostheses. The data below strongly support the hypothesis that mechanical trauma and the galvanic phenomenon play a role in the etiology of SCC of the tongue.

Male patients showed a higher incidence of SCC of the tongue compared with female patients; patients with SCC of the tongue were most likely to be 50-59 years of age. No relationship between location of the dental prosthesis and the presence of SCC of the tongue was observed. No sig-

nificant associations between the position of a prosthesis and location of SCC of the tongue were observed. More patients with SCC of the tongue had a crown and/or a bridge than did not have a prosthesis. Physical trauma from ill-fitted prostheses is expected to be a main causative factor of SCC of the tongue. The galvanic phenomenon arising from dissimilar prosthetic metals is also expected to be another factor contributing to SCC of the tongue; this phenomenon is composed of pathologic changes, local actions, and the polarization effect.

ORCID

Huan Fan <http://orcid.org/000-0002-2654-1329>

REFERENCES

1. Warnakulasuriya S. Global epidemiology of oral and oropharyngeal cancer. *Oral Oncol* 2009;45:309-16.
2. Kolokythas A. Long-term surgical complications in the oral cancer patient: a comprehensive review. Part I. *J Oral Maxillofac Res* 2010;1:e1.
3. Byers RM. Squamous cell carcinoma of the oral tongue in patients less than thirty years of age. *Am J Surg* 1975;130:475-8.
4. Jones JB, Lampe HB, Cheung HW. Carcinoma of the tongue in young patients. *J Otolaryngol* 1989;18:105-8.
5. Llewellyn CD, Johnson NW, Warnakulasuriya KA. Risk factors for squamous cell carcinoma of the oral cavity in young people—a comprehensive literature review. *Oral Oncol* 2001;37:401-18.
6. Mashberg A, Boffetta P, Winkelmann R, Garfinkel L. Tobacco smoking, alcohol drinking, and cancer of the oral cavity and oropharynx among U.S. veterans. *Cancer* 1993;72:1369-75.
7. Boffetta P, Mashberg A, Winkelmann R, Garfinkel L. Carcinogenic effect of tobacco smoking and alcohol drinking on anatomic sites of the oral cavity and oropharynx. *Int J Cancer* 1992;52:530-3.
8. Schwartz SM, Daling JR, Doody DR, Wipf GC, Carter JJ, Madeleine MM, Mao EJ, Fitzgibbons ED, Huang S, Beckmann AM, McDougall JK, Galloway DA. Oral cancer risk in relation to sexual history and evidence of human papillomavirus infection. *J Natl Cancer Inst* 1998;90:1626-36.
9. Laronde DM, Hislop TG, Elwood JM, Rosin MP. Oral cancer: just the facts. *J Can Dent Assoc* 2008;74:269-72.
10. Preston-Martin S, Henderson BE, Pike MC. Descriptive epidemiology of cancers of the upper respiratory tract in Los Angeles. *Cancer* 1982;49:2201-7.
11. Cox B, Taylor K, Treasure E. Trends in oral cancer by subsite in New Zealand. *Eur J Cancer B Oral Oncol* 1995;31B:113-7.
12. Macfarlane GJ, Sharp L, Porter S, Franceschi S. Trends in survival from cancers of the oral cavity and pharynx in Scotland: a clue as to why the disease is becoming more common? *Br J Cancer* 1996;73:805-8.
13. Moore SR, Johnson NW, Pierce AM, Wilson DF. The epidemiology of tongue cancer: a review of global incidence. *Oral Dis* 2000;6:75-84.

14. Miyamoto S, Sakuraba M, Nagamatsu S, Kayano S, Kamizono K, Hayashi R. Risk factors for gastric-tube dependence following tongue reconstruction. *Ann Surg Oncol* 2012;19:2320-6.
15. Markopoulos AK. Current aspects on oral squamous cell carcinoma. *Open Dent J* 2012;6:126-30.
16. Goldstein DP, Irish JC. Head and neck squamous cell carcinoma in the young patient. *Curr Opin Otolaryngol Head Neck Surg* 2005;13:207-11.
17. Jaikittivong A, Aneksuk V, Langlais RP. Oral mucosal conditions in elderly dental patients. *Oral Dis* 2002;8:218-23.
18. Lockhart PB, Norris CM Jr, Pulliam C. Dental factors in the genesis of squamous cell carcinoma of the oral cavity. *Oral Oncol* 1998;34:133-9.
19. Kinnebrew M, Gittleman L, Carr RF, Beazley R. Squamous cell carcinoma of the tongue in a young woman. Report of a case with etiologic considerations. *Oral Surg Oral Med Oral Pathol* 1984;58:696-8.
20. Gorsky M, Silverman S Jr. Denture wearing and oral cancer. *J Prosthet Dent* 1984;52:164-6.
21. Jaikittivong A, Aneksuk V, Langlais RP. Oral mucosal lesions in denture wearers. *Gerodontology* 2010;27:26-32.
22. Albuquerque R, López-López J, Mari-Roig A, Jané-Salas E, Chimenos-Küstner E, Santos JR. Relationship between squamous cell carcinoma of the anterior two thirds of the tongue and removable denture use: a pioneer study in a Portuguese population. *Braz Dent J* 2011;22:410-4.
23. Sharp GS. Treatment for low tolerance to dentures: supplemental report. *J Prosthet Dent* 1967;17:222-6.
24. Saito T, Sugiura C, Hirai A, Notani K, Totsuka Y, Shindoh M, Fukuda H. Development of squamous cell carcinoma from pre-existent oral leukoplakia: with respect to treatment modality. *Int J Oral Maxillofac Surg* 2001;30:49-53.
25. Korraah A, Odenthal M, Kopp M, Vigneswaran N, Sacks PG, Dienes HP, Stützer H, Niedermeier W. Induction of apoptosis and up-regulation of cellular proliferation in oral leukoplakia cell lines inside electric field. *Oral Surg Oral Med Oral Pathol Oral Radiol* 2012;113:644-54.
26. Reinhard MC, Solomon HA. Electrical currents from dental metals as an etiologic factor in oral cancer. *Am J Cancer* 1934;22:606-10.
27. Bascom PW. Oral cancer and prosthodontics. *J Prosthet Dent* 1968;19:164-73.