

# Autotransplantation combined with orthodontic treatment: a case involving the maxillary central incisors with root resorption after traumatic injury

**Manuel Marques  
Ferreira\*, Hugo M.  
Ferreira, Filomena  
Botelho, Eunice  
Carrilho**

Faculty of Medicine, University of  
Coimbra, Coimbra, Portugal

Traumatic dental injury can result in avulsion of anterior teeth. In young patients, it is a challenge to the dental professional because after replantation, late complications such as ankylosis require tooth extraction. Although prosthetic and orthodontic treatment, and implant placement have been described as the options for intervention, autogenous tooth transplantation could be an effective procedure in growing patients if there is a suitable donor tooth available. This case presents the treatment of a patient who suffered a traumatic injury at 9 years old with avulsion of tooth 21, which had been replanted, and intrusion of tooth 11. Both teeth ankylosed; thus they were removed and autotransplantation of premolars was carried out. After transplantation, the tooth underwent root canal treatment because of pulpal necrosis. Orthodontic treatment began 3 months after transplantation and during 7 years' follow-up the aesthetics and function were maintained without signs of resorption. (*Restor Dent Endod* 2015;40(3):236-240)

**Key words:** Autotransplantation; Orthodontic treatment; Surgical procedure

Received November 12, 2014;  
Accepted March 8, 2015.

Ferreira MM; Ferreira HM; Botelho F; Carrilho E, Faculty of Medicine, University of Coimbra, Coimbra, Portugal

**\*Correspondence to**

Manuel Marques Ferreira, DDS, MSD, PhD.

Professor, Faculty of Medicine, University of Coimbra, Av. Bissaya Barreto-Blocos de Celas-CHUC-3000-075 Coimbra, Portugal  
TEL, +351239834616; FAX, +351239834616; E-mail, mmferreira@fmed.uc.pt

## Introduction

Traumatic dental injury can result in the loss of anterior teeth, with aesthetic and functional consequences for patients. The avulsion of anterior teeth in young patients is a challenge to the dental professional, for which prosthetic treatment, orthodontic treatment, and implant placement are established treatment options. If a suitable donor tooth is available, autogenous tooth transplantation is an alternative biological procedure for arch restoration.<sup>1-3</sup> This option results in aesthetic improvements, maintains the occlusion, permits normal phonetic articulation, and allows normal vertical alveolar and facial growth in patients. However, this procedure does not always have an optimal prognosis, and the success of the procedure depends on appropriate case selection, the stage of root development, and proper surgical technique.<sup>4-6</sup>

This case report describes the treatment of a patient who suffered a traumatic injury at nine years of age. Tooth 21 had been avulsed and replanted and tooth 11 was intruded. After the trauma, both teeth became ankylosed and were extracted. An autotransplantation procedure using two premolars was carried out to reconstruct her dentition in order to facilitate dentoalveolar growth and to address aesthetic and functional concerns. After seven years of follow-up, the aesthetic and functional improvements remained stable, with no signs of resorption.

## Case Report

In November 2007, a 14 year old female patient presented to our dental office. She had an open bite and had experienced a traumatic dental injury at nine years of age. Tooth 21 was avulsed and had been replanted and tooth 11 was intruded. Both teeth had ankylosed, were infraoccluded, and demonstrated a stone percussion sound. Her complaints were the aesthetic appearance of these teeth and the fact that she had used an orthodontic appliance for a long time (since nine years of age). Clinical and radiographic findings presented a face with a convex profile, open bite, and the presence of an orthodontic appliance (Figure 1a). On radiographic evaluation, tooth 11 showed pulpal canal obliteration and tooth 21 had received root canal treatment. Inflammatory root resorption and replacement root resorption were present in both teeth, and tooth 12 demonstrated apical root resorption (Figures 1b and 1c).

After evaluation, orthodontic treatment was recommended, with extraction of the four first premolars and autotransplantation of the mandibular premolars to the site of the upper central incisors. The treatment plan consisted of removing the orthodontic appliance, study for orthodontic treatment, extraction of teeth 14 and 24, extraction of teeth 11 and 21 and preparation of the sockets, extraction of teeth 34 and 44 and transplantation to the sockets of teeth 11 and 21, reshaping the transplanted teeth, placement of a full fixed appliance, removal of the orthodontic appliance, and the placement of an upper Hawley retainer and lower flexible lingual bonded retainer on the six anterior teeth. The patient's parents accepted the proposed treatment plan.

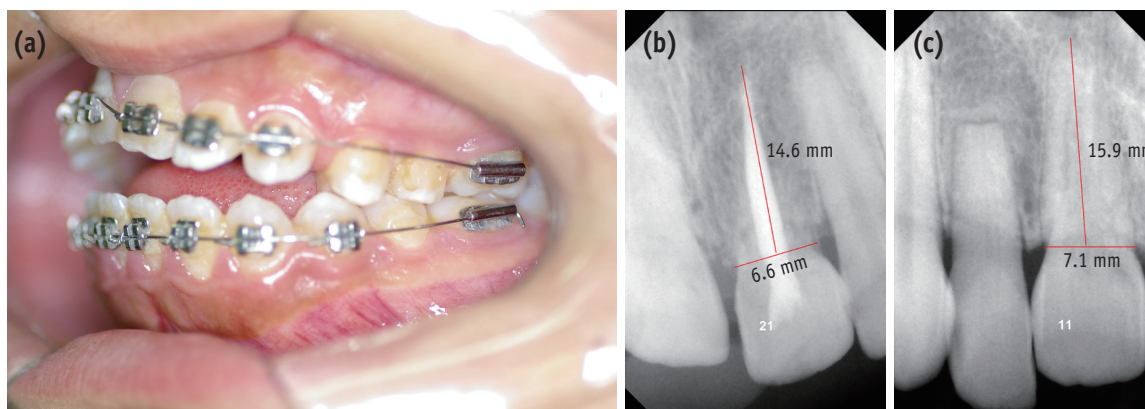
Articaine hydrochloride anhydrous was used as a local anesthetic, with 1:200,000 adrenaline tartrate (Meganest 1:200,000, Clarben, S.A., Madrid, Spain). Teeth 11 and 21 were extracted after an intrasulcular incision to allow for

better gingival fiber reinsertion. The recipient sites were evaluated clinically and on the radiographs (Figures 1b and 1c). The donor teeth were measured with periapical radiography and acrylic model teeth were made with the same shape and dimensions of the donor teeth (Figures 1b and 1c). These models were used in the preparation of the alveolar recipient sites.<sup>4</sup>

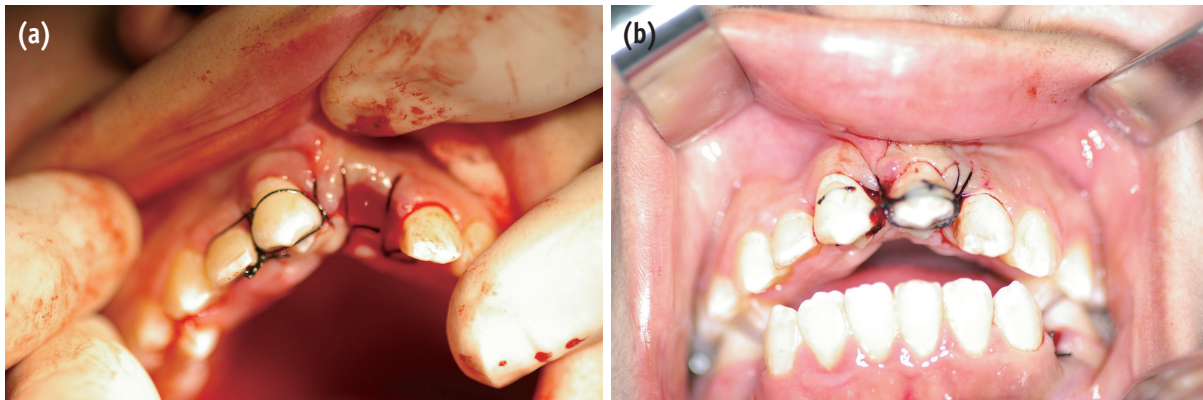
The recipient bed was prepared for immediate transplantation to the site of tooth 11, whereas transplantation was deferred by ten days for tooth 21 (Figures 2a and 2b). The teeth chosen for transplantation were cleaned with a polishing brush and toothpaste, and disinfection of the oral cavity was carried out with a solution of 0.1% chlorhexidine digluconate and 0.1% clorbutanol hemihydrate (Eludril, Pierre Fabre Dermo-Cosmétique, Soual, France). The teeth chosen for transplantation were atraumatically extracted and gently inserted into the prepared alveolar socket. The extra-alveolar time of the transplanted teeth was minimal (less than five minutes), in order to maintain the vitality of periodontal ligament cells.

After transplantation, the teeth were splinted during a period of ten days using 3-0 silk sutures crossing the occlusal face of the tooth, and then were fixed with composite (Figures 2a and 2b). The occlusion was checked and controlled with blue/red 60  $\mu$ m interarticular paper (D-50769, Bausch KG, Köln, Germany). An antibiotic was administered, starting 24 hours before the intervention (one gram amoxicillin tablets, one tablet every 12 hours), and continuing for six days after the procedure.

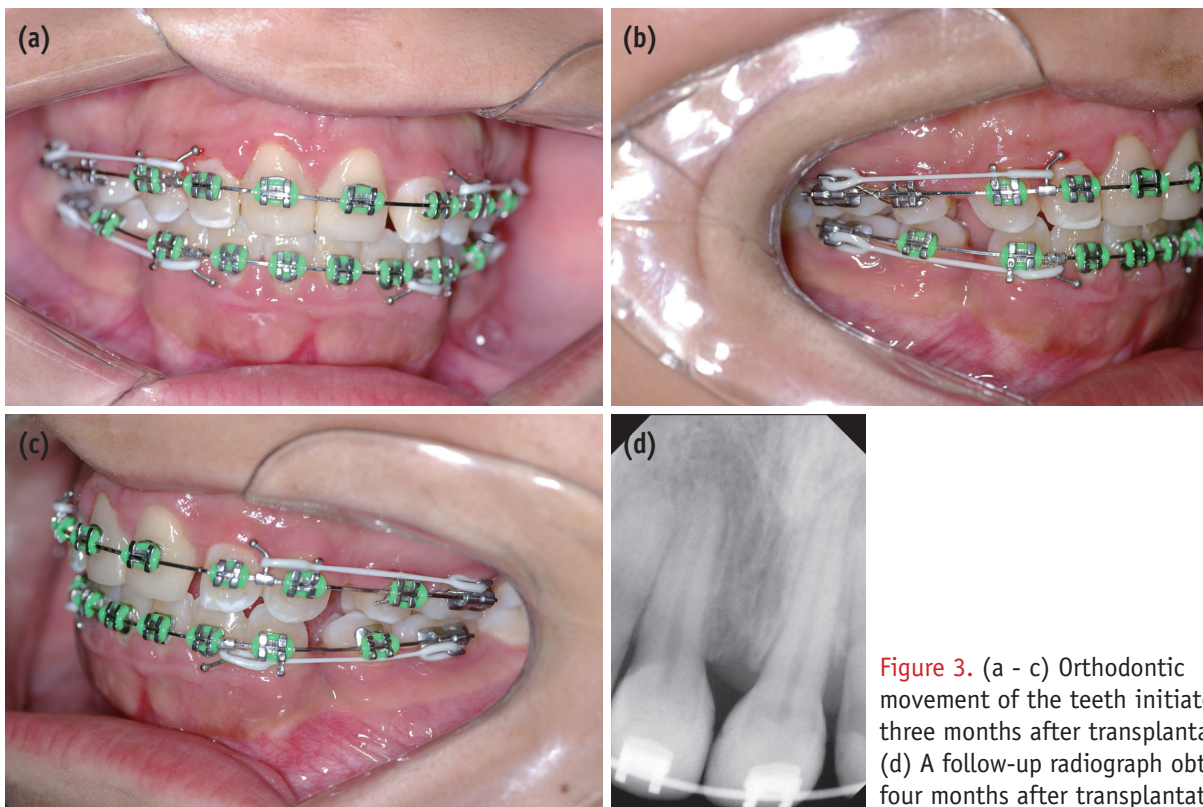
Instructions were given for analgesic treatment (paracetamol, 500 mg tablets as necessary, no more than 4 tablets in 24 hours). An ice pack was applied to the face, protected with fabric or paper. A soft diet was advised for 48 hours after the transplantation, and chewing with the transplanted teeth was prohibited for a period of seven days. Careful oral hygiene was also recommended,



**Figure 1.** (a) Intraoral image showing an anterior open bite; (b) Radiograph of tooth 21 with root resorption and measures used to prepare the socket to receive the tooth to be transplanted; (c) Radiograph of teeth 11 and 12 with root resorption and measures used to prepare the socket to receive the tooth to be transplanted.



**Figure 2.** (a) A donor tooth placed into an artificial socket, stabilized with 3-0 silk sutures crossing the occlusal face of the tooth, and fixed with composite. An artificial alveolus was prepared according to predetermined dimensions for the tooth chosen for transplantation 10 days later; (b) Tooth transplanted 10 days after the socket had been prepared.



**Figure 3.** (a - c) Orthodontic movement of the teeth initiated three months after transplantation; (d) A follow-up radiograph obtained four months after transplantation.

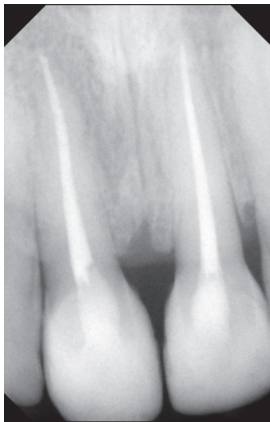followed by a mouthwash with 1 mg/mL chlorhexidine digluconate (Eludril), diluted in 5 mL of water. The sutures were removed 10 days after the operation. The day after the transplantation, the patient was observed and questioned regarding the occurrence of pain, swelling, and bleeding. Follow-up examinations were performed 10 days, one month, three months, six months, and annually after the transplantation. In each follow-up examination, a radiographic examination and sensitivity testing to cold

and percussion were performed, as well as observations of the gums, the marginal groove, and dental mobility.

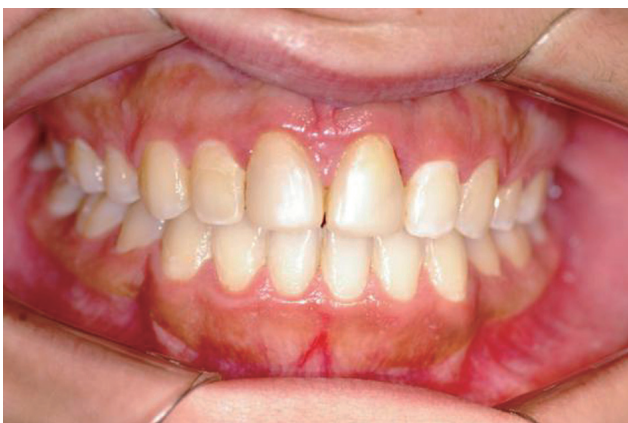Orthodontic treatment began three months after the transplantation, because orthodontic movement after periodontal healing could prevent the ankylosis of autotransplanted teeth.<sup>7</sup> After a temporary resin-based composite build-up on the natural premolar crowns, they were shaped into upper central incisors (Figures 3a - 3d). Orthodontic treatment was performed and transplanted

teeth were clinically evaluated through percussion, mobility tests, and radiography. Due to the young age of the patient, a period of time was allowed to pass with monthly vitality checks, in the hope that revascularization would occur. However, revascularization did not take place. The transplanted teeth developed pulp necrosis, and root canal treatment was performed (Figure 4). The periodontal ligament healed and healthy periradicular tissues were maintained.

A satisfactory aesthetic result and functional occlusion were obtained. The 7 year follow-up showed maintenance of aesthetic improvements, adequate function of the transplanted and reshaped teeth, and radiographic evidence of periradicular tissue health (Figure 5).



**Figure 4.** A transplanted tooth after root canal treatment, showing good periodontal healing.



**Figure 5.** The treatment was determined to be aesthetically and functionally successful after seven years of post-transplantation follow-up.

## Discussion

After the avulsion of a tooth, a decision has to be made whether to perform replantation, even in an emergency context when the ideal conditions for preventing ankylosis cannot be achieved. If a replanted tooth becomes ankylosed and the child is a candidate for autotransplantation, the tooth chosen for transplantation can still be removed within the optimal time for a successful transplantation. The successful autotransplantation of premolars to replace missing anterior teeth in growing patients has frequently been reported.<sup>1,5</sup> The surgical technique for dental transplantation requires very accurate techniques to prevent damage of the periodontal ligament and to achieve optimal results.<sup>3,5,8-11</sup>

This case reports two transplanted premolar teeth, one of which was transplanted immediately after the ankylosed incisor was extracted and the socket prepared according to the shape of the premolar selected for transplantation.<sup>4,12</sup> An acrylic tooth model was used to prepare the recipient socket with the same dimensions of the tooth chosen for transplantation. Acrylic tooth models are used to prevent contact between the root of the tooth and the bone, thus preventing ankylosis.

The other tooth was transplanted 10 days after the socket had been prepared. This technique provided the transplanted teeth with a good bed, containing new and vascularized tissue.<sup>8,10,12,13</sup> The results were similar in both cases regarding healing and overall success, although necrosis occurred in the two transplanted teeth. Silk 3-0 sutures were the preferred material to stabilize the teeth, instead of stainless steel and composite, due to their flexibility, which allows physiological movements and prevents ankylosis.<sup>3,4,6,8,9</sup> Before orthodontic treatment, reshaping was performed to make the morphology of the teeth resemble that of the incisors. The normal periodontal ligament was re-established to enable the transplanted teeth to undergo the same orthodontic movements as the other teeth. After reshaping the crown, orthodontic treatment was initiated.

Autotransplantation treatment procedures can have long-term complications, such as pulpal necrosis associated with a completely formed root. Due to the young age of our patient, a period of time was allowed to elapse, with monthly vitality checks, in the hope that revascularization would occur. However, revascularization did not take place, and it was necessary to perform a root canal treatment. In the seven year period of follow-up in this case, the survival rate of the transplanted teeth was 100%, regarding aesthetics, function, clinical appearance, and the radiographic image of the alveolar process.

Transplanted teeth equipped with a periodontal membrane can be moved orthodontically, preserving the bone and maintaining the potential for normal alveolar bone growth

in young patients. This technique can be integrated into a multidisciplinary treatment plan, providing an alternative to dental implants in growing patients. Although bone-integrated implants have become a treatment option to replace missing teeth in adolescents, they can only be used after the completion of facial growth. During the interim period, the patient must use a removable retainer with an artificial tooth, resulting in resorption of the bone and aesthetic difficulties in later implant placement.

## Conclusions

Autotransplantation is a reliable approach to replace lost teeth due to traumatic injury and is the best solution in growing patients, due to its potential to restore the dentition and maintain alveolar bone growth. When ankylosis of replanted maxillary incisors occurs, transplanting the premolars is an option with a high rate of success, if the relevant biological variables are adequately controlled. An interdisciplinary approach to dental autotransplantation can provide functional and aesthetically satisfactory natural teeth replacements for growing patients.

Conflict of Interest: No potential conflict of interest relevant to this article was reported.

## References

1. Clokie CM, Yau DM, Chano L. Autogenous tooth transplantation: an alternative to dental implant placement? *J Can Dent Assoc* 2001;67:92-96.
2. Tsukiboshi M. History and future prospects. In: Tsukiboshi M, editor. *Autotransplantation of teeth*. 2nd ed. Carol Stream, IL: Quintessence Publishing Co. Inc.; 2001. p170-171.
3. Andreasen JO, Paulsen HU, Yu Z, Schwartz O. A long-term study of 370 autotransplanted premolars. Part III. Periodontal healing subsequent to transplantation. *Eur J Orthod* 1990;12:25-37.
4. Marques-Ferreira M, Rabaça-Botelho MF, Carvalho L, Oliveiros B, Palmeirão-Carrilho EV. Autogenous tooth transplantation: evaluation of pulp tissue regeneration. *Med Oral Patol Oral Cir Bucal* 2011;16:e984-e989.
5. Bae JH, Choi YH, Cho BH, Kim YK, Kim SG. Autotransplantation of teeth with complete root formation: a case series. *J Endod* 2010;36:1422-1426.
6. Ferreira MM, Botelho MF, Abrantes M, Oliveiros B, Carrilho EV. Quantitative scintigraphic analysis of pulp revascularization in autotransplanted teeth in dogs. *Arch Oral Biol* 2010;55:825-829.
7. Yang Y, Bai Y, Li S, Li J, Gao W, Ru N. Effect of early orthodontic force on periodontal healing after autotransplantation of permanent incisors in beagle dogs. *J Periodontol* 2012;83:235-241.
8. Ferreira MM, Botelho MF, Carvalho L, Silva MR, Oliveiros B, Carrilho EV. Evaluation of dentin formed in autogenous tooth transplantation in the dog: a comparison between one- and two-stage surgical techniques. *Dent Traumatol* 2012;28:97-100.
9. Nasjleti CE, Castelli WA, Caffesse RG. The effect of different splinting times on replantation of teeth in monkeys. *Oral Surg Oral Med Oral Pathol* 1982;53:557-566.
10. Katayama A, Ota M, Sugito H, Shibukawa Y, Yamada S. Effect of proliferating tissue on transplanted teeth in dogs. *Oral Sug Oral Med Oral Pathol Oral Radiol Endod* 2006;101:e110-e118.
11. Lindskog S, Pierce AM, Blomlof L, Hammarstrom L. The role of necrotic periodontal membrane in cementum resorption and ankylosis. *Endod Dent Traumatol* 1985;1:96-101.
12. Lee SJ, Jung IY, Lee CY, Choi SY, Kum KY. Clinical application of computer-aided rapid prototyping for tooth transplantation. *Dent Traumatol* 2001;17:114-119.
13. Nethander G, Skoglund A, Kahnberg KE. Experimental autogenous tooth transplantation in the dog: a comparison between one- and two-stage surgical techniques. *Acta Odontol Scand* 2003;61:223-229.