

Massive Hemoptysis due to Endotracheal Hemangioma: A Case Report and Literature Review

Yeonsil Yu, M.D.¹, Suhyeon Lee, M.D.¹, Jinyoung An, M.D.¹, Jeongmin Lee, M.D.¹, Jihoon Kim, M.D.², Youngkyung Lee, M.D, Ph.D.³, Eunah Jung, M.D.⁴, Sookhee Song, M.D.¹, Hyeok Kim, M.D., Ph.D.¹ and Suhyun Kim, M.D.¹

Departments of ¹Internal Medicine, ²Otorhinolaryngology-Head and Neck Surgery, ³Radiology, and ⁴Pathology, Seoul Medical Center, Seoul, Korea

Tracheal hemangioma is a rare benign vascular tumor in adults. We reported a case of massive hemoptysis caused by a cavernous hemangioma in a 75-year-old man. This is the first report, to our knowledge, of a tracheal cavernous hemangioma that presented with massive hemoptysis. The lesion was removed with a CO₂ laser under rigid laryngoscopy. Endovascular tumors, such as tracheobronchial hemangiomas, should be considered a diagnostic option in cases of massive hemoptysis without a significant underlying lung lesion.

Keywords: Hemangioma, Cavernous; Hemoptysis; Trachea

Introduction

Primary tracheal tumors are rare with an approximate incidence of 2.7 new cases per million per year, with vascular tumors accounting for less than 10%^{1,2}. Tracheal tumors are more commonly malignant than benign in adults, whereas the reverse is true in children³. Hemangioma of the tracheo-bronchial tree occurs more frequently in young children and regresses steadily, while, tracheal hemangioma is exceptional in adults¹. Hemoptysis is one of the most serious and possibly

life-threatening manifestations of the disease. We reported a case of tracheal hemangioma in an adult with massive hemoptysis. We furthermore reviewed the literature to date.

Case Report

A 75-year-old man presented with hemoptysis in our outpatient clinic. He had recurrent episodes of blood tinged sputum and minor hemoptysis during the past year. He had a history of smoking an average of 55 pack-year of cigarettes and had bronchial asthma. Recently, he had also been diagnosed with smear-negative pulmonary tuberculosis (TB) in the public health center and was treated with anti-TB drugs. The results of hematologic and chemical laboratory tests were unremarkable. Chest radiography showed small nodules with linear opacities in the left upper lung zones. Low dose chest computed tomography (CT) scans without contrast enhancement showed small calcified nodules with linear opacities in the left upper lobe. The opacities in the left upper lobe were unchanged in comparison with low dose chest CT scans examined 10 months ago. Occasional hemoptysis persisted despite the ongoing anti-TB therapy and oral tranexamic acid administered for about a month. Flexible bronchoscopy performed under local anesthesia, revealed an approximately 6 mm-

Address for correspondence: Suhyun Kim, M.D.

Department of Internal Medicine, Seoul Medical Center, 156 Sinnae-ro, Jungnang-gu, Seoul 131-795, Korea

Phone: 82-2-2276-7808, **Fax:** 82-2-2276-7820

E-mail: sammy7597@naver.com

Received: Oct. 7, 2014

Revised: Nov. 10, 2014

Accepted: Nov. 26, 2014

©It is identical to the Creative Commons Attribution Non-Commercial License (<http://creativecommons.org/licenses/by-nc/3.0/>).

Copyright © 2015

The Korean Academy of Tuberculosis and Respiratory Diseases.

All rights reserved.

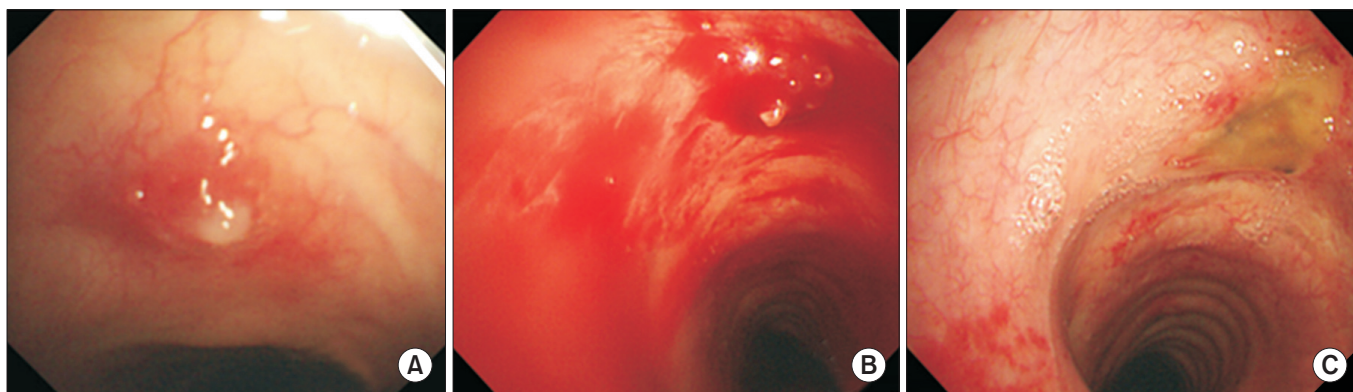


Figure 1. Bronchoscopic findings. (A) Initial bronchoscopy showed a polypoid lesion on the ventral wall of the trachea, 5 mm below the vocal cord. (B) Follow-up bronchoscopy showed massive bleeding on the polypoid lesion. (C) Postoperative bronchoscopy showed healing and scarring of the lesion with no evidence of bleeding.

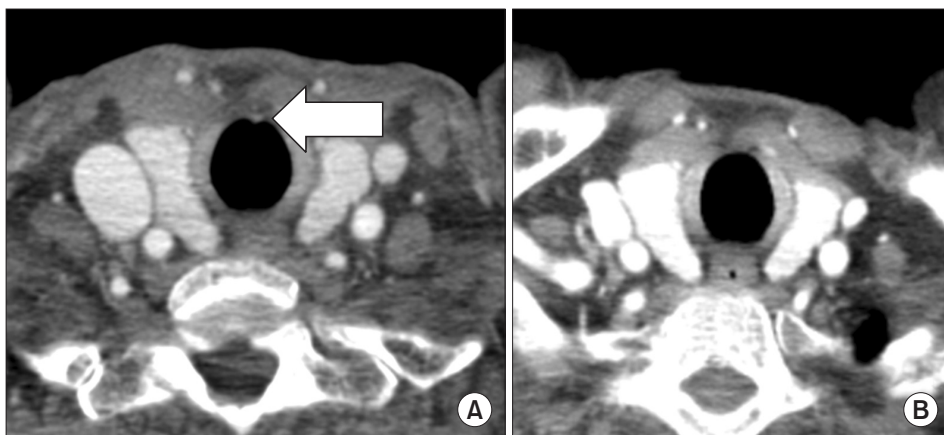


Figure 2. Chest computed tomography scans. (A) Initial imaging showed a focal enhancement smaller than 5 mm in the midline of the anterior tracheal wall (arrow). (B) Postoperative imaging shows disappearance of the previous tracheal nodular lesion.

sized, well-circumscribed, reddish hypervascular, multiloculated, polypoid lesion found on the ventral wall of the tracheal midline, 5 mm below the vocal cords (Figure 1A). The other parts of the trachea and bronchi were unremarkable. Bleeding from the polypoid lesion occurred on intra-procedural coughing. The bleeding stopped after endobronchial instillation of 1:10,000 diluted epinephrine. However, forcep biopsy without laser coagulation equipment was not attempted due to the possibility of profuse intra-procedural bleeding.

The patient was admitted and treated with intravenous tranexamic acid. Subsequently, no further hemoptysis was found until 1-week postbronchoscopy. Chest CT scans with contrast enhancement showed a focal enhancement <5 mm in the midline of the anterior tracheal wall (Figure 2A, arrow). The polypoid lesion was diagnosed as a presumptive tracheal hemangioma. We referred the patient to a tertiary referral hospital for therapeutic bronchoscopic laser ablation. The hospital staff recommended a wait-and-see policy; however, 3 days later he was admitted to our hospital for recurrent episodes of massive hemoptysis. During the follow-up bronchoscopy, ap-

proximately 500 mL of blood was suctioned from the tracheal polypoid lesion (Figure 1B). A consult was arranged with the otorhinolaryngology department. The patient underwent an emergency operation for the tracheal lesion, under general anesthesia on the 10th day of hospitalization. A 4-mm-sized, hemorrhagic and polypoid lesion was found about 5 mm below the glottis. The lesion was removed by CO₂ laser (2 watt, super-pulse, continuous mode) under rigid laryngoscopy. After removal, bleeding from tracheal mucosa was controlled by coagulation with a suction Bovie. The patient had no further episodes of hemoptysis during the 12 months postoperative follow-up period. Histopathology showed several dilated spaces generally with degenerated lining cells; the dilated spaces lined by flattened cells focally, contained few red blood cells (Figure 3). A diagnosis of tracheal cavernous hemangioma was made. One-week follow-up flexible bronchoscopy showed healing and scarring of the lesion with no evidence of bleeding (Figure 1C). The tracheal nodular lesion had disappeared in the 6-month follow-up chest CT scans (Figure 2B).

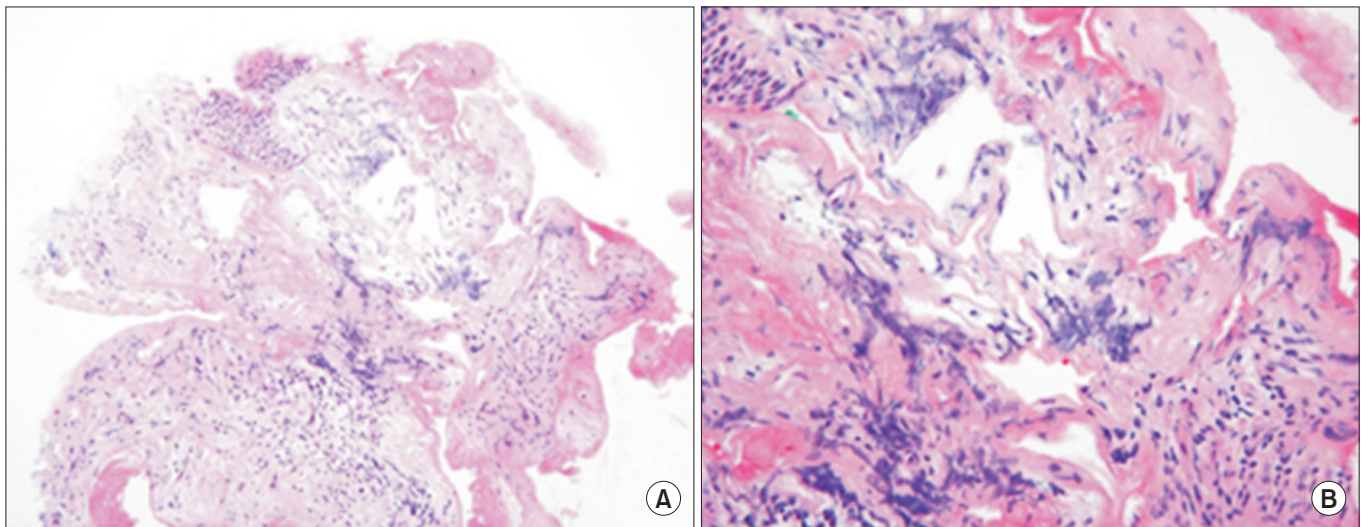


Figure 3. Photograph of histopathological specimen showing multiple dilated vascular spaces containing a few red blood cells (A, H&E stain, $\times 200$; B, H&E stain, $\times 400$).

Discussion

Hemangioma is a common benign tumor of the head and neck in children, which is characterized by proliferative development during infancy and gradual involution later in childhood⁴. Sweetser classified hemangiomas of the airways into the infantile and adult varieties¹. Hemangiomas in adults usually arise from the upper airway, including the laryngopharynx, nose, and tongue, and seldom arise from the subglottic trachea⁵. Hoarseness with slight or no dyspnea is the most common manifestation, and hemoptysis occurs frequently⁵. Hemangiomas can be divided into cavernous and capillary types, depending on the diameter of the vascular channels that comprise the tumor⁶. Capillary hemangioma is the most common variant of hemangiomas that occur in the skin, subcutaneous tissues, and mucous membranes of the oral cavities and lips, as well as in internal viscera⁶. Microscopically, cavernous hemangioma is a well-demarcated lesion composed of large spaces filled with red blood cells and thrombotic material, while capillary hemangiomas do not have such large vascular spaces⁶. Cavernous hemangioma, as in this case, have a higher risk of bleeding due to large cavernous spaces than the capillary hemangioma⁶.

Tracheobronchial hemangioma is an extremely rare disease with only few cases reported to date (Table 1)¹⁻¹⁴. The most frequent symptom is minor to massive hemoptysis⁴. To the best of our knowledge, this is the first report of a tracheal cavernous hemangioma that presented with massive hemoptysis. The amount of bleeding is usually correlated with length of hospital stay and outcome in patients¹⁵. Our patient presented with recurrent episodes of blood tinged sputum and minor hemoptysis, followed by massive hemoptysis of

about 500 mL during bronchoscopy. Emergency laryngomicrosurgery was performed on the tracheal hemangioma under general anesthesia on the 10th day of hospitalization. The patient was discharged without intensive care unit care on the 14th day. The two previously reported cases of capillary hemangiomas with massive hemoptysis were treated with Nd:YAG laser and interventional radiology, respectively^{1,6}. The first patient presented with hemoptysis (coughed up volume, 500 mL) and a 1 cm hemangioma 7 cm below the vocal cord on bronchoscopy, which was coagulated with Nd:YAG laser⁶. The second patient manifested massive hemoptysis of unknown volume and an irregular excrescent mass leading to 30% to 40% stenosis of the proximal trachea on bronchoscopy. After catheter embolization of the pathologic right intercostal bronchial trunk, the patient was kept sedated for 24 hours with orotracheal intubation and insufflation of the orotracheal tube balloon at the hemangioma¹.

Bronchiectasis, TB, mycetomas, necrotizing pneumonia and bronchogenic carcinomas are the main underlying conditions of massive hemoptysis. Several alterations in vascular anatomy may occur in these chronic inflammatory or infectious lung diseases¹⁵. Some authors suggest that CT scans should replace bronchoscopy as a first-line investigational approach in patients with large (<300 mL/24 hr) or massive hemoptysis (>300 mL/24 hr), because of its higher diagnostic yield. It is crucial, however, to perform fiber-optic bronchoscopy (FOB) for diagnosis of endoluminal lesions as a bleeding focus in patients without definite lung parenchymal lesions or vascular abnormalities in CT scans. Although the optimal timing for a diagnostic FOB in hemoptysis remains controversial, early FOB might be more helpful than delayed FOB in patients without underlying lung disease. Chest radiograph and chest

Table 1. Review of case reports detailing tracheobronchial hemangiomas

Source	Gender/ Age (yr)	Underlying lung disease	Clinical symptoms (amount of hemoptysis)	Bronchoscopic findings and locations of the lesions	Treatment
Brown and Rebeiz (1993) ⁷	M/47	None	Hemoptysis (5 mL)	5-mm-sized red, pedunculated mass on the anterior tracheal wall just below the subglottis	Endoscopic biopsy and Nd:YAG laser
Strausz and Soltesz (1999) ⁸	M/55	None	Hemoptysis (NA)	2×2-mm-sized reddish lesion with capillarized surface on the ventral wall of the middle trachea	Bronchoscopy with forceps excisional biopsy
Strausz and Soltesz (1999) ⁸	F/70	None	Chronic cough	5×4-mm-sized smooth surface lesion on the left upper lobe bronchus	Nd:YAG laser
So et al. (1999) ⁶	F/32	None	Massive hemoptysis (500 mL)	1-cm-sized smooth surface mass 7 cm below the vocal cords	Nd:YAG laser
Irani et al. (2003) ⁹	F/72	None	Cough, hemoptysis (NA)	2–3-mm-sized polypoid tracheal tumor with hyperemic mucosa 3 cm below the vocal cords	Bronchoscopy and forceps biopsy
Zambudio et al. (2003) ¹	F/66	ITP	Massive hemoptysis (NA)	Irregular excrescent tracheal mass on the lumen between the first and third tracheal rings	Embolization of branch of right intercostal artery by interventional radiology (ICU care)
Cordos et al. (2005) ¹⁰	M/50	None	Dyspnea, hemoptysis (NA)	Not available	Interventional endoscopy and surgical resection, Nd:YAG laser
Madhumita et al. (2004) ³	F/40	None	Foreign body sensation, hemoptysis (NA)	10×5-mm-sized cherry-red tracheal mass in the upper one-third, 20 cm from the upper incisor tooth	Bronchoscopic excision under general anesthesia
Rose and Mathur (2008) ⁵	M/66	Mitral stenosis	Hemoptysis (NA)	Three mucosal polyps lateral to the carina at the proximal left mainstem bronchus	Bronchoscopy with forceps biopsy and APC
Chawla et al. (2010) ¹¹	M/62	PTE with IVC filter, asthma	Hemoptysis (NA)	Soft lesion at the 9 o'clock position in the distal trachea	Bronchoscopy with forceps excisional biopsy and Nd:YAG laser
Kim et al. (2010) ¹²	F/28	None	Cough, hemoptysis (25 mL)	10-mm-sized polypoid lesion in the lateral wall of proximal trachea 2 cm below the vocal cords	Removed by rigid bronchoscopy
Amy and Enrique (2012) ¹³	M/22	Hypogonadism with testosterone therapy	Hemoptysis (2–4 tablespoons)	15-mm-sized purple, vascular lesion 3 cm from the carina at the 5 o'clock position in the distal trachea	Bronchoscopic removal with electrocautery loose snare
Jie et al. (2012) ¹⁴	M/35	None	Cough, dyspnea, hemoptysis (NA)	15×20-mm-sized hyperemic mucosal polypoid lesion in the lateral wall of the proximal left main bronchus	Tracheal endoscopic electrocautery, APC, and brachytherapy
Cho et al. (2013) ⁴	M/61	Asthma, COPD, old TB, HTN, DM	Hemoptysis (NA)	3-mm-sized polypoid lesion on the medial side of left lingular segmental bronchus	Bronchoscopy with forceps biopsy
Prakash et al. (2014) ²	F/23	Misdiagnosed as refractory asthma, pregnant	Acute respiratory failure	40×20-mm-sized polypoid lesion in the posterior tracheal wall, extending from the tip of the endotracheal tube	Surgical debulking with ECMO (ICU care)

NA: not available; Nd:YAG: neodymium:yttrium-aluminum-garnet; ITP: idiopathic thrombocytopenic purpura; ICU: intensive care unit; APC: argon plasma coagulation; PTE: pulmonary thromboembolism; IVC: inferior vena cava; COPD: chronic obstructive pulmonary disease; TB: tuberculosis; HTN: hypertension; DM: diabetes mellitus; ECMO: extracorporeal membrane oxygenation.

CT scans are typical, and bronchoscopy is fundamental for diagnosis and obtaining specimens for histologic confirmation of tumor like tracheal hemangioma, as in our case.

Maximal growth of hemangioma occurs within a few weeks and the definitive pathophysiologic mechanism remains unknown. Hormonal changes during pregnancy, viral or bacterial infection, trauma, and preexisting arteriovenous malformations have been considered as potential etiologic factors¹¹. Prakash et al.² described a case who presented at 32-week gestation with life-threatening respiratory failure resembling acute severe asthma, requiring invasive ventilation that was extremely difficult. Amy and Enrique¹³ reported tracheal hemangioma in patient recently started on testosterone therapy, although the relationship between testosterone and angiogenesis has not been confirmed. However, other previously reported cases of tracheobronchial hemangiomas had no definite predisposing factors (Table 1). Hemangiomas were mostly located on the trachea, especially the upper one-third of the trachea, except four cases that were located on the left bronchus^{4,5,8,14}.

The mainstay of treatment in symptomatic cases is surgical debulking or excision using various methods². There are several therapeutic alternatives such as systemic steroids, local injection of sclerosing substances, excisional forceps biopsy with adequate hemostasis, Nd:YAG laser, argon plasma coagulation, arteriographic embolization and endotracheal brachytherapy⁴. Although surgical excision is the curative treatment of choice, surgical treatment was only selected in two cases within the literature. One patient with minimal hemoptysis underwent partial bronchial resection combined with interventional bronchoscopy with Nd:YAG laser⁷. The other patient presented with respiratory failure and the tumor was subsequently debulked and the trachea stented by bi-femoral veno-venous extra-corporeal membrane oxygenation. Most of the cases listed in Table 1 were treated with therapeutic bronchoscopy using Nd:YAG laser or forcep biopsy. Although the tumor may be completely removed with a flexible bronchoscopic excisional biopsy and local instillation of adrenaline for bleeding control^{4,8,9}, there are reports of massive and fatal hemorrhage from endobronchial vascular lesion injury during bronchoscopic biopsy^{4,13}. Interventional bronchoscopy (e.g., rigid bronchoscopy) during the removal is highly suggested if bleeding is a potential risk, such as in case of vascular tumors¹³. Interventional bronchoscopy was unavailable and the lesion was located in the upper trachea, hence, we performed laryngomicrosurgery instead of bronchoscopic excisional biopsy. Embolization is currently not used as a therapeutic option in interventional radiology of tumor vascularization. However, Zambudio et al.¹ reported a case of a tracheal capillary hemangioma with idiopathic thrombocytopenic purpura, which began as massive hemoptysis and was treated successfully with embolization by interventional radiology; the lesion was large enough to be visualized on CT.

In conclusion, tracheal cavernous hemangioma that may produce massive hemoptysis, can be controlled efficiently and definitively with laser by rigid laryngoscopy, if located in the upper trachea, especially subglottis. Endovascular tumor like tracheobronchial hemangiomas should be considered as a diagnostic option in case of massive hemoptysis without significant underlying lung lesion in radiologic finding. While tracheobronchial hemangiomas can be treated with several methods according to lesion size and amount of hemoptysis, definitive treatment has not been established. The literature suggests the various available modalities for treatment and most cases have responded successfully to such treatment methods with favorable outcomes.

Conflicts of Interest

No potential conflict of interest relevant to this article was reported.

References

1. Zambudio AR, Calvo MJ, Lanzas JT, Medina JG, Paricio PP. Massive hemoptysis caused by tracheal hemangioma treated with interventional radiology. *Ann Thorac Surg* 2003;75:1302-4.
2. Prakash S, Bihari S, Wiersema U. A rare case of rapidly enlarging tracheal lobular capillary hemangioma presenting as difficult to ventilate acute asthma during pregnancy. *BMC Pulm Med* 2014;14:41.
3. Madhumita K, Sreekumar KP, Malini H, Indudharan R. Tracheal haemangioma: case report. *J Laryngol Otol* 2004;118:655-8.
4. Cho NJ, Baek AR, Kim J, Park JS, Jang AS, Park JS, et al. A case of capillary hemangioma of lingular segmental bronchus in adult. *Tuberc Respir Dis* 2013;75:36-9.
5. Rose AS, Mathur PN. Endobronchial capillary hemangioma: case report and review of the literature. *Respiration* 2008;76:221-4.
6. So SC, Kwack KK, Park HK, Kim JH, Shin HM, Lyu DY, et al. A case of tracheal hemangioma manifested massive hemoptysis. *Tuberc Respir Dis* 1999;47:704-8.
7. Brown JS, Rebeiz EE. Pathologic quiz case 1. Capillary hemangioma. *Arch Otolaryngol Head Neck Surg* 1993;119:700-2.
8. Strausz J, Soltesz I. Bronchial capillary hemangioma in adults. *Pathol Oncol Res* 1999;5:233-4.
9. Irani S, Brack T, Pfaltz M, Russi EW. Tracheal lobular capillary hemangioma: a rare cause of recurrent hemoptysis. *Chest* 2003;123:2148-9.
10. Cordos I, Ulmeanu R, Mihaltan FD, Orghidan M, Galbenu P, Dragomir A, et al. Sequential approach in a case of tracheal hemangioma: segmental tracheal resection after Nd-YAG la-

- ser application. *Pneumologia* 2005;54:191-4.
11. Chawla M, Stone C, Simoff MJ. Lobular capillary hemangioma of the trachea: the second case. *J Bronchology Interv Pulmonol* 2010;17:238-40.
 12. Kim HJ, Bae SY, Sung YK, Song SY, Jeon K, Koh WJ, et al. A case of tracheal capillary hemangioma in an adult. *Tuberc Respir Dis* 2010;69:385-8.
 13. Amy FT, Enrique DG. Lobular capillary hemangioma in the posterior trachea: a rare cause of hemoptysis. *Case Rep Pulmonol* 2012;2012:592524.
 14. Jie S, Hong-rui L, Fu-quan Z. Brachytherapy for tracheal lobular capillary haemangioma (LCH). *J Thorac Oncol* 2012;7:939-40.
 15. Sakr L, Dutau H. Massive hemoptysis: an update on the role of bronchoscopy in diagnosis and management. *Respiration* 2010;80:38-58.