

Case Report

Globus Pallidus Interna Deep Brain Stimulation for Chorea-Acanthocytosis

Jae-Hyeok Lee, M.D., Ph.D.,¹ Won-Ho Cho, M.D., Ph.D.,² Seung-Heon Cha, M.D., Ph.D.,² Dong-Wan Kang, M.D., Ph.D.²

Departments of Neurology,¹ Neurosurgery,² Pusan National University School of Medicine, Busan, Korea

Chorea-acanthocytosis (ChAc) is a rare hereditary disorder characterized by involuntary choreiform movements and erythrocytic acanthocytosis. Pharmacotherapy for control of involuntary movements has generally been of limited benefit. Deep brain stimulation (DBS) has recently been used for treatment of some refractory cases of ChAc. We report here on the effect of bilateral high-frequency DBS of globus pallidus interna in a patient with ChAc.

Key Words : Chorea-acanthocytosis · Deep brain stimulation · Chorea · Globus pallidus.

INTRODUCTION

Chorea-acanthocytosis (ChAc) is a rare autosomal recessive neurodegenerative disorder characterized by generalized chorea, orofaciolingual dyskinesia with dysphagia and dysarthria, muscle wasting, hyporeflexia, and behavioral disturbance⁶. ChAc can be diagnosed by Western blot identification of chorein or sequencing of the *VPS13* gene^{4,11}. Effective management of ChAc has long been a significant challenge. Medical treatment is mostly ineffective and deep brain stimulation (DBS) has recently been attempted for management of ChAc. We report here on a genetically confirmed case of ChAc in a patient who showed significant improvement after bilateral DBS of the globus pallidus interna (GPI). We also provide a review of the literature regarding the treatment outcome of this rare condition.

CASE REPORT

A 36-year-old man presented with exacerbation of slurred speech, orofaciolingual dyskinesia, tongue and lip biting, choreiform movements of the head and neck, and gait disturbance during the course of three years. There was no family history of similar neurological disorders. On examination, we observed rapid bending of the neck and trunk, alternating lateral flexion of the trunk when walking, resulting in frequent falls. Muscle power and muscle bulk, and sensory function were intact. The patient

did not show any psychiatric disorder during the psychiatric interview. Mini-mental status examination (MMSE) score was 30 and intelligence quotient was 85. Laboratory tests, including serum creatine kinase, iron, ferritin, lactate, lipids, and lipid electrophoresis were unremarkable. Results of nerve conduction study, electromyography, and electroencephalography showed no abnormal findings. Cardiomyopathy, cardiac arrhythmia, and hepatosplenomegaly were absent. Brain MR imaging (3.0-T MR system, Verio, Siemens, AG, Erlangen, Germany) showed bilateral atrophic putamina and head of caudate nuclei on a T2-weighted image (Fig. 1). Peripheral blood smear showed 21% acanthocytes confirmed by scanning electron microscopy (Fig. 2). Finally, genetic testing confirmed a homozygous nonsense mutation in exon 37 (c.4411C>T; p.Arg1471*) in the *VPS13* gene. His symptoms did not respond to medications, including diazepam, baclofen, trihexyphenidyl, haloperidol, and tetrabenazine. During the two-year follow-up period, his choreic movement and gait disturbance showed gradual worsening and he was no longer able to walk independently. We recommended DBS for the patient for control of symptoms and for improvement of functional capacity.

After written consent was obtained, he underwent bilateral implantation of a quadripolar electrode (model 3387; Medtronic, Minneapolis, MN, USA) into the GPI under generalized anesthesia so that the lowest contact terminated at the bottom of GPI (Fig. 3). We performed CT scan in order to confirm adequacy of

• Received : February 26, 2014 • Revised : April 17, 2014 • Accepted : May 13, 2014

• Address for reprints : Dong-Wan Kang, M.D., Ph.D.

Department of Neurosurgery, Pusan National University School of Medicine, 179 Gudeok-ro, Seo-gu, Busan 602-739, Korea
Tel : +82-51-240-7257, Fax : +82-51-244-0242, E-mail : drdwkang@gmail.com

• This is an Open Access article distributed under the terms of the Creative Commons Attribution Non-Commercial License (<http://creativecommons.org/licenses/by-nc/3.0>) which permits unrestricted non-commercial use, distribution, and reproduction in any medium, provided the original work is properly cited.

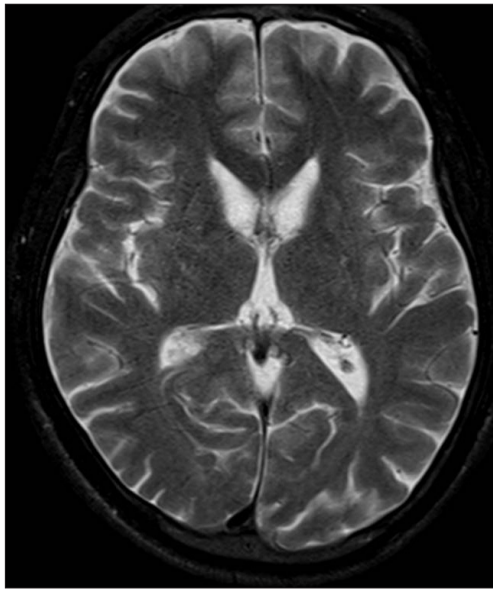


Fig. 1. T2-weighted MR imaging showed mild bilateral atrophy of the head of the caudate nucleus.

the electrode locations and absence of hemorrhage followed by placement of an internal pulse generator (Solettra; Medtronic). DBS programming was performed two weeks after implantation. Postoperatively, the benefit was rapidly evident with marked improvement in choreic movements. Tongue and lip biting almost disappeared and he was able to walk independently. However, dysarthria did not show significant improvement. In the six-month postoperative evaluation, motor section of Unified Huntington's Disease Rating Scale (UHDRS) score was 59 in the preoperative evaluation, and 36 after two months. One year after DBS implantation, the score had decreased to 34 and MMSE scores showed no change. The benefit had remained stable for two years (Table 1). The final DBS settings were as follows : right, 2.3 V, 60 μ s, 130 Hz; left, 2.9 V, 60 μ s, 130 Hz.

DISCUSSION

Our patient had typical ChAc, with choreic movements and tongue and lip biting. GPi-DBS provided a rapid benefit, which

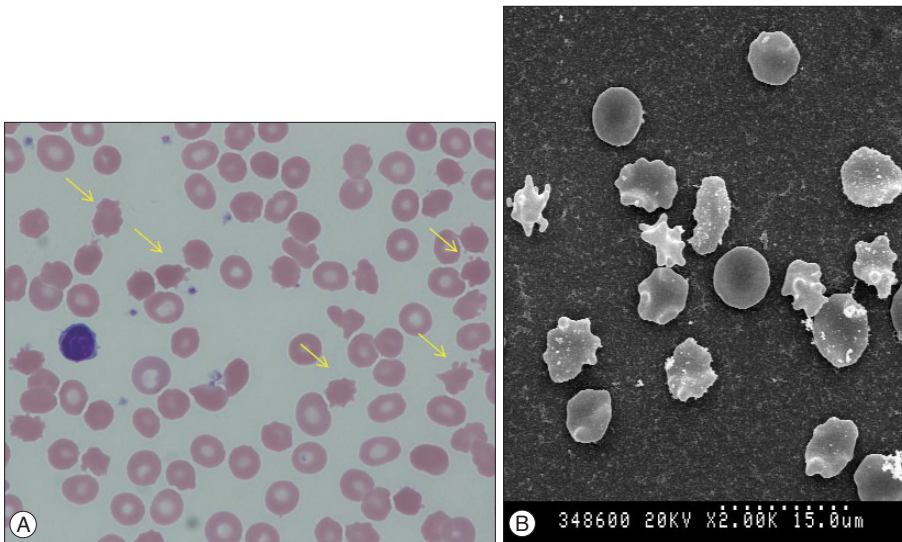


Fig. 2. A : Acanthocytosis (arrows) in a peripheral blood smear (wright stain, $\times 1000$). B : Electron microscopic scanning.

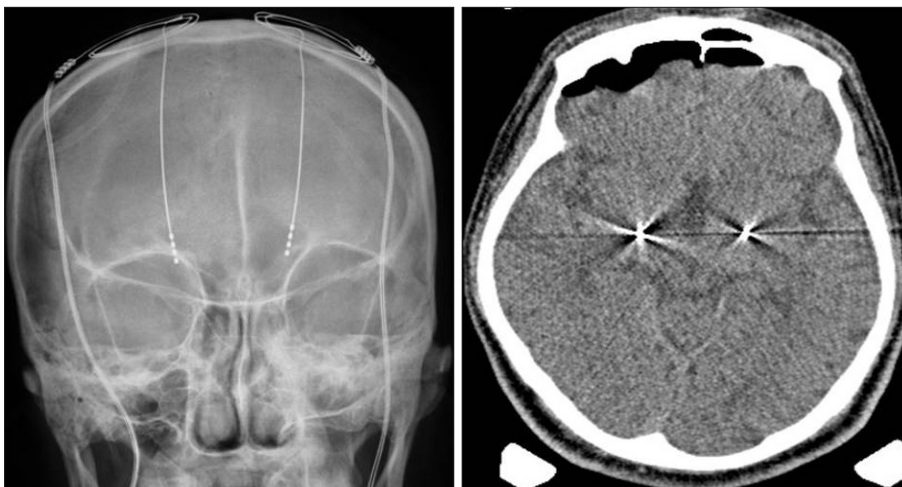


Fig. 3. Plain skull X-ray and CT scan showing a deep brain stimulation electrode located on the globus pallidus bilaterally.

Table 1. Clinical changing of pre- and postoperative states using the UHDRS

	Preoperative	Postoperative (2 months)	Postoperative (12 months)	Postoperative (18 months)	Postoperative (24 months)
UHDRS motor assessment (total score : 124)	59	36	34	35	36

UHDRS : Unified Huntington's Disease Rating Scale

Table 2. Summary of reported cases with ChAc treated by GPI DBS

Age	Sex	Symptoms	Duration to DBS (year)	Outcome	Chorein gene	Reference
38	M	Gait disturbance, tongue protrusion, oromandibular hyperkinesia	3	No benefit from high- or low-frequency stimulation of the GPI.	Not confirmed	Wihl et al. ¹⁴⁾
32	M	Dysarthria, tongue biting and walking difficulty	8	Low-frequency stimulation showed good results. At 130 Hz stimulation, symptoms were worsened.	Confirmed	Guehl et al. ⁵⁾
35	F	Tongue and lip biting, dysarthria, oromandibular dystonia, choreic gait	10	High-frequency stimulation improved in dystonia, chorea. Low-frequency stimulation worsened truncal spasm.	Confirmed	Ruiz et al. ¹²⁾
39	F	Gait disturbance, orolingual dyskinesia, tongue protrusion, lip biting	4	High-frequency stimulation showed improvement in dystonia, bradykinesia.	Confirmed	Shin et al. ¹³⁾
39	M	Orofacial and lingual dyskinesia	22	Low-frequency stimulation improved choreic movement. High-frequency stimulation worsened symptoms.	Not confirmed	Li et al. ⁸⁾
30	M	Orofacial and lingual dyskinesia, tongue biting	12	Low-frequency stimulation improved choreic movement. High-frequency stimulation worsened symptoms.	Not confirmed	Li et al. ⁸⁾
54	M	Orofacial dyskinesia, feeding dystonia, trunk spasm	NA	High-stimulation improved mouth movement, truncal dips and gait.	Confirmed	Kefalopoulou et al. ⁷⁾
43	M	Oromandibular dyskinesia, dysarthria, gait disturbance	NA	High-frequency stimulation improved choreic movement and truncal spasm.	Confirmed	Kefalopoulou et al. ⁷⁾

ChAc : chorea-acanthocytosis, GPI : globus pallidus interna, DBS : deep brain stimulation, NA : not available

lasted for two years during the follow-up period. This result supports the usefulness of DBS for symptomatic treatment in cases of ChAc, however, there are still few data regarding long term benefit (Table 2).

DBS has been used in treatment of hyperkinetic movement disorders, including dystonia and L-dopa induced dyskinesia in Parkinson's disease. DBS has recently been employed for relief of symptoms of chorea in patients with Huntington's disease and ChAc. In patients with ChAc, a paucity of case reports of DBS have demonstrated improvements in chorea and activities of daily living, although with some variability in treatment outcome. Only one published case has reported no benefit from DBS¹⁴⁾.

One published case of a patient with ChAc reported improvement in choreic movements following DBS of the ventralis oralis posterior nucleus of the thalamus³⁾. However, GPI is a more preferable target for treatment of primary dystonia or neuroacanthocytosis and almost all therapeutic effects were obtained by GPI-DBS. The optimal stimulation parameters remain debatable. High-frequency stimulation has been reported to be effective not only in generalized dystonia, but also in several cases of Huntington's disease^{1,10)}, senile chorea¹⁵⁾, and cerebral palsy²⁾. In agreement with a few reports^{7,12,13)}, our patient showed improvement of his symptoms with high-frequency stimulation (130

Hz). However, the opposite has been reported in some cases of ChAc, where improvement was only achieved with low-frequency stimulation (40 Hz) with worsening at high-frequency stimulation (130 Hz)^{5,8)}. The exact reason for these contrasting effects is unclear and conduct of further studies will be needed.

Few studies have reported on the long-term effect of DBS in treatment of ChAc. Miquel et al.⁹⁾ recently reported a significant long-term improvement of motor symptom severity (improvement $\geq 20\%$ in UHDRS-motor score) in 61.5% of patients at a mean follow-up period of 2.5 years. They found that gait improvement, orofacial movements and tics, head drops, and trunk spasms were DBS-sensitive symptoms, while dysarthria and feeding problems were less responsive. In our case, during long-term follow-up, the patient showed improvement of 42.3% within one year and 39.0% within two years after surgery. Among his various symptoms, abnormal truncal flexion, tongue and lip biting showed marked improvement within several months after surgery, while dysarthria did not show significant improvement. Resistance to treatment or even worsening of dysarthria has been commonly described in DBS. This has been attributed to the adverse effect of DBS⁹⁾ or progression of the disease.

CONCLUSION

ChAc is a rare autosomal recessive disorder characterized by generalized chorea and morphological abnormalities in red blood cells. It presented with orofaciolingual dyskinesia, gait disturbance, and behavioral disturbance. However, the optimal treatment for ChAc is still unclear. Medical treatment is usually ineffective and DBS has been tried in management of ChAc. In recently reported cases, including the one reported here, DBS of the GPi resulted in significant improvement of symptoms in ChAc. Although DBS cannot cure all symptoms of ChAc, it can improve the quality of life for patients. Therefore, DBS is a valuable treatment option and should be considered as a treatment option for ChAc patients who are refractory to medical therapy.

• Acknowledgements

The authors would like to thank Chang-Seok Ki, MD, at the Department of Laboratory Medicine and Genetics, Samsung Medical Center, who contributed to genetic confirmation for ChAc. We also appreciate the efforts of Myung-Sik Lee, MD, and Chul-Hyoung Lyoo, MD from the Department of Neurology, Gangnam Severance Hospital, in preparation of the scanning electron microscopic image.

References

1. Bereznai B, Steude U, Seelos K, Bötzel K : Chronic high-frequency globus pallidus internus stimulation in different types of dystonia : a clinical, video, and MRI report of six patients presenting with segmental, cervical, and generalized dystonia. *Mov Disord* 17 : 138-144, 2002
2. Berweck S : BP-DBS for dystonia-choreoathetosis cerebral palsy. *Lancet Neurol* 8 : 692-693, 2009
3. Burbaud P, Rougier A, Ferrer X, Guehl D, Cuny E, Arne P, et al. : Improvement of severe trunk spasms by bilateral high-frequency stimulation of the motor thalamus in a patient with chorea-acanthocytosis. *Mov Disord* 17 : 204-247, 2002
4. Dobson-Stone C, Velayos-Baeza A, Filippone LA, Westbury S, Storch A, Erdmann T, et al. : Chorein detection for the diagnosis of chorea-acanthocytosis. *Ann Neurol* 56 : 299-302, 2004
5. Guehl D, Cuny E, Tison F, Benazzouz A, Bardinet E, Sibon Y, et al. : Deep brain pallidal stimulation for movement disorders in neuroacanthocytosis. *Neurology* 68 : 160-161, 2007
6. Hardie RJ, Pullon HW, Harding AE, Owen JS, Pires M, Daniels GL, et al. : Neuroacanthocytosis. A clinical, haematological and pathological study of 19 cases. *Brain* 114 (Pt 1A) : 13-49, 1991
7. Kefalopoulou Z, Zrinzo L, Aviles-Olmos I, Bhatia K, Jarman P, Jahanshahi M, et al. : Deep brain stimulation as a treatment for chorea-acanthocytosis. *J Neurol* 260 : 303-305, 2013
8. Li P, Huang R, Song W, Ji J, Burgunder JM, Wang X, et al. : Deep brain stimulation of the globus pallidus internal improves symptoms of chorea-acanthocytosis. *Neurol Sci* 33 : 269-274, 2012
9. Miquel M, Spampinato U, Latxague C, Aviles-Olmos I, Bader B, Bertram K, et al. : Short and long term outcome of bilateral pallidal stimulation in chorea-acanthocytosis. *PLoS One* 8 : e79241, 2013
10. Moro E, Lang AE, Strafella AP, Poon YY, Arango PM, Dagher A, et al. : Bilateral globus pallidus stimulation for Huntington's disease. *Ann Neurol* 56 : 290-294, 2004
11. Rampoldi L, Dobson-Stone C, Rubio JP, Danek A, Chalmers RM, Wood NW, et al. : A conserved sorting-associated protein is mutant in chorea-acanthocytosis. *Nat Genet* 28 : 119-120, 2001
12. Ruiz PJ, Ayerbe J, Bader B, Danek A, Sainz MJ, Cabo I, et al. : Deep brain stimulation in chorea acanthocytosis. *Mov Disord* 24 : 1546-1547, 2009
13. Shin H, Ki CS, Cho AR, Lee JJ, Ahn JY, Lee JH, et al. : Globus pallidus interna deep brain stimulation improves chorea and functional status in a patient with chorea-acanthocytosis. *Stereotact Funct Neurosurg* 90 : 273-277, 2012
14. Wihl G, Volkmann J, Allert N, Lehrke R, Sturm V, Freund HJ : Deep brain stimulation of the internal pallidum did not improve chorea in a patient with neuro-acanthocytosis. *Mov Disord* 16 : 572-575, 2001
15. Yianni J, Nandi D, Bradley K, Soper N, Gregory R, Joint C, et al. : Senile chorea treated by deep brain stimulation : a clinical, neurophysiological and functional imaging study. *Mov Disord* 19 : 597-602, 2004