

## Case Report

# Undetected Metallic Chopstick Stabbed on Neck Resulting Tinnitus and Foreign Body Sensation

Sun A Choi, M.D.,<sup>1</sup> Sung Bum Kim, M.D.,<sup>2</sup> Seung Youp Shin, M.D.,<sup>1</sup> Young Gyu Eun, M.D.<sup>1</sup>

Departments of Otorhinolaryngology-Head and Neck Surgery,<sup>1</sup> Neurosurgery,<sup>2</sup> School of Medicine, Kyung Hee University, Seoul, Korea

Penetrating neck injuries constitute 5–10% of all trauma cases. These injuries may cause life-threatening suppurative or vascular complications, but the severity and extent of damage depends upon the inflicting object and the involved structures. If significant complications are not expected, then it is best to leave the foreign body embedded and avoid surgical risks. We present a rare case of a foreign body embedded in the neck causing tinnitus and foreign body sensation.

**Key Words** : Foreign body · Stabb · Tinnitus · Neck.

## INTRODUCTION

Penetrating neck wounds caused by bullets or sharp tools account for 5% to 10% of all injuries<sup>3)</sup>. Without appropriate care, the injury can cause death; thus, penetrating neck injuries are among the most critical injuries. The neck comprises several complex structures including the distal carotid artery, vertebral artery, parotid gland, pharynx, the ninth through twelfth spinal cord segments, and a cranial nerve located between the mandible and skull base. Exposure of these anatomical structures is challenging and risky; therefore, unless significant complications are expected, surgical excision is not recommended owing to the risk of surgical complications.

In this case report, we describe a foreign body embedded in the neck for a long period of time that was diagnosed radiographically, and we provide a review of the relevant literature.

## CASE REPORT

A 59-year-old man donated a kidney 8 months prior to evaluation. He later reported a foreign body sensation in his neck, mild to severe cervical, shoulder, and chest pain, as well as tinnitus. He described the tinnitus as a “ssuk-saek” sound, and the symptom worsened when the patient turned his head. Pure tone audiometry was normal in both ears, at 10 dB in the right ear and 12 dB in the left ear. However, there was high tone loss in the 4 kHz

to 8 kHz range, and tinnitus in the right ear at 50 dB and in the left at 30 dB. An evoking otoacoustic emission test of transient tone revealed that the average radiating sound intensity was 8.4 dB in the right ear and 2.5 dB in the left ear. The 0–6 kHz reproducibility was 90% in the right ear and 76% in the left ear. The converted otoacoustic emission test had a lower response in the left ear. A laryngeal exam revealed arytenoid edema and pseudosulcus of the true vocal cord.

We suspected laryngopharyngeal reflux and prescribed lansoprazole (30 mg, 28 days), but the patient's symptoms did not resolve. Cervical computed tomography (CT) was performed, but no significant findings were noted. The patient was sent for evaluation by the neurosurgery department, and cervical disc disease was suspected. Subsequent cervical radiography and interpretation of previous CT data on a bone setting revealed a broken metallic foreign body 3-mm wide and 4.8-cm long within the right infratemporal fossa (Fig. 1, 2).

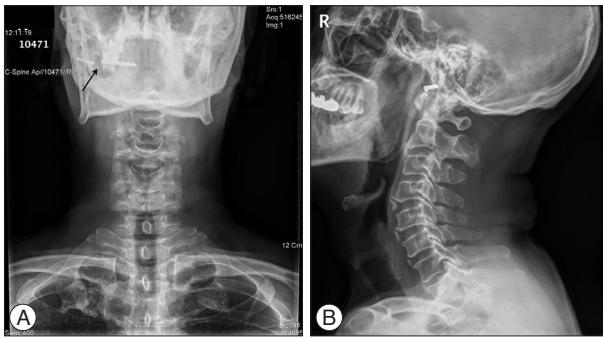
We queried the patient further, and he recalled falling while holding a metal chopstick. The chopstick broke, but its tip was never found. After the accident, he reported no symptoms except momentary pain. There was no infection, edema, or severe neurologic deficit associated with the lesion; therefore, the foreign body was left embedded for several decades. The patient and his guardian declined surgical excision of the object and elected long-term monitoring.

• Received : November 6, 2013 • Revised : April 1, 2014 • Accepted : April 6, 2014

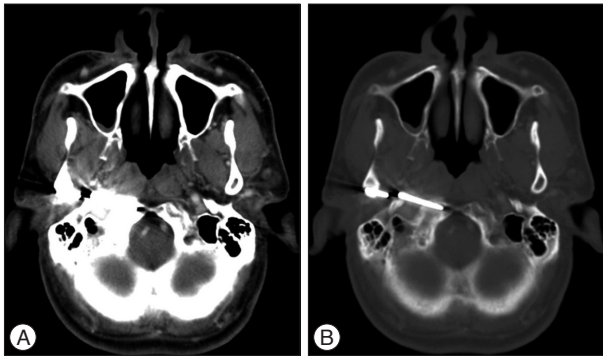
• Address for reprints : Sung Bum Kim, M.D.

Department of Neurosurgery, Kyung Hee University Medical Center, 23 Kyungheedaero, Dongdaemun-gu, Seoul 130-872, Korea  
Tel : +82-2-958-8402, Fax : +82-2-958-8380, E-mail : sungbumi7@hanmail.net

• This is an Open Access article distributed under the terms of the Creative Commons Attribution Non-Commercial License (<http://creativecommons.org/licenses/by-nc/3.0>) which permits unrestricted non-commercial use, distribution, and reproduction in any medium, provided the original work is properly cited.



**Fig. 1.** A radiopaque foreign body (arrow) is evident on anteroposterior (A) and lateral (B) radiographic views.



**Fig. 2.** A : Axial computed tomography (CT) did not initially reveal any significant finding. B : Once the CT image was switched to a bone setting, a metallic foreign body traversing the right infratemporal fossa was observed.

## DISCUSSION

In the field of otorhinolaryngology (head and neck surgery), an injury such as a foreign body embedded in the body because of carelessness or an accident is common. Foreign bodies can be surgically excised, but surgery has associated risks of complication and may require exploration of deep neck structures<sup>1</sup>.

Several reports have described that a fish bone lodged deep in the neck can be displaced into the thyroid gland, neck musculature, or parapharynx by deglutition movements or neck muscle contractions<sup>2,4,6,12,15</sup>. A previous study described a wire penetrating the piriform fossa into the thyroid gland towards the right posterior<sup>10</sup>, and there have also been reports of an external auditory canal foreign body infiltrating the jugular bulb and parapharynx<sup>9,14</sup>. Yet another report described the case of an infant who experienced mental deterioration and left hemiparesis after falling while biting a chopstick despite a clear penetrating wound never being found<sup>8</sup>. Most prior cases of foreign body injury resulted from careless negligence, and the foreign body was usually surgically removed shortly after the injury occurred.

However, if a foreign body remains embedded for a long period of time, it may induce pressure damage and cause infection. Allergic reactions, granulomatous inflammation, tissue necrosis, and reactive lymph node proliferation may occur secondarily. In addition to the local histologic response, symptoms such as tinnitus, foreign body sensation, voice change, persistent neck

pain, and odynophagia may occur.

Tinnitus is a significant symptom that commonly follows head and neck trauma because of auditory nerve, cochlea, tympanic membrane, or ossicular chain damage<sup>7</sup>. In the present case, the tinnitus worsened every time the patient turned his head, which may reflect neuromuscular alterations in the tissue surrounding the foreign body.

The infratemporal fossa (ITF) is located deep to the infratemporal crest, continues superiorly towards the temporal fossa and temporalis muscle, and inferiorly towards the parapharyngeal space. The osseous boundaries are the posterolateral maxillary surface anteriorly, the lateral pterygoid plate anteromedially, the mandibular ramus laterally, and the tympanic temporal bone and styloid process posteriorly. The ITF contains the maxillary artery, the trigeminal nerve mandibular branch, the pterygoid muscles, and the pterygoid venous plexus. Owing to its deep position, masses in the ITF may grow for a considerable time before symptoms occur, often delaying diagnosis. Access to the area is challenging, but adequate surgical exposure is critical for the excision of large ITF tumors<sup>13</sup>.

The ITF is divided into prestyloid and retrostyloid regions. The former contains facial and trigeminal nerves, and the latter contains the internal carotid artery, jugular foramen, and the ninth through twelfth cranial nerves<sup>5</sup>. A foreign body within the prestyloid process can cause trismus as well as mandibular and pharyngeal wall swelling. A foreign body within the retrostyloid process can cause systemic symptoms such as fever and chill.

In the case we described, there was no evidence of skull fracture or external injury, and the patient could not recall the traumatic event; the foreign body likely resided in the tissue for an extended period of time. The location adjacent to the bone structure may have delayed diagnosis; the foreign body was revealed only after switching the cervical CT data to a bone setting. In a similar case report, a mysterious transverse sinus foreign body remained asymptomatic for over 20 years<sup>11</sup>.

Because the foreign body was made of metal, suppurative inflammation typical of organic material such as wood was absent; only cervical lymph node reactive proliferation was observed. Moreover, the patient experienced only mild symptoms, and he and his guardian declined surgical excision. Leaving the foreign body embedded is preferred over infratemporal fossa exposure, due to the risk of considerable neurologic and vascular complications.

In a neck injury patient experiencing nonspecific symptoms, a thorough otolaryngologic history, physical examination, and radiography or computed tomography can enable diagnosis. Furthermore, the foreign body can remain embedded in the body without major somatic damage; however, routine monitoring is needed.

## CONCLUSION

We reported the rare case of metallic chopstick embedded in

the neck for several decades, and tried to find out the possibility of correlation with tinnitus and foreign body sensation. We also presumed the entrance pathway of foreign body into infratemporal fossa.

We assumed that careful history taking, detailed physical examination, and proper radiologic study may important tool for detection and evaluation of foreign body, which is located in important structure of our body.

## References

1. Ahmad R, Pampori RA, Wani AA, Qazi SM, Abdul Ahad SA : Transcervical foreign body. *J Laryngol Otol* 114 : 471-472, 2000
2. al Muhanna A, Abu Chra KA, Dashti H, Behbehani A, al-Naqeeb N : Thyroid lobectomy for removal of a fish bone. *J Laryngol Otol* 104 : 511-512, 1990
3. Bailey BJ, Johnson JT, Newland SD, Stewart MG : Penetrating face and neck trauma in Bailey BJ, Johnson JT, Newlands SD (eds) : **Head and Neck Surgery-Otolaryngology**, ed 4. Philadelphia : Lippincott Williams & Wilkins, 2006, pp1070
4. Bendet E, Horowitz Z, Heyman Z, Faibel M, Kronenberg J : Migration of fishbone following penetration of the cervical esophagus presenting as a thyroid mass. *Auris Nasus Larynx* 19 : 193-197, 1992
5. Cosan TE, Arslantas A, Guner AI, Vural M, Kaya T, Tel E : Injury caused by deeply penetrating knife blade lodged in infratemporal fossa. *Eur J Emerg Med* 8 : 51-54, 2001
6. Feldhusen F, Braunbeck T, Wallner F : [Dysphagia after eating sea foods. Pyriform sinus foreign body with perforation and abscess of the parapharyngeal space]. *HNO* 47 : 746-747, 1999
7. Folmer RL, Griest SE : Chronic tinnitus resulting from head or neck injuries. *Laryngoscope* 113 : 821-827, 2003
8. Jin HJ, Yu JS, Kim YK, Gang HS, Lee SJ : Medulla oblongata injury caused by non-penetrating trauma by chopsticks. *Yeungnam Univ J Med* 27 : 122-126, 2010
9. Jones RL, Chavda SV, Pahor AL : Parapharyngeal abscess secondary to an external auditory meatus foreign body. *J Laryngol Otol* 111 : 1086-1087, 1997
10. Murthy PS, Bipin TV, Ranjit R, Murty KD, George V, Mathew KJ : Extraluminal migration of swallowed foreign body into the neck. *Am J Otolaryngol* 16 : 213-215, 1995
11. Oh CH, Hyun D : Mysterious foreign body in transverse sinus. *J Korean Neurosurg Soc* 51 : 167-169, 2012
12. Osinubi OA, Osiname AI, Pal A, Lonsdale RJ, Butcher C : Foreign body in the throat migrating through the common carotid artery. *J Laryngol Otol* 110 : 793-795, 1996
13. Otremba M, Adam S, Omay SB, Lowlicht R, Bulsara KR, Judson B : Maxillary swing approach for extended infratemporal fossa tumors. *Laryngoscope* 123 : 1607-1611, 2013
14. Park CH, So SH, Kim HJ, Lim HJ : A Case of Jugular Bulb Injury by the External Ear Foreign Body. *Korean J Otolaryngol-Head Neck Surg* 42 : 1183-1185, 1999
15. Shim WY, Jeong WH, Park JB, Kim CA, Baik SK : Two cases of fish bone foreign body presenting as tongue and neck mass. *Korean J Otolaryngol-Head Neck Surg* 44 : 556-559, 2001