

## Case Report

# Delayed Traumatic Diaphragm Hernia after Thoracolumbar Fracture in a Patient with Ankylosing Spondylitis

Hyoun-Ho Lee, M.D., Ikchan Jeon, M.D., Sang Woo Kim, M.D., Young Jin Jung, M.D.

Department of Neurosurgery, College of Medicine, Yeungnam University, Daegu, Korea

Traumatic diaphragm hernia can occur in rare cases and generally accompanies thoracic or abdominal injuries. When suffering from ankylosing spondylitis, a small force can develop into vertebral fracture and an adjacent structural injury, and lead to diaphragm hernia without accompanying concomitant thoracoabdominal injury. A high level of suspicion may be a most reliable diagnostic tool in the detection of a diaphragm injury, and we need to keep in mind a possibility in a patient with ankylosing spondylitis and a thoracolumbar fracture, even in the case of minor trauma.

**Key Words :** Diaphragm hernia · Ankylosing spondylitis · Delayed · Thoracolumbar fracture.

## INTRODUCTION

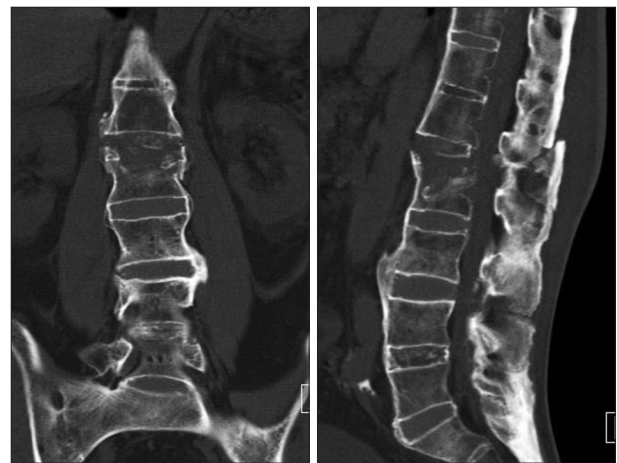Diaphragm hernia usually develops as a consequence of high velocity blunt trauma such as in a vehicular accidents, fall, or from a penetrating injury such as stabbing or upper abdominal surgery<sup>1,4,10,18,19</sup>. A wide range of associated injuries (hepatic, pelvic, bowel, renal, splenic, spine or thoracic lesions) are commonly present in patients with diaphragmatic injury, even though it can occur in isolation without any associated abdominal trauma<sup>2,22</sup>. In major trauma victims, acute diaphragm injury may go unnoticed, and there is often a delay between the injury and the diagnosis, which can lead to poor outcomes. The diagnosis is usually made intra-operatively<sup>14</sup>.

In this article, we present a rare case of delayed diaphragm hernia after an operation for a thoracolumbar fracture caused by a minor pedestrian accident in a patient with ankylosing spondylitis.

## CASE REPORT

A 71-year-old man who presented with back pain and lower extremity weakness after a minor pedestrian accident was admitted through emergency room in our hospital. Radiological studies including computed tomography (CT) (Fig. 1) and mag-

netic resonance (MR) images showed chance fracture on L2 with syndesmophyte, bamboo spine and sacroiliitis, implying ankylosing spondylitis. He underwent posterior fusion and pedicle screw fixation from T12 to L3 level with allo- and auto-graft bone five days later since the accident, recovered from neurologic deficit and became an ambulatory.



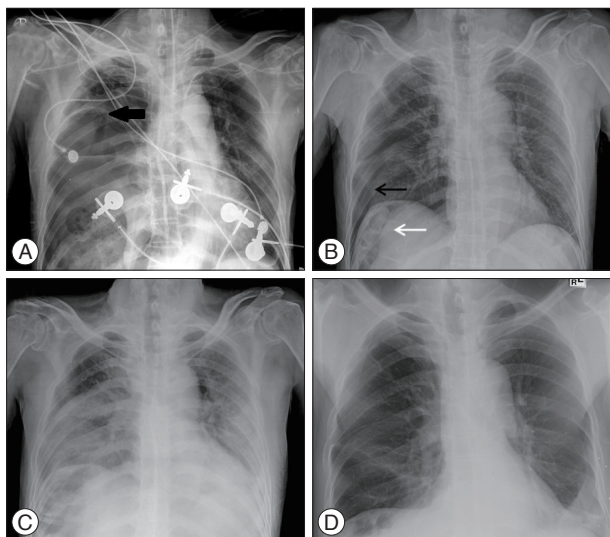
**Fig. 1.** Chance fracture on the L2, presenting on preoperative CT scan. There are fractures of the lamina, spinous process, and vertebral body with a canal compromise on CT scan. The findings of ankylosing spondylitis including syndesmophyte, bamboo spine are shown in CT scan.

• Received : February 23, 2014 • Revised : June 30, 2014 • Accepted : August 18, 2014

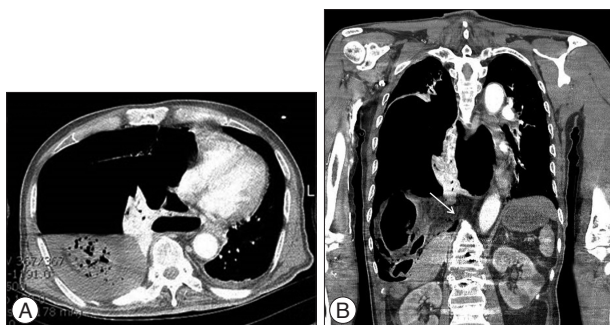
• Address for reprints : Ikchan Jeon, M.D.

Department of Neurosurgery, Yeungnam University Medical Center, Yeungnam University College of Medicine, 170 Hyeonchung-ro, Nam-gu, Daegu 705-802, Korea  
Tel : +82-53-620-3790, Fax : +82-53-620-3770, E-mail : jicns@hanmail.net

• This is an Open Access article distributed under the terms of the Creative Commons Attribution Non-Commercial License (<http://creativecommons.org/licenses/by-nc/3.0>) which permits unrestricted non-commercial use, distribution, and reproduction in any medium, provided the original work is properly cited.



**Fig. 2.** There are air shadows (large black arrow) in the right hemithorax and trachea deviation to the left side on the chest X-ray at the time of arrest (about 6 weeks later from the accident) (A). Pneumothorax (black arrow) and a 9th rib fracture (white arrow) of the right hemithorax in the initial chest X-ray at the time of admission (B) and postoperative aggravation (C). Two weeks later, the improved status of atelectasis and consolidation is showing on the follow-up chest X-ray (D).



**Fig. 3.** A : A chest CT scan shows the viscerothorax containing large bowel and fluid collection in the right hemithorax after the sudden arrest. The heart and lungs are deviated to the opposite side by the herniated abdominal contents. B : There are disruption of the right crus (white arrow) from vertebra body compare to the left crus and extensive destruction of right hemidiaphragm and peri-vertebral structures.

One month later (postoperatively), a yellow-colored serous fluid was discharging at the operation site. Under the impression of postsurgical infection, wound revision and inspection were performed. There was no definite infectious sign except some granulation tissues around the incision site and implants. After two weeks, the revision wound was clearly healed and there were no specific signs except intermittent abdominal discomfort; however, the patient suddenly complained of severe abdominal pain and dyspnea a further two weeks later, which led to cardiac arrest. In a review of previous chemical and radiological studies, a suspicious air shadow was found in the right hemithorax on the chest X-ray that was performed just prior to the arrest (Fig. 2A). Under the possibility of diaphragmatic rupture, abdominal CT scan was performed and we found that the large bowel had herniated through the defect of the right hemi-diaphragm, displac-

ing the lung and heart to the opposite side (Fig. 3).

The patient underwent an emergency operation after the recovery of vital signs through cardiopulmonary resuscitation. There were perforations in the right colon with fecal materials in the right pleural cavity, and a two-finger-width defect between the tendon and muscle portions with the erosive changes in the medial side of right hemi-diaphragm and the adjacent structures nearby the vertebrae. An extended right hemicolectomy, a wedge resection of right lower lung segment, and a repair of diaphragm with repositioning of the herniated bowel were performed. The patient did not recover and expired because of the septic condition.

## DISCUSSION

Diaphragmatic hernia is an uncommon condition that typically occurring in 1 to 7% of patients with major blunt trauma and 10 to 15% of patients with penetrating trauma<sup>17</sup>.

A sudden high velocity force is required to rupture the diaphragm. Blunt trauma to the abdomen increases the trans-diaphragmatic pressure gradient between the abdominal and the thoracic compartments. The differential pressure between the abdominal and thoracic cavities with the positive intra-abdominal pressure and negative intra-thoracic pressure during a respiration encourages the movement of abdominal viscera into the thoracic cavity<sup>16,23</sup>. The delayed rupture of a diaphragm may occur several days after the initial injury. The devitalization of the diaphragm muscle caused by the initial injury continues as a barrier until the inflammatory process weakens and ruptures it. Tension viscerothorax results in the reduction of venous return to the heart and diminished cardiac output<sup>20</sup>.

The fact that a diagnosis of diaphragm rupture following trauma is often delayed has been reported by several authors. Moreover, chest radiographs miss up to half of penetrating diaphragmatic ruptures and most patients remain with non-specific symptoms<sup>14,21</sup>. However, the more acceptable explanation for the delayed detection of diaphragmatic defects is that the injury usually only manifests when the herniation occurs<sup>12</sup>. Patients with an undiagnosed rupture of the diaphragm can develop symptoms after a delay of weeks, months, or even years<sup>6</sup>. There are no gold diagnostic methods with a high sensitivity or specificity. The audible bowel sounds on the chest auscultation suggest displaced bowel loops. Although the chest X-ray is the first line of investigation and sequential imaging increases sensitivity, with a finding of unusual gas shadow in the lower chest due to a portion of the colon and the small intestine being transposed into the right hemithorax, additional radiologic studies such as CT scan should be required to rule out the fatal injuries<sup>9,13</sup>. Nevertheless, a high index of suspicion is the most important tool for proper diagnosis<sup>8</sup>. Diagnostic delay may result in an increased morbidity and mortality, because of a displacement of abdominal organs is more common in delayed hernias<sup>16,25</sup>. The presence of strangulation with gangrene and perforation was related to increased morbidity and mortality. Mortality rate of undergone emergency repairs

in this condition was up to 32%<sup>5</sup>).

Although autopsy studies have revealed equal incidence of right and left diaphragmatic ruptures, antemortem reports suggest 88–95% of diaphragmatic ruptures occurred on the left side<sup>4</sup>. This could be explained by better visualization of the left diaphragm on diagnostic laparoscopy but restricted visualization of the right diaphragm<sup>24</sup>. And right sided ruptures are associated with high mortality and morbidity, so the under diagnosis of right sided injuries may be due to high incidence of mortality<sup>4</sup>. However, the protective effect of the liver also contributes the left sided diaphragmatic tear dominant<sup>3,11</sup>. The stomach is the most common affected organ due to its proximity to the relatively unprotected left dome of the diaphragm<sup>7</sup>.

In this case, there were initially a 9th rib fracture and a small amount of pneumothorax on the right hemithorax (Fig. 2B, C), though that was not evaluated with more advanced imaging tools (there was no relation between the rib fracture and the diaphragm injury on the CT scan that was performed at the time of cardiac arrest). However, we overlooked an important clue including unusual gas pattern in the lower zone of right hemithorax that had been sustained by two weeks postoperatively, even though a pneumothorax lesion had disappeared (Fig. 2D). We think that the serous-natured, yellow-colored fluid discharge at the operation site may have originated from the pleural cavity through the injured diaphragm and the passage made by a dehiscence of adjacent structures such as crus around the fractured vertebra. There was another clue we overlooked, that intermittent abdominal discomfort was presented during the second post-operation period. At that time, we should have recognized that bowel strangulation and ischemia had developed and progressed.

We think that the serous-natured, yellow-colored fluid discharge at the operation site may have originated from the pleural cavity through the injured diaphragm and the passage made by a dehiscence of adjacent structures such as crus around the fractured vertebra. There was another clue we overlooked, that intermittent abdominal discomfort was presented during the second post-operation period. At that time, we should have recognized that bowel strangulation and ischemia had developed and progressed.

We can assume two possibilities for the formation of the diaphragmatic defect in this case. The first is that the initial small injuries in the diaphragm and the adjacent structures around the fractured vertebra were developed by the combination of vertebral fracture and steep pressure gradient between the abdomen and thorax. We guess a blunt trauma which is sufficient to develop 9th rib fracture and pneumothorax was occurred in the right hemithorax at the time of the accident. The initial small injuries occurred silently without any clinical signs and extended into a larger one, which was accelerated with positional changes and ambulation. On the other hand, there was no possibility of operation-induced diaphragm hernia. The sudden onset natured symptoms (such as chest X-ray changes and respiration) related with extensive destruction of adjacent structures around the fractured vertebrae which was extended into diaphragm after the operation

were required to explain the associations related with the operation. The operation was only performed with posterior fusion.

Another one is based on the decrease of expansion and flexibility in the thoracic cavity under the condition of ankylosing spondylitis. In this condition, we think that the diaphragm can also become stiffer than a normal one, which may be a major causal factor of diaphragmatic tear from minor blunt injury. Ragnarsdottir et al.<sup>15</sup> reported that respiratory movements among patients with ankylosing spondylitis are primarily decreased in the upper part of the thorax. Otherwise, they still have a good ability to move their lower thoracic wall, and their abdominal wall movements were increased. This probably indicates that patients with ankylosing spondylitis are able to compensate for their limited upper thoracic expansion by increasing diaphragmatic movement.

In conclusion, we think that the predisposing factors related with ankylosing spondylitis we mentioned above and the concomitant injuries of adjacent peri-vertebral structures under thoracolumbar fracture may have play a major role in the delayed diaphragmatic hernia in this patient.

## CONCLUSION

A high level of suspicion and additional CT scan in the cases with abnormal chest X-ray can be reliable diagnostic tools for the detection of diaphragm injuries. We need to be more concerned with identifying the state of diaphragm, particularly when we treat a patient with thoracolumbar fracture who is suffering from ankylosing spondylitis, even after minor trauma.

## References

1. Beaunoyer M, St-Vil D, Lallier M, Blanchard H : Abdominal injuries associated with thoraco-lumbar fractures after motor vehicle collision. *J Pediatr Surg* 36 : 760-762, 2001
2. Brasel KJ, Borgstrom DC, Meyer P, Weigelt JA : Predictors of outcome in blunt diaphragm rupture. *J Trauma* 41 : 484-487, 1996
3. Disler DG, Deluca SA : Traumatic rupture of the diaphragm and herniation of the liver. *Am Fam Physician* 46 : 453-456, 1992
4. Goh BK, Wong AS, Tay KH, Hoe MN : Delayed presentation of a patient with a ruptured diaphragm complicated by gastric incarceration and perforation after apparently minor blunt trauma. *CJEM* 6 : 277-280, 2004
5. Hacıbrahimoglu G, Solak O, Olcmen A, Bedirhan MA, Solmazer N, Gurses A : Management of traumatic diaphragmatic rupture. *Surg Today* 34 : 111-114, 2004
6. Ho MP, Wu YH, Tsai KC, Wu JM, Cheung WK : Delayed herniation of intra-abdominal contents after blunt right-sided diaphragm rupture. *Am J Emerg Med* 30 : 2089.e1-2089.e3, 2012
7. Hoffman E : Strangulated diaphragmatic hernia. *Thorax* 23 : 541-549, 1968
8. Hsee L, Wigg L, Civil I : Diagnosis of blunt traumatic ruptured diaphragm : is it still a difficult problem? *ANZ J Surg* 80 : 166-168, 2010
9. Humphreys TR, Abbuhl S : Massive bilateral diaphragmatic rupture after an apparently minor automobile accident. *Am J Emerg Med* 9 : 246-249, 1991
10. Kao Y, Lee WJ, Lin HJ : Tension gastrothorax : a life-threatening cause of acute abdominal pain. *CMAJ* 180 : 983, 2009
11. Kelly J, Condon E, Kirwan W, Redmond H : Post-traumatic tension fae-

- copneumothorax in a young male : case report. *World J Emerg Surg* 3 : 20, 2008
12. Meyers BF, McCabe CJ : Traumatic diaphragmatic hernia. Occult marker of serious injury. *Ann Surg* 218 : 783-790, 1993
  13. Muroi M, Provenza G, Conte S, Sagnotta A, Petrucciani N, Gentili I, et al. : Diaphragmatic rupture with right colon and small intestine herniation after blunt trauma : a case report. *J Med Case Rep* 4 : 289, 2010
  14. Onakpoya U, Ogunrombi A, Adenekan A, Akerele W : Strangulated tension viscerothorax with gangrene of the stomach in missed traumatic diaphragmatic rupture. *ISRN Surg* 2011 : 458390, 2011
  15. Ragnarsdottir M, Geirsson AJ, Gudbjornsson B : Rib cage motion in ankylosing spondylitis patients : a pilot study. *Spine J* 8 : 505-509, 2008
  16. Rashid F, Chakrabarty MM, Singh R, Iftikhar SY : A review on delayed presentation of diaphragmatic rupture. *World J Emerg Surg* 4 : 32, 2009
  17. Reber PU, Schmied B, Seiler CA, Baer HU, Patel AG, Büchler MW : Missed diaphragmatic injuries and their long-term sequelae. *J Trauma* 44 : 183-188, 1998
  18. Saboe LA, Reid DC, Davis LA, Warren SA, Grace MG : Spine trauma and associated injuries. *J Trauma* 31 : 43-48, 1991
  19. Santschi M, Echavé V, Laflamme S, McFadden N, Cyr C : Seat-belt injuries in children involved in motor vehicle crashes. *Can J Surg* 48 : 373-376, 2005
  20. Shah R, Sabanathan S, Mearns AJ, Choudhury AK : Traumatic rupture of diaphragm. *Ann Thorac Surg* 60 : 1444-1449, 1995
  21. Shreck GL, Toalson TW : Delayed presentation of traumatic rupture of the diaphragm. *J Okla State Med Assoc* 96 : 181-183, 2003
  22. Soundappan SV, Holland AJ, Cass DT, Lam A : Diagnostic accuracy of surgeon-performed focused abdominal sonography (FAST) in blunt paediatric trauma. *Injury* 36 : 970-975, 2005
  23. Walchalk LR, Stanfield SC : Delayed presentation of traumatic diaphragmatic rupture. *J Emerg Med* 39 : 21-24, 2010
  24. Warren O, Kinross J, Paraskeva P, Darzi A : Emergency laparoscopy--current best practice. *World J Emerg Surg* 1 : 24, 2006
  25. Wirbel RJ, Mutschler W : Blunt rupture of the right hemi-diaphragm with complete dislocation of the right hepatic lobe : report of a case. *Surg Today* 28 : 850-852, 1998