

RESEARCH ARTICLE

Hepatoprotective Effects of Curcumin Against Diethyl Nitrosamine Induced Hepatotoxicity in Albino Rats

Naif Mohammed Kadasa¹, Haytham Abdallah², Mohamed Afifi^{1,2*}, Salah Gowayed^{1,3}

Abstract

Curcumin is widely used as a traditional medicine. This work was aimed to investigate its possible protective effect against chemically induced hepatocellular carcinoma (HCC) in rats. Fifty male albino rats were divided into five groups (n=10, each). The control group received a single dose of normal saline, the diethylnitrosamine (DEN) group received a single intra-peritoneal dose at 200mg/kg body weight, and the 3rd, 4th and 5th groups were given DEN and daily administered curcumin (CUR) via intra-gastric intubation in doses of 300, 200 and 100 mg/kg b.wt. respectively for 20 weeks. Serum, and liver samples were used for determination of alpha fetoprotein (AFP), interleukin-2 (IL-2), interleukin-6 (IL-6), serum liver enzymes (AST, ALT, ALP and GGT) levels as well the activities and gene expression of glutathione peroxidase (GPx), glutathione reductase (GR), catalase (CAT) and super oxide dismutase (SOD). Curcumin significantly lowered the serum levels of AFP, IL-2 and IL-6, ALT, ALT, and malondialdehyde (MDA) as well gene expression of IL-2 and IL-6. In contrast it increased the gene expression and activities of GPx, GR, CAT and SOD. The protective effect of CUR against DEN-induced hepatocarcinogenesis in albino rats was proven.

Keywords: Hepatocellular carcinoma - hepatotoxicity - curcumin - antioxidant effects

Asian Pac J Cancer Prev, 16 (1), 103-108

Introduction

Hepatocellular carcinoma (HCC) is an aggressive cancer, it is one of the most frequent primary cancer of the liver at which its incidence rate has been increased to become the fifth most common malignancy worldwide (Zhong et al., 2014). The HCC incidence rate is one million cases every year (Liovet, et al., 2008). The pathogenesis of HCC is multifactorial, highly associated with many risk factors but it is mainly develops after exposition of the cellular machinery to a mutation that results in replication of the cell in higher rate and/or avoiding of apoptosis (Youns et al., 2013). The main way for HCC treatment is surgical resection and liver transplantation (Zekri et al., 2013; Zhang et al., 2013; Zhu et al., 2013). For unresectable HCC other methods were developed such as chemotherapies by interferon or 5 Fluoro-uracil (Parker et al., 2004). Bad prognosis and reoccurrence of HCC in most cases directed the most of recent studies toward the prevention of HCC by any method especially the use of natural foods or natural food additives as Curcumin, which has been used traditionally in medicine in India and other Asian countries (Zhaohui et al., 2013). It has a wide spectrum of biological and pharmaceutical activities,

as anti-inflammatory, Anti-infectious, anti-fungal, anti-viral, anti-mutagenic, anti-parasitic and anti-carcinogenic (Gopal et al., 2014). Many studies have demonstrated the anticancer effect of curcumin in a variety of tumors as pancreatic, breast, gastrointestinal and hepatic cancer (Preetha et al., 2008). Those data are now attracting the interest of many researchers for developing this agent as chemo-preventive or even chemotherapeutic drugs (Corson and Crews, 2007).

Materials and Methods

Materials

DENA (Diethyl nitrosamine) and Carbon tetrachloride were obtained from Sigma-Aldrich Co. (St. Louis, Missouri, USA). Curcumin, obtained in commercial form as capsules from Vitacost, USA. DENA was diluted in normal saline while carbon tetrachloride was diluted in corn oil

Experimental Design

All experimental procedures were approved by the Medical Research Ethics Committee of Zagazig University, Egypt.

¹Department of Biological Sciences, Faculty of Science, King Abdulaziz University, Jeddah, Saudi Arabia, ²Department of Biochemistry, Faculty of Veterinary Medicine, Zagazig University, Zagazig, ³Botany Department, Faculty of Agriculture, Suez Canal University, Ismailia, Egypt *For correspondence: mafifi@kau.edu.sa

Fifty male albino rats, weighing 120±20g each, were used. Animals were acclimatized under controlled conditions for two weeks before starting the experimental procedures. Rats were divided to five groups (n=10) for each group, control group received a single dose of normal saline, DENA bearing non-treated group received a single intra-peritoneal dose of DENA (200mg/Kg body weight) (Al-Rejaie, et al., 2009), the 3rd, 4th and 5th groups were DENA bearing treated group daily administrated curcunine via intra-gastric intubation in doses of 300,200 and 100 mg Kg-1 b.wt. respectively for 20 weeks.

Biochemical analysis At the end of experimental period, rats from all groups were sacrificed by decapitation under ether anesthesia; blood and liver samples were collected, serum was isolated and used for investigation of AFP using ELFA (Enzyme Linked Fluorescent Assay) technique using VIDAS® AFP kits (Catalogue number 30 413, BioMerieux, France), IL-2 and IL-6 that were determined using Abcam's IL-2 Rat ELISA kit (ab100769) and Abcam's IL6 Rat ELISA Kit (ab119548) respectively. Serum ALT, AST, ALP and γ-GT were determined using spectrum Kits (Egyptian Company for Biotechnology, Cairo, Egypt REF: 265 002, 261 002, 263002 and 264002) following the manufacture instructions. Hepatic tissue samples were used for homogenate preparation, for estimation of Malondialdehyde (MDA), CAT, SOD, GR and GPx activities (Ali et al., 2014).

Hestopathological analysis

Small parts of hepatic tissue were fixed in formalin buffered neutral solution, gradually dehydrated in ethanol (70-100%), then cleaned with xylene finally embedded in paraffin. Paraffin sections were prepared and stained with hematoxylin and eosin (HE) dyes (Bancroft and Gamble, 2008).

Molecular analysis

Total RNA was isolated from liver samples using the RNeasy Mini Kit Qiagen, Cat. No.74104. The amount of extracted RNA was quantified and qualified using NanoDrop® ND-1000 Spectrophotometer, NanoDrop Technologies, Wilmington, Delaware USA. The purity of RNA was checked and ranged between 1.8 and 2. 0.5µg of total RNA was used for production of cDNA using

QIAGEN LongRange 2Step RT-PCR Kit, Cat. No.205920. The PCR reaction was placed in a gradient T Professional thermo-cycler (Biometra, Germany). PCR conditions were a denaturation step at 95 °C for 4 min followed by 28 cycles of 95°C, 1 min; 55°C, 1 min; 72°C, 1 min for all genes except for IL-2 annealing temperature was 60°C. 10 ul of PCR products were analyzed on a 2% agarose gel stained with ethidium bromide in 1X Tris acetate EDTA buffer (TAE) pH 8.3-8.5 (Stock solution was 50X from Bioshop® Canada Inc. Burlington, ON. L7L6A4. Lot No. 1L22854). The electrophoretic picture was visualized and analyzed by gel documentation system (Bio Doc Analyze, Biometra, Germany). The Primer sequences (Table 1) of rat GPx, CAT, CuZnSOD, GR and β-actin were obtained from the published sequences (Ali et al., 2014), IL-2 and IL-6 (Olivier et al., 1995). The primers design was optimized for Polymerase Chain Reaction (PCR) with Eugene™ version 2.2 (Daniben Systems, Cincinnati, OH).

Statistical analysis

The obtained data were analyzed and graphically represented using the statistical package for social science (SPSS, 18.0 software, 2011) for obtaining means and standard error. Duncan's test was used for making a multiple comparisons among the groups for testing the inter-grouping homogeneity.

Results

In this work, we tested the antitumor effects of CUR against DEN inducerd hepatic tumorigenesis. Liver hestopathological changes, hepatic tumor markers and proinflammatory markers were tested and had been compared for the different animals groups.

Hestopathological examination of liver with HE

The control non-treated rats hepatic histological sections displayed the normal hepatic lobules organization, normal hepatocytes and sinusoidal architecture (Figure 1a). Although, DENA treated rats displayed Focal replacement of portal area with extensive fibrous C.T with islets of cholangioadenocarcinoma represented mainly by large biliary cells with destructed membrane, scanty

Table 1. Primer Sequences of Rats GPx, CAT, CuZnSOD, GR, IL-2, IL-6 and β-actin

Gene		Oligonucleotide sequences	Size (bp)	Gene ID
GPx	F	5'-CACAGTCCACCGTGTATGCC-3'	292	S50336.1
	R	5'-AAGTTGGGCTCGAACCCACC-3'		
CAT	F	5'-GTCCGATTCTCCACAGTCGC-3'	272	AH004967.1
	R	5'-CGCTGAACAAGAAAGTAACCTG-3'		
SOD	F	5'-ATGGGGACAATACACAAGGC-3'	225	Z21917.1
	R	5'-TCATCTTGTTTCTCGTGGAC-3'		
GR	F	5'-CCATGTGGTTACTGCACTTCC-3'	171	NM_053906
	R	5'- GTTCCTTCCTTCTCCTGAGC-3'		
IL-2	F	5'AACAGCGCACCCACTTCAA3'	400	NM_053836.1
	R	5'TTGAGATGATGCTTTGACA3'		
IL-6	F	5'CTCCCTACTTCACAAGTC3'	457	NM_012589.2
	R	5'CTCCATTAGGAGAGCATTG3'		
β-actin	F	5'-TCACTATCGGCAATGTGCGG-3'	260	NM_007393
	R	5'-GCTCAGGAGGAGCAATGATG-3'		

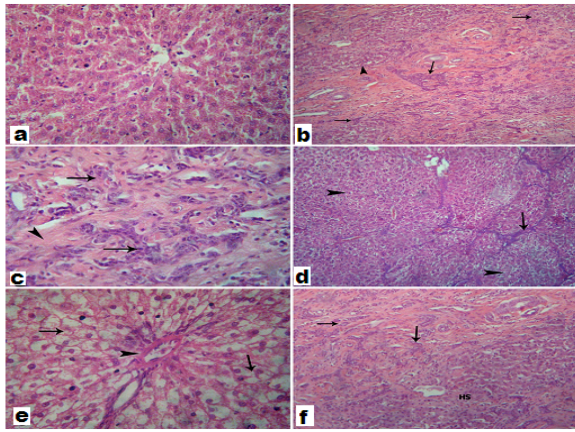


Figure 1. The histopathological finding a) liver of control group, show normal hepatocytes and sinusoidal architecture. b&c) livers of DENA-treated group, with H&E (100X) and H&E (400X) showing: Focal replacement of portal area with extensive fibrous C.T (arrow) with islets of cholangioadenocarcinoma represented mainly by large biliary cells with destroyed membrane, scanty basophilic cytoplasm and large vesicular nuclei beside numerous mitosis (arrow heads) with pressure atrophy of adjacent hepatocytes (small HS). liver of DENA bearing CUR treated rats (100, 200 and 300 mg/kg) showed diffuse hydrophobic degeneration, portal area shows hyalinization in the wall of blood vessels with no evidence of carcinogenesis (d). Scanty fibrous C.T proliferation (arrows) well developed in the portal tract forming incomplete bridge with no evidence of carcinogenesis (e), and limited extension of carcinogenesis and cholangioadenocarcinoma (large hepatic spares HS) (f)

basophilic cytoplasm and large vesicular nuclei beside numerous mitosis with pressure atrophy of adjacent hepatocytes (Figure 1 b,c). Compared with DEN-bearing non-treated rats, the DEN-bearing CUR-treated rats showed disappearance of cholangioadenocarcinoma, but the hepatic tissue still has a diffuse hydrophobic degeneration in portal area with scanty fibrous C.T. These lesions correlated with the CUR dose (Figure 1 d,e, f).

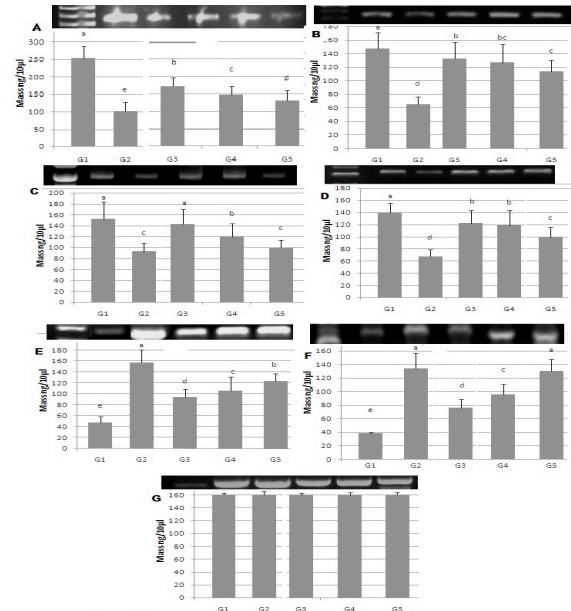


Figure 2. The electrophotograph of GPx (A), GR (B), SOD (C), CAT (D), IL-2 (E), IL-6 (F) and β -actin (G) gene expression in hepatic tissue. Columns with different letters are significant differ at $p \leq 0.05$

Table 2. The effect of Curcumin on Serum AFP, IL-2, IL-6, ALT, AST, ALP and GGT levels

	Control	DENA group	CUR group (300mg/kg)	CUR group (200mg/kg)	CUR group (100mg/kg)
α -FP (IU/ml)	3.49 \pm 0.5	268 \pm 17***	46 \pm 2**	76 \pm 3***	114 \pm 4**
IL-2 (ng/ml)	3.52 \pm 0.5	21 \pm 0.6***	11 \pm 0.3**	15 \pm 0.5***	17 \pm 0.5**
IL-6 (ng/ml)	3.1 \pm 0.2	22 \pm 0.6***	10 \pm 0.4**	14 \pm 0.4***	18 \pm 0.3**
ALT (U/L)	54.47 \pm 4	130 \pm 2***	60 \pm 1#	70 \pm 2**	99 \pm 3**
AST (U/L)	180 \pm 10	284 \pm 3***	185 \pm 3#	209 \pm 12**	251 \pm 5**
ALP (U/L)	142.66 \pm 5	217 \pm 2***	150 \pm 2#	187 \pm 4**	190 \pm 6**
GGT (U/L)	18.59 \pm 2	100 \pm 2***	20 \pm 1#	40 \pm 2**	71 \pm 5**

*Data is represented as Mean \pm S.D. * $p < 0.05$, ** $p < 0.01$, *** $p < 0.001$ (statistical significant compared to the control group); # $p < 0.05$, ## $p < 0.01$, ### $p < 0.001$ (statistical differ from DEN group)

Table 3. The Effect of Curcumin on Hepatic MDA and GSH Concentrations and Hepatic GPx, GR, SOD and CAT Activities

	Control	DENA group	CUR group (300mg/kg)	CUR group (200mg/kg)	CUR group (100mg/kg)
MDA (μ mol/L)	13 \pm 1	26 \pm 0.5***	12 \pm 0.5###	18 \pm 0.4**	20 \pm 0.6**
GSH (mg/gm tissue)	19 \pm 1	6 \pm 0.5***	18 \pm 0.5###	14 \pm 0.7**	8 \pm 0.7**
GPx (μ mol NADPH/mg protein)	59 \pm 3	18 \pm 1***	50 \pm 2***	45 \pm 2***	28 \pm 1**
GR (U/gm tissue)	18 \pm 1	7 \pm 0.6***	17 \pm 0.8###	13 \pm 0.8**	10 \pm 0.5**
SOD (eu/mg protein)	2.5 \pm 0.1	0.9 \pm 0.01***	2.33 \pm 0.03###	1.7 \pm 0.02**	1.2 \pm 0.08**
CAT (μ mol H ₂ O ₂ decomposed /gm tissue)	148 \pm 10	115 \pm 4***	145 \pm 5###	130 \pm 8**	125 \pm 8**

*Data is represented as Mean \pm S.D. * $p < 0.05$, ** $p < 0.01$, *** $p < 0.001$ (statistical significant compared to the control group); # $p < 0.05$, ## $p < 0.01$, ### $p < 0.001$ (statistical differ from DEN group)

Biochemical analysis

The index of liver function in control non-treated group was normal. DEN-bearing non-treated rats had an increased ALT, AST, ALP, GGT, AFP, IL2 and IL6 in comparing to the other groups. CUR treated rats displayed a significant decrease in these parameters when compared to DEN-bearing non-treated rats in a dose dependant Table 2).

Antioxidant enzymes activities and MDA levels.

The hepatic tissue of DEN-bearing non-treated rats had an increased MDA levels and decreased GPx, GR, SOD and CAT activities in comparing to the other groups. CUR treated rats displayed a significant decrease in MDA and increase of GPx, GR, SOD, CAT, GSH when compared to DEN-bearing non-treated rats in a dose dependant (Table 3).

Molecular analysis

The hepatic tissue of DEN-bearing non-treated rats had an increased AFT, IL2 and IL6 and decreased GPx, GR, SOD and CAT mRNA levels in comparing to the other groups. CUR treated rats displayed a significant decrease in AFT, IL2 and IL6 and increase GPx, GR, SOD and CAT mRNA levels when compared to DEN-bearing non-treated rats in a dose dependant (Figure 2).

Discussion

In the present study we aimed to investigate the protective effects of CUR against the DENA induced HCC in rats. The histopathological examination of hepatic tissue, displayed the HCC lesions in rats administrated DENA. The same observation was documented by many authors (Bendong et al., 2012; Zhao et al., 2014). The histopathological features suggested that CUR is effective in reducing DEN-induced hepatocarcinogenesis in a dose dependant manner (Chuang et al., 2000; Sreepriya and Bali, 2006; Zhao et al., 2014).

It is known that the AST, ALT, ALP, GGT serum levels are indicative for hepatic function, their increase is correlated with the hepatic injury (Zhao et al., 2014). DEN hepatic injury is related to the disturbance in hepatocytes membrane instability and metabolism resulting in alterations of the serum levels of these enzymes. The increase of ALT and AST serum levels are specific to hepatocellular disturbance (Al-Rejaie et al., 2009). ALP is a liver function enzymes that related to the membrane lipid in canalicular ducts. ALP increase in serum reflects the biliary flow disturbance. So, the extra or intra-hepatic interference with the bile flow leads to elevation of ALP serum levels (Zhao et al., 2014). GGT is a membrane-bound enzyme, present mainly in the canalicular ducts. GGT serum levels are ultared by many pathologic and physiological factors, such as carcinogenesis and development (Yao et al., 2004). In our results the increase of serum GGT level in DENA group may be attributed to its liberation from the cellular membrane into blood indicating the cellular membrane damage as a result of carcinogenesis (Zhao et al., 2014). The decrease of ALT, AST, ALP and GGT serum levels in CUR treated rats may be attributed to the decrease of cellular damage (Sreepriya

and Bali, 2006; Zhao et al., 2014).

It is well documented that, DENA induces hepatic dysfunction through the induction of disturbances in antioxidant defense systems, increases the reactive oxygen species (ROS) and membrane lipid peroxidation and consequently vital bio-membranes damage (Mohamed et al., 2010; Ismail et al., 2011). The anti-oxidative defense system includes enzymatic and non-enzymatic components as GPx and SOD which consider the key enzymes in elimination of free radicals. SOD act upon the toxic superoxide anions (O₂⁻) converting it to O₂ and H₂O₂, which reduced by GSH-Px in presence of GSH to H₂O and produced the oxidize glutathione (GSSG) (Subudhi and Chainy, 2010), that converted back to GSH by GR. While CAT directly breakdown of H₂O₂ to O₂ and H₂O (Kaushik and Kaur, 2003). In the present study, DENA treated rats had a significant decrease in the activity and gene expression of GPx, GR, SOD and CAT and the level of GSH and a significant increase in the level of MDA (Bendong et al., 2012). In the same line of the present study results, several studies exhibits that, the anti-carcinogenic effect of CUR is produced through its protective effect against oxidative damage and its antioxidant property exerting as a powerful scavenger for oxygen free radicals and its ability to increase intracellular glutathione concentration, in addition by protecting the level of lipid peroxidation (Ciftci et al., 2012; Bendong et al., 2012).

Alpha fetoprotein is a fetal specific glycoprotein secreted from fetal liver and yolk sac, rapidly falls few weeks after birth (Mallikarjun et al., 2013). AFP is the most important serum marker for diagnosis of HCC (Wen et al., 2013). In the same line of our results Soresi et al (2003), reported that, AFP serum level had been elevated in DENA treated rats. CUR treatment has an ameliorative effect on AFP (Oscar et al 2007; Ahmed et al., 2014).

IL-6 is an immunoregulatory cytokines that produced by cancer cells and associated macrophages, its high serum level is associated with specific immune and metabolic alterations that lead to cancer cachexia, one of the main causes of death in cancer patients. IL-6 involved in cancer cells growth through induction of matrix metalloproteinase (MMP)-9 productions (Lane et al., 2011), also induction of tumor angiogenesis (Rabinovich et al., 2011), IL-2 and IL-6 represents the main factors of the cell-mediated immune response. The production of IL-2 and its receptor on cytotoxic T lymphocytes is induced by IL-6. IL-2 is the key cytokine in the regulation of the antineoplastic immunity (Lo et al., 2011). IL-6 was increased in the serum patient with cancer and may be considered an indicator of the inflammatory and oxidative status of these patients (Mantovani et al., 2003). Our data indicated the significant increase of the serum levels and hepatic gene expression of IL-2 and IL-6 in experimental HCC-induced rats than in other experimental groups. Some authors in the same line demonstrated that the IL-6 concentrations were higher in cancer patient than healthy controls (Katriina et al., 2008). The administration of CUR suppress the IL-2 and IL-6 gene expression as well decrease there levels in serum, this explain the antiinflammatory activity of curcumin. This effect can be produced by the ability

of CUR to modulate a variety of molecules that have an important role in cancer progression such as cytokines (Fujioka et al., 2003). CUR has been found to interrupt the cell cycle, acting as anti-proliferative, cytotoxic and apoptotic for HCC cell line (Vietri et al., 2003). CUR also inhibits IL-6 production (Chen et al., 2003) which explains the reduction of IL-2 and 6 in CUR treated groups. CUR has been shown as potent immunomodulatory agent that down regulates the expression of various proinflammatory cytokines including TNF, IL-1, IL-2, IL-6, IL-8, IL-12 (Ganesh et al., 2007).

In conclusion, based on the present study results, we suggest the protective effects of CUR against DEN-induced hepatocarcinogenesis in albino rats. CUR had been modulated the hepatic pathological alteration, liver function enzymes serum levels, induced the hepatic antioxidant system and suppressed the proinflammatory cytokines.

Acknowledgements

This work was funded by the Deanship of Scientific Research (DSR), King Abdulaziz University, Jeddah, under grant number (965-011-D1434). The authors, therefore, acknowledge with thanks DSR technical and financial support.

References

Ahmed O, Mohamed B, Mahmoud A (2014). Curcumin and naringin prevent 7,12-dimethylbenz(a)anthracene-induced hepatic injury by suppressing inflammation and oxidative stress. *J Internat Academic Res Multidisciplinary*, **2**, 589-606.

Ali A, Afifi M, Abdelazim A, Mosleh Y (2014). Quercetin and omega 3 ameliorate oxidative stress induced by aluminium chloride in the Brain. *J Mol Neurosci*, **53**, 654-660

Al-Rejaie SS, Aleisa AM, Al-Yahya AA, et al (2009). Progression of diethylnitrosamine-induced hepatic carcinogenesis in carnitine-depleted rats. *World J Gastroenterol*, **15**, 1373-80

Bancroft J, Gamble M (2008). (Theory and Practice of Histological Technique) 4th Ed., Churchill, Livingston, New York, London, San Francisco, Tokyo.

Bendong C, Mingliang N, Guangshun Y (2012). Effect of paeonol on antioxidant and immune regulatory activity in HCC Rats. *Molecules*, **17**, 4672-83.

Chen Y, Chen C, Chen J, Tsauer W, Hsu S (2003). Non-canthalidin-induced apoptosis is via the extracellular signal-regulated kinase and c-Jun-NH2-terminal kinase signaling pathway in human hepatoma Hep G2 cells. *Br J Pharmacol*, **140**, 461-70.

Chuang S, Kuo M, Hsu C, et al (2000). Curcumin-containing diet inhibits diethyl-nitrosamine-induced murine hepatocarcinogenesis. *Carcinogenesis*, **21**, 331-5.

Ciftci O, Aydin M, Ozdemir I, Vardi N (2012). Quercetin prevents 2, 3, 7, 8-tetrachlorodibenzo-p-dioxin-induced testicular damage in Rats. *Andrologia*, **44**, 164-173.

Corson T, Crews C (2007). Molecular understanding and modern application of traditional medicines. Triumphs and trials. *Cell*, **130**, 769-74.

Fujioka S, Sclabas G, Schmidt C, et al (2003). Function of nuclear factor kappa B in pancreatic cancer metastasis. *Clin Cancer Res*, **9**, 346-354.

Ganesh C, Bharat B (2007). Spicing Up of the Immune System

by Curcumin. *J Clin Immunol*, **27**, 19-43.

Gopal P, Paul M, Pau S (2014). Curcumin induces caspase mediated apoptosis in JURKAT cells by disrupting the redox balance. *Asian Pac J Cancer Prev*, **15**, 93-100.

Ismail M, Iqbal Z, Khattak M, Javaid A, Khan T (2011). Prevalence, types and predictors of potential drug-drug interactions in pulmonology ward of a tertiary care hospital. *Afr J Pharm Pharmacol*, **5**, 1303-9.

Katriina H, Shah E, Debbie A (2008). Systematic review of the association between circulating interleukin-6 (IL-6) and cancer. *European J Cancer*, **44**, 937-45.

Kaushik S, Kaur J (2003). Chronic cold exposure affects the antioxidant defense system in various rat tissues. *Clin Chim Acta*, **333**, 69-77.

Lane D, Matte I, Rancourt C (2011). Prognostic significance of IL-6 and IL-8 ascites levels in ovarian cancer patients. *BMC Cancer*, **11**, 210.

Liovet J, Di Bisceglie A, Bruix J, et al (2008). Design and endpoints of clinical trials in hepatocellular carcinoma. *J Natl Cancer Inst*, **100**, 698-711.

Lo C, Chen M, Hsiao M (2011). IL-6 trans-signaling information and progression of malignant ascites in ovarian cancer. *Cancer Res*, **71**, 424-34.

Mallikarjun P, Keyur A, Sheth C, Adarsh A (2013). Elevated Alpha Fetoprotein, No Hepatocellular Carcinoma. *JCEH*, **3**, 162-4.

Mantovani G, Maccio A, Madeddu C (2003). Antioxidant agents are effective in inducing lymphocyte progression through cell cycle in advanced cancer patients: assessment of the most important laboratory indexes of cachexia and oxidative stress. *J Mol Med*, **81**, 664-73.

Mohamed A, Metwally N, Mohamed S, Hassan E (2010). Protective capacity of butanolic extract of myoporium laetum against oxidative stress and immune disorder induced tissue damage in profenofos intoxicated rats. *Int J Acad Res*, **2**, 157-164.

Olivier F, Peter J, Margaret J (1995). Spontaneous acceptance of rat liver allografts is associated with an early down regulation of intra graft interleukin-4 messenger RNA expression. *Hepatol*, **21**, 767-75.

Oscar A, Bernardo C, Daniela M, et al (2007). The progressive elevation of alpha fetoprotein for the diagnosis of hepatocellular carcinoma in patients with liver cirrhosis. *BMC Cancer*, **7**, 28.

Parker J, Roe S, Barford D (2004). Crystal structure of a PIWI protein suggests mechanisms for siRNA recognition and slicer activity. *EMBO J*, **23**, 4727-37.

Preetha A, Ajaikumar B, Robert A, Bharat B (2007). Bioavailability of curcumin: problems and promises. *Mol Pharm*, **4**, 807-18.

Preetha A, Chitra S, Sonia J, et al (2008). Curcumin and cancer: an "old-age" disease with an "age-old" solution," *Cancer Let*, **267**, 133-164.

Rabinovich A, Medina L and Piura B (2011). Regulation of ovarian carcinoma SKOV-3 cell proliferation and secretion of MMPs by autocrine IL-6. *Anticancer Res*, **27**, 267-72.

Soresi M, Magliarisi C, Campagna P, et al (2003). Usefulness of alpha-fetoprotein in the diagnosis of hepatocellular carcinoma. *Anticancer Res*, **23**, 1747-53.

Sreepriya M, Bali G (2006). Effects of administration of embelin and curcumin on lipid peroxidation, hepatic glutathione antioxidant defense and hematopoietic system during N-nitrosodiethylamine/ phenobarbital-induced hepatocarcinogenesis in Wistar rats. *Mol Cell Biochem*, **284**, 49-55.

Subudhi U, Chainy G (2010). Expression of hepatic antioxidant genes in L-thyroxine-induced hyperthyroid rats: Regulation by vitamin E and Curcumin. *Chem Biol Interact*, **183**,

- Vietri M, Pietrabissa A, Mosca F, et al (2003). Curcumin is a potent inhibitor of phenol sulfo-transferase (SULT1A1) in human liver and extra-hepatic tissue. *Xenobiotica*, **33**, 357-63.
- Wen-jun M, Hai-yong W, Li-song T (2013). Correlation analysis of preoperative serum alpha-fetoprotein (AFP) level and prognosis of hepatocellular carcinoma (HCC) after hepatectomy. *World J Surg Oncol*, **11**, 212-9.
- Yao DF, Dong ZZ, Yao DB, et al (2004). Abnormal expression of hepatoma-derived gamma-glutamyltransferase subtyping and its early alteration for carcinogenesis of hepatocytes. *Hepatobiliary Pancreat Dis Int*, **3**, 564-70.
- Youns M, Abdel Wahab A, Hassan Z, Attia M (2013). Serum talin-1 is a potential novel biomarker for diagnosis of hepatocellular carcinoma in Egyptian patients. *Asian Pac J Cancer Prev*, **14**, 3819-23
- Zekri Ael-R, Nassar AA, El-Din El-Rouby MN, et al (2013). Disease progression from chronic hepatitis C to cirrhosis and hepatocellular carcinoma is associated with increasing DNA promoter methylation. *Asian Pac J Cancer Prev*, **14**, 6721-6.
- Zhang J, Wang R, Ma YY, et al (2013). Association between single nucleotide polymorphisms in miRNA196a-2 and miRNA146a and susceptibility to hepatocellular carcinoma in a Chinese population. *Asian Pac J Cancer Prev*, **14**, 6427-31.
- Zhao J, Peng L, Geng C, et al (2014). Preventive effect of hydrazinocurcumin on carcinogenesis of diethylnitrosamine-induced hepatocarcinoma in male SD Rats. *Asian Pac J Cancer Prev*, **15**, 2115-21
- Zhaohui L, Tianxia L, Dejun Y, et al (2013). Curcumin protects against rotenone-induced neurotoxicity in cell and drosophila models of Parkinson's disease. *Adv Parkinson's Dis*, **2**, 18-27.
- Zhong C, Li H, Liu D, et al (2014). Clinical study of hepatectomy combined with jianpi huayu therapy for hepatocellular carcinoma. *Asian Pac J Cancer Prev*, **15**, 5951-7
- Zhu WJ, Huang CY, Li C, et al (2013). Risk factors for early recurrence of HBV-related hepatocellular carcinoma meeting Milan criteria after curative resection. *Asian Pac J Cancer Prev*, **14**, 7101-6.