

Intestinal Nematodes from Small Mammals Captured near the Demilitarized Zone, Gyeonggi Province, Republic of Korea

Deok-Gyu Kim^{1,2}, Jae-Hwan Park^{1,†}, Jae-Lip Kim¹, Bong-Kwang Jung¹, Sarah Jiyoun Jeon¹, Hyemi Lim¹,
Mi Youn Lee¹, Eun-Hee Shin^{1,3}, Terry A. Klein⁴, Heung-Chul Kim⁵, Sung-Tae Chong⁵, Jin-Won Song⁶,
Luck-Ju Baek⁶, Jong-Yil Chai^{1,*}

¹Department of Parasitology and Tropical Medicine, Seoul National University College of Medicine, Seoul 110-799, Korea; ²Department of Parasitology, College of Medicine, Dankook University, Chonan 330-714, Korea; ³Seoul National University Bundang Hospital, Seongnam 463-707, Korea; ⁴Public Health Command Region-Pacific Unit 45006, APO AP 96343, USA, ⁵5th Medical Detachment, 168th Multifunctional Medical Battalion, 65th Medical Brigade, Unit 15247, APO AP 96205-5247, USA; ⁶Department of Microbiology, College of Medicine, Korea University, Seoul 136-705, Korea

Abstract: A total of 1,708 small mammals (1,617 rodents and 91 soricomorphs), including *Apodemus agrarius* (n = 1,400), *Microtus fortis* (167), *Crocidura lasiura* (91), *Mus musculus* (32), *Myodes* (= *Eothenomys*) *regulus* (9), *Micromys minutus* (6), and *Tscherskia* (= *Cricetulus*) *triton* (3), were live-trapped at US/Republic of Korea (ROK) military training sites near the demilitarized zone (DMZ) of Paju, Pocheon, and Yeoncheon, Gyeonggi Province from December 2004 to December 2009. Small mammals were examined for their intestinal nematodes by necropsy. A total of 1,617 rodents (100%) and 91 (100%) soricomorphs were infected with at least 1 nematode species, including *Nippostrongylus brasiliensis*, *Heligmosomoides polygyrus*, *Syphacia obvelata*, *Heterakis spumosa*, *Protospirura muris*, *Capillaria* spp., *Trichuris muris*, *Rictularia affinis*, and an unidentified species. *N. brasiliensis* was the most common species infecting small mammals (1,060; 62.1%) followed by *H. polygyrus* (617; 36.1%), *S. obvelata* (370; 21.7%), *H. spumosa* (314; 18.4%), *P. muris* (123; 7.2%), and *Capillaria* spp. (59; 3.5%). Low infection rates (0.1-0.8%) were observed for *T. muris*, *R. affinis*, and an unidentified species. The number of recovered worms was highest for *N. brasiliensis* (21,623 worms; mean 20.4 worms/infected specimen) followed by *S. obvelata* (9,235; 25.0 worms), *H. polygyrus* (4,122; 6.7 worms), and *H. spumosa* (1,160; 3.7 worms). *A. agrarius* demonstrated the highest prevalence for *N. brasiliensis* (70.9%), followed by *M. minutus* (50.0%), *T. triton* (33.3%), *M. fortis* (28.1%), *M. musculus* (15.6%), *C. lasiura* (13.2%), and *M. regulus* (0%). This is the first report of nematode infections in small mammals captured near the DMZ in ROK.

Key words: *Nippostrongylus brasiliensis*, *Heligmosomoides polygyrus*, *Syphacia obvelata*, *Heterakis spumosa*, *Protospirura muris*, *Capillaria* spp., *Trichuris muris*, *Rictularia affinis*, nematode, rodent, insectivore, demilitarized zone, Gyeonggi-do (Province)

The demilitarized zone (DMZ) is a 4-km wide boundary on the Korean Peninsula that serves as a buffer zone between South Korea (Republic of Korea; ROK) and North Korea [1]. The DMZ consists of unmanaged lands, except for 1 village (Daeseong-dong), and is an ecologically unique and highly conserved region [2]. As a result, there have been few reports of intestinal parasites present in wild animals near the DMZ.

In addition, US/ROK-operated military training sites consist of small to large expanses of unmanaged lands similar to parts of the DMZ where wild small to large animals are often abundant.

A rodent-borne disease surveillance program, including intestinal parasite surveys, was conducted at US/ROK-operated training sites near the DMZ, Gyeonggi Province, ROK, where trematode infections were previously reported [3-5]. In previous studies, the striped field mouse, *Apodemus agrarius*, and the Ussuri white-toothed shrew, *Crocidura lasiura*, were identified as natural definitive hosts for *Plagiorchis muris* [3], in addition to several species of echinostome flukes [4]. Moreover, *A. agrarius* was identified as a natural definitive host for a human-infecting trematode, *Neodiplostomum seoulense* [5]. The present

•Received 20 October 2014, revised 24 December 2014, accepted 24 December 2014.

*Corresponding author (cyj@snu.ac.kr)

†Deceased after completion of this study.

© 2015, Korean Society for Parasitology and Tropical Medicine

This is an Open Access article distributed under the terms of the Creative Commons Attribution Non-Commercial License (<http://creativecommons.org/licenses/by-nc/3.0>) which permits unrestricted non-commercial use, distribution, and reproduction in any medium, provided the original work is properly cited.

Table 1. Nematode infections in small rodents and soricomorphs captured near the DMZ of Gyeonggi Province, Korea

		No. rodents examined	Nematodes								
			<i>Nippostrongylus brasiliensis</i>	<i>Heligmosomoides polygyrus</i>	<i>Syphacia obvelata</i>	<i>Heterakis spumosa</i>	<i>Protospirura muris</i>	<i>Capillaria</i> sp.	<i>Rictularia affinis</i>	<i>Trichuris muris</i>	Others
<i>Apodemus agrarius</i>	No. mice infected (%)	1,400	992 (70.9)	592 (42.3)	351 (25.1)	310 (22.1)	120 (8.6)	10 (0.7)	13 (0.9)	1 (0.1)	17 (1.2)
	No. worms (av. no.) ^a		20,830 (21.0)	3,954 (6.7)	9,013 (25.7)	1,146 (0.5)	469 (3.9)	14 (1.4)	23 (1.8)	1 (1.0)	23 (1.4)
<i>Microtus fortis</i>	No. mice infected (%)	167	47 (28.1)	4 (2.4)	1 (0.6)	0 (0.0)	0 (0.0)	5 (3.0)	0 (0.0)	0 (0.0)	29 (17.4)
	No. worms (av. no.) ^a		698 (14.9)	21 (5.3)	1 (1.0)	0 (0.0)	0 (0.0)	9 (1.8)	0 (0.0)	0 (0.0)	211 (7.3)
<i>Crocodyra lasiura</i>	No. mice infected (%)	91	12 (13.2)	9 (9.9)	5 (5.5)	1 (1.1)	3 (3.3)	44 (48.4)	0 (0.0)	0 (0.0)	13 (14.3)
	No. worms (av. no.) ^a		77 (6.4)	86 (9.6)	11 (2.2)	2 (2.0)	3 (1.0)	308 (7.0)	0 (0.0)	0 (0.0)	21 (1.6)
<i>Mus musculus</i>	No. mice infected (%)	32	5 (15.6)	10 (31.3)	8 (25.0)	2 (6.3)	0 (0.0)	0 (0.0)	0 (0.0)	1 (3.1)	0 (0.0)
	No. worms (av. no.) ^a		9 (1.8)	59 (5.9)	131 (16.4)	3 (1.5)	0 (0.0)	0 (0.0)	0 (0.0)	3 (3.0)	0 (0.0)
<i>Myodes regulus</i>	No. mice infected (%)	9	0 (0.0w)	1 (11.1)	2 (22.2)	0 (0.0)	0 (0.0)	0 (0.0)	0 (0.0)	0 (0.0)	0 (0.0)
	No. worms (av. no.) ^a		0 (0.0)	1 (1.0)	32 (16.0)	0 (0.0)	0 (0.0)	0 (0.0)	0 (0.0)	0 (0.0)	0 (0.0)
<i>Micromys minutus</i>	No. mice infected (%)	6	3 (50.0)	0 (0.0)	3 (50.0)	1 (16.7)	0 (0.0)	0 (0.0)	0 (0.0)	0 (0.0)	0 (0.0)
	No. worms (av. no.) ^a		8 (2.7)	0 (0.0)	47 (15.7)	9 (9.0)	0 (0.0)	0 (0.0)	0 (0.0)	0 (0.0)	0 (0.0)
<i>Tscherskia triton</i>	No. mice infected (%)	3	1 (33.3)	1 (33.3)	0 (0.0)	0 (0.0)	0 (0.0)	0 (0.0)	0 (0.0)	0 (0.0)	0 (0.0)
	No. worms (av. no.) ^a		1 (1.0)	1 (1.0)	0 (0.0)	0 (0.0)	0 (0.0)	0 (0.0)	0 (0.0)	0 (0.0)	0 (0.0)
Total	No. mice infected (%)	1,708	1,060 (62.1)	617 (36.1)	370 (21.7)	314 (18.4)	123 (7.2)	59 (3.5)	13 (0.8)	2 (0.1)	59 (3.5)
	No. worms (av. no.) ^a		21,623 (20.4)	4,122 (6.7)	9,235 (25.0)	1,160 (3.7)	472 (3.8)	331 (5.6)	23 (1.8)	4 (2.0)	255 (4.3)

^aMean no. per infected animal.

report focuses on intestinal nematode infections among 6 species of rodents (*A. agrarius*, *Tscherskia triton*, *Myodes regulus*, *Microtus fortis*, *Micromys minutus*, and *Mus musculus*) and 1 species of soricomorphs (*C. lasiura*) live-captured near the DMZ from December 2004 to March in 2009.

A total of 1,617 rodents (6 species) and 91 soricomorphs (1 species) were live-captured, using the collapsible Sherman® traps (3"×3.5"×9" folding traps, H.B. Sherman, Tallahassee, Florida, USA), from 3 US/ROK military training sites in Gyeonggi Province (Paju-si, Pocheon-si, and Yeoncheon-gun) located within 3-10 km from the DMZ. The captured mammals included *A. agrarius* (n=1,400), *M. fortis* (167), *C. lasiura* (91), *M. musculus* (32), *M. regulus* (9), *M. minutus* (6), and *T. triton* (3). Trapping was conducted quarterly from December 2004 to September 2005 and from March to December 2009. Captured specimens were euthanized in accordance with a Korea University Institutional Animal Care and User Committee (IACUC) protocol under biosafety level 2 (BSL-2) laboratory conditions. The stomach, small intestine, and large intestine to the end of the rectum, were removed and placed in 50-ml glass screw-top vials in 70% alcohol until examination. The gastrointestinal content was removed and examined for intestinal helminths under a stereomicroscope [3-5]. Nematodes were isolated and fixed with 70% alcohol. Selected specimens were cleared in lactophenol and placed on a microscope slide with coverslip and identified using a research microscope [6].

Of a total of 1,617 rodents and 91 soricomorphs examined, 1,048 (64.8%) and 12 (13.2%), respectively, were infected with *Nippostrongylus brasiliensis* (Table 1, Fig.1). In addition, ro-

dent and soricomorphs were infected with *Heligmosomoides polygyrus* (608, 37.6% and 9, 9.9%, respectively), *Syphacia obvelata* (365, 22.6% and 5, 5.5%, respectively), *Heterakis spumosa* (313, 19.4% and 1, 1.1%, respectively), *Protospirura muris* (120, 7.4% and 3, 3.3%, respectively), *Capillaria* spp. (15, 0.9% and 44, 48.4%, respectively) (Fig. 1). and an unidentified nematode species (46, 2.8% and 13, 14.3%, respectively). Only rodents were found infected with *Rictularia affinis* (13, 0.8%) and *Trichuris muris* (2, 0.1%) (Fig. 1).

A. agrarius demonstrated high nematode infection rates with 992 (70.9%) harboring *N. brasiliensis* nematodes, followed by *H. polygyrus* (592, 42.3%), *S. obvelata* (351, 25.1%), *H. spumosa* (310, 22.1%), and *Protospirura muris* (120, 8.6%) (Table 1). *M. fortis* was infected with *N. brasiliensis* (47, 28.1%); however, infection rates for other nematodes were relatively low (0-2.4%). *C. lasiura* demonstrated the highest infection rate for *Capillaria* spp. (44, 48.4%), followed by *N. brasiliensis* (12, 13.2%) and *H. polygyrus* (9, 9.9%). *M. musculus* demonstrated the highest infection rate for *H. polygyrus* (10, 31.3%), followed by *S. obvelata* (8, 25.0%), and *N. brasiliensis* (5, 15.6%).

N. brasiliensis was observed more frequently in *A. agrarius* (70.9%), followed by *M. minutus* (50.0%), *T. triton* (33.3%), *M. fortis* (28.1%), *M. musculus* (15.6%), and *C. lasiura* (13.2%). *H. polygyrus* was found more frequently in *A. agrarius* (42.3%), followed by *T. triton* (33.3%), and *M. musculus* (31.3%). The highest prevalence of *S. obvelata* was observed in *M. minutus* (50.0%), followed by *A. agrarius* (25.1%), *M. musculus* (25.0%), and *M. regulus* (22.2%). The highest prevalence of *H. spumosa* was observed in *A. agrarius* mice (22.1%). *Capillaria*

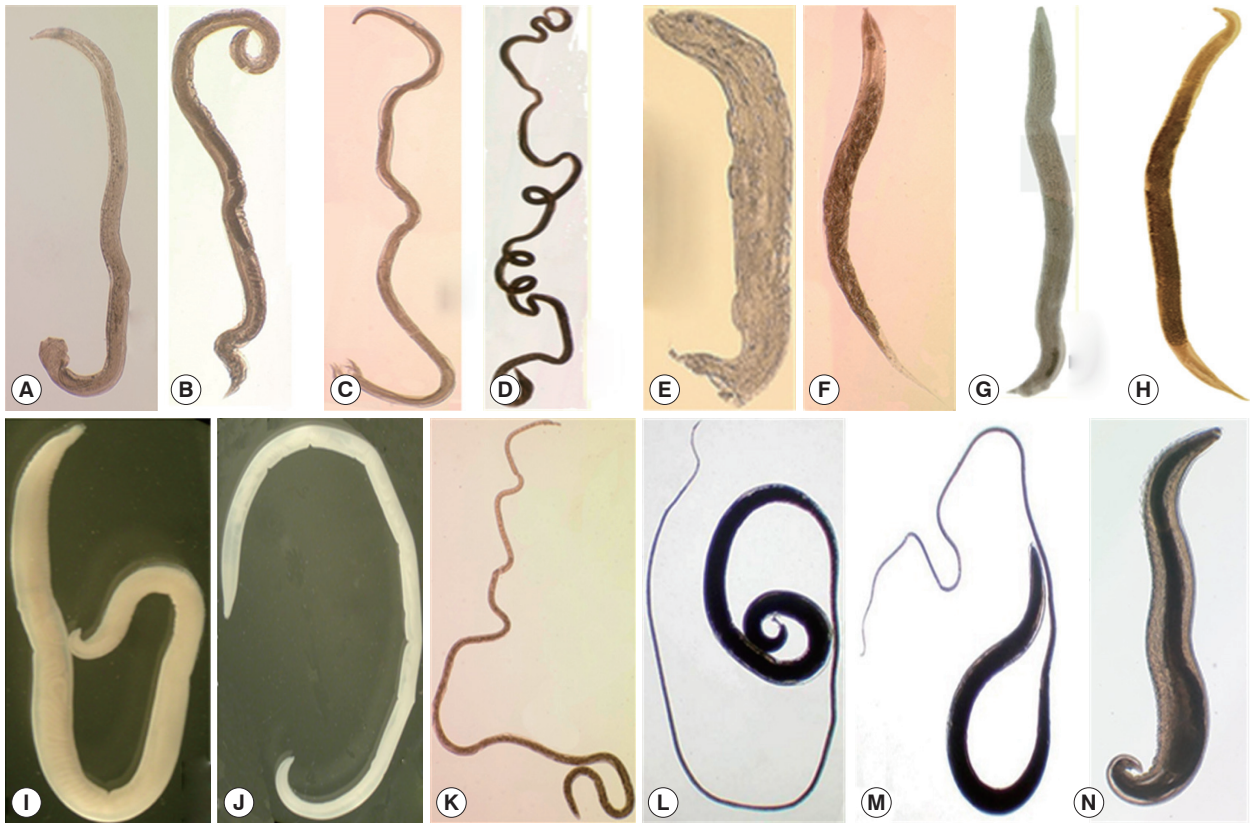


Fig. 1. Nematodes collected from wild rodents in Korea. The most popular species was *Nippostrongylus brasiliensis* (A, male; B, female) followed by *Heligmosomoides polygyrus* (C, male; D, female), *Syphacia obvelata* (E, male; F, female), *Heterakis spumosa* (G, male; H, female), *Protospirura muris* (I, male; J, female), *Capillaria* sp. (K, female), *Trichuris muris* (L, male; M, female), and *Rictularia affinis* (N, male).

spp. were observed more frequently in *C. lasiura* (48.4%). The highest worm burdens were observed for *N. brasiliensis* (total 21,623 worms; mean 20.4 worms/infected rodent), followed by *S. obvelata* (9,235; mean 25.0), *H. polygyrus* (4,122; mean 6.7), *Protospirura muris* (472; mean 3.8), and *H. spumosa* (1,160; mean 3.7) (Table 1).

In the previous study, Chai et al. [4] reported the infection status of echinostomes from *A. agrarius* captured near the DMZ, ROK. They [3,5] also reported *Plagiorchis muris* and *N. seoulense* infections in *A. agrarius*. However, studies of intestinal nematode infections in rodents and soricomorphs have been limited. Thus, nematode studies are needed to better understand parasite faunas in natural hosts for conserved areas, like the DMZ, and their impact on veterinary and medical health.

The results of the present study have shown that *N. brasiliensis* was the most highly prevalent nematode species with the highest infection intensity among those detected in the study. *N. brasiliensis* is a common and well-known intestinal nematode among rodents [7-9]. Its prevalence in 5 district localities

was 66.7%, 80.3%, 16.2%, 71.6%, and 14.2%, respectively, for Carey Island (Klang, Malaysia), Kuala Lumpur (Malaysia), Belgrade area (Serbia), Baltimore (Maryland, USA), and Caribbean Island (Jamaica) [8-12]. In our study, the prevalence of *N. brasiliensis* ranged from 0% (*M. regulus*) to 70.9% (*A. agrarius*) (overall mean, 62.1%), depending on the species of rodent or soricomorph. This figure is quite different from previous studies performed in Korea [13-15]. Seo et al. [13] and Yong et al. [14] detected high prevalences of *Nippostrongylus muris* but not *N. brasiliensis* among rodents from northern and northern/western parts of Korea, respectively. On the other hand, Sohn et al. [15] detected neither *N. muris* nor *N. brasiliensis* in *A. agrarius* mice from a southern area of Korea. The reason for this discrepancy remains to be investigated.

H. polygyrus demonstrated a high prevalence among rodents captured from various localities of the world, including Portugal, UK, and ROK (this study) and is known to enhance their susceptibility to other intestinal helminth infections [16]. The prevalence of *H. polygyrus* in our study (42.3%) was lower than

that in Portugal [16]. *Heligmosomum* sp., *Heligmosomoides* sp., and heligmosomid nematodes were reported from rodents in ROK [13,15]. Their prevalence was extremely high in rodents of southern parts of ROK (Hapcheon-gun and Gurye-gun), over 97% [15]; however, it was comparatively lower in rodents of northern parts (Gyeonggi and Gangwon Province), 28-30% [13].

The mean prevalence of *S. obvelata*, a murine pinworm species, was 25.1% among 7 species of small mammals examined in this study. It was lower than the one in a previous study in ROK, 36.4% and 41.4%, in *R. norvegicus* and *A. agrarius*, respectively [13]; however, it was higher than the other reported recently in southern regions in ROK, 5.1% [15]. In Brazil, *Rattus rattus* revealed the prevalence of 22.3%, a similar figure to our study [17].

H. spumosa was originally reported from the cecum of a rat from Berlin, Germany, by Schneider in 1866 [13]. In a previous study in Korea, the infection rate of *R. norvegicus*, *A. agrarius*, and *R. rattus* (= *R. alexandrinus*) with *H. spumosa* was 24.2%, 6.4%, and 37.5%, respectively [13]. In our study, its prevalence in *A. agrarius* was 22.1%, much higher than the figure in a previous study [13]. The prevalence of *H. spumosa* in Serbia and Norway was 36.7% [10] and 24.1% [11], respectively, similar to our study.

P. muris was reported previously in the stomach of a rat from Korea in 1968 [13]. Its overall prevalence in this study was 7.2% for all 7 small mammals examined, whereas it was 8.5% from bush rats, *Rattus fuscipes*, in Australia [18] and 5% among cotton rats, *Sigmodon hispidus*, in the US [19]. *C. hepatica* is common worldwide and is found in the livers of a wide variety of mammals, including humans [20]. A previous paper from Malaysia reported the prevalence of *C. hepatica* as 13.9% [9]. In our study, we did not examine the liver but examined only the intestinal tract of the mammals. The *Capillaria* spp. detected in our study may be the same species as reported from other small mammals in Korea [13]; however, further studies are required to elucidate the species of *Capillaria*. The rodent whipworm, *T. muris*, is a common parasite of the cecum of house mice and rats [21]. In *R. norvegicus*, the prevalence of *T. muris* was reported to be 6.0% and 14.8% in Belgrade area (Serbia) and Baltimore, Maryland (the US), respectively [10,11]. However, in our study, its prevalence was very low (0.1%).

The present study is significant because *S. obvelata* is potentially zoonotic to cause human infections. Actually 2 *S. obvelata*

adult specimens (females) were collected from the feces of a Bohemian child living in the Philippines [22]. Another reason for the significance of this study is that several species of the nematodes identified in this study are used as invaluable models for human intestinal nematode infections. *N. brasiliensis* is used as a model for human hookworm infections [23], *H. polygyrus* is used as a model for human ascariasis [24], and *T. muris* is used as a model for human *Trichuris trichiura* infection [25].

In conclusion, 7 species of nematodes were identified, in addition to members of the genus *Capillaria* and an unidentified species, from the gut contents and intestinal tract of 7 species of small mammals (6 rodents and 1 soricomorph) captured near the DMZ of Gyeonggi Province, ROK. This is the first report of nematode infections among rodents and soricomorphs captured near the DMZ, ROK.

ACKNOWLEDGMENTS

We thank COL Hee-Choon (Sam) Lee, Chief, Force Health Protection and Preventive Medicine (FHP&PM), 65th Medical Brigade (MED BDE) and Commanders and staff of the 5th Medical Detachment, 168th Multifunctional Medical Battalion, 65th MED BDE, for their support. Funding for portions of this work was provided by the Armed Forces Health Surveillance Center- Global Emerging Infections Surveillance and Response System (AFHSC-GEIS) Operations, Silver Spring, Maryland, USA, and the Public Health Command Region-Pacific, Camp Zama, Japan.

CONFLICT OF INTEREST

We have no conflict of interest related to this study.

REFERENCES

1. Yoon BI, Kim HC, Kim JT. Lung worm (*Metastrongylus elongatus*) infection in wild boars (*Sus scrofa*) of the demilitarized zone, Korea. *J Wildl Dis* 2010; 46: 1052-1054.
2. Kim KC. Preserving biodiversity in Korea's demilitarized zone. *Science* 1997; 278: 242-243.
3. Chai JY, Park JH, Guk SM, Kim JL, Kim HJ, Kim WH, Shin EH, Klein TA, Kim HC, Chong ST, Song JW, Baek LJ. *Plagiatorchis muris* infection in *Apodemus agrarius* from northern Gyeonggi-do (province) near the demilitarized zone. *Korean J Parasitol* 2007; 45: 153-156.

4. Chai JY, Park JH, Jung BK, Guk SM, Kim JL, Shin EH, Klein TA, Kim HC, Chong ST, Baek LJ, Song JW. Echinostome infections in the striped-field mouse, *Apodemus agrarius*, and the Ussuri white-toothed shrew, *Crocodyra lasiura*, caught near the demilitarized zone, Gyeonggi-do (Province), Republic of Korea. *Korean J Parasitol* 2009; 47: 311-314.
5. Chai JY, Park JH, Guk SM, Kim JL, Kim HJ, Kim WH, Shin EH, Klein TA, Kim HC, Chong ST, Song JW, Baek LJ. *Apodemus agrarius* as a new definitive host for *Neodiplostomum seoulense*. *Korean J Parasitol* 2007; 45: 157-161.
6. Beaver PC, Jung RC, Cupp EW. *Clinical Parasitology*. 9th ed. Philadelphia, USA. Lea & Febiger. 1984, p. 733-758.
7. Haley AJ. Biology of the rat nematode *Nippostrongylus brasiliensis* (Travassos, 1914). I. Systematics, hosts and geographic distribution. *J Parasitol* 1961; 47: 727-732.
8. Nursyazana MT, Mohdzain SN, Jeffery J. Biodiversity and macro-parasitic distribution of the wild rat population of Carey Island, Klang. *Trop Biomed* 2013; 30: 199-210.
9. Siti Shafiyah CO, Jamaiah I, Rohela M, Lau YL, Siti Aminah F. Prevalence of intestinal and blood parasites among wild rats in Kuala Lumpur, Malaysia. *Trop Biomed* 2012; 29: 544-550.
10. Kataranovski M, Mirkov I, Belij S, Popov A, Petrovic Z, Gaci Z, Kataranovski D. Intestinal helminths infection of rats (*Rattus norvegicus*) in the Belgrade area (Serbia): the effect of sex, age and habitat. *Parasite* 2011; 18: 189-196.
11. Easterbrook JD, Kaplan JB, Glass GE, Watson J, Klein SL. A survey of rodent-borne pathogens carried by wild-caught Norway rats: a potential threat to laboratory rodent colonies. *Lab Anim* 2008; 42: 92-98.
12. Waugh CA, Lindo JE, Foronda P, Angeles-Santana M, Lorenzo-Morales J, Robinson RD. Population distribution and zoonotic potential of gastrointestinal helminths of wild rats *Rattus rattus* and *R. norvegicus* from Jamaica. *J Parasitol* 2006; 92: 1014-1018.
13. Seo BS, Rim HJ, Yoon JJ, Koo BY, Hong NT. Studies on the parasitic helminths of Korea. III. Nematodes and cestodes of rodents. *Korean J Parasitol* 1968; 6: 123-131.
14. Yong TS, Chung KH, Ree HI. Infection status of intestinal parasites of field rodents in Korea. *Yonsei Rep Trop Med* 1991; 22: 55-59.
15. Sohn WM, Na BK, Song HJ, Kim CM, Nam GJ. Intestinal helminthic infections in striped field mice, *Apodemus agrarius*, from two southern regions of Korea. *Korean J Parasitol* 2014; 52: 419-423.
16. Behnke JM, Eira C, Rogan M, Gilbert FS, Torres J, Miquel J, Lewis JW. Helminth species richness in wild wood mice, *Apodemus sylvaticus*, is enhanced by the presence of the intestinal nematode *Heligmosomoides polygyrus*. *Parasitology* 2009; 136: 793-804.
17. de Araujo EO, de Moura Mendes M, Langone PQ, Müller G. The helminth parasites of *Rattus rattus* (Linnaeus, 1758) of urban, intermediate and rural environments in southern Brazil. *Neotrop Helminthol* 2014; 8: 19-22.
18. Obendorf DL. The helminth parasites of *Rattus fuscipes* (Waterhouse) from Victoria, including description of two new nematode species. *Aust J Zool* 1979; 27: 867-879.
19. Boggs JE, McMurry ST, Leslie DM Jr, Engle DM, Lochmiller RL. Influence of habitat modification on the community of gastrointestinal helminths of cotton rats. *J Wildl Dis* 1991; 27: 584-593.
20. Tung KC, Hsiao FC, Wang KS, Yang CH, Lai CH. Study of the endoparasitic fauna of commensal rats and shrews caught in traditional wet markets in Taichung City, Taiwan. *J Microbiol Immunol Infect* 2013; 46: 85-88.
21. Fahmy MAM. An investigation on the life cycle of *Trichuris muris*. *Parasitology* 1954; 44: 50-57.
22. Riley WA. A mouse oxyurid, *Syphacia obvelata*, as a parasite of man. *J Parasitol* 1919; 6: 89-93.
23. Ndlovu H, Darby M, Froelich M, Horsnell W, Lühder F, Hünig T, Brombacher F. Inducible deletion of CD28 prior to secondary *Nippostrongylus brasiliensis* infection impairs worm expulsion and recall of protective memory CD4+ T cell. *PLoS Pathog* 2014; 10: e1003906.
24. Reynolds LA, Harcus Y, Smith KA, Webb LM, Hewitson JP, Ross EA, Brown S, Uematsu S, Akira S, Gray D, Gray M, MacDonald AS. MyD88 signaling inhibits protective immunity to the gastrointestinal helminth parasite *Heligmosomoides polygyrus*. *J Immunol* 2014; 193: 2984-2993.
25. Cliffe LJ, Grensis RK. The *Trichuris muris* system: a paradigm of resistance and susceptibility to intestinal nematode infection. *Adv Parasitol* 2004; 57: 255-307.