Korean J Thorac Cardiovasc Surg 2015;48:46-51 □ Clinical Research □
ISSN: 2233-601X (Print) ISSN: 2093-6516 (Online) http://dx.doi.org/10.5090/kjtcs.2015.48.1.46

Surgical Treatment for Occlusion of Graft Arteriovenous Fistula in Patients Undergoing Hemodialysis

Tae Ook Noh, M.D., Sung-Wook Chang, M.D., Kyoung Min Ryu, M.D., Jae Wook Ryu, M.D.

Background: Maintenance of adequate vascular access for hemodialysis is important in patients with end-stage renal disease. Once arteriovenous fistula (AVF) occlusion occurs, the patient should be treated with rescue therapy. This study was performed to evaluate the results of a rescue therapy for AVF occlusion. ***Methods:*** From January 2008 to December 2012, 47 patients who underwent surgical rescue therapy for AVF occlusion after graft AVF formation, were enrolled in this study. The patients were divided into two groups, namely the graft repair group (group A, n=19) and the thrombectomy group (group B, n=28). Postoperative results of both groups were analyzed retrospectively. ***Results:*** There were no statistically significant differences in the clinical characteristics between the two groups. In terms of the duration of AVF patency after the first rescue therapy, group A showed a longer AVF patency duration than group B (24.5±21.9 months versus 17.7±13.6 months), but there was no statistically significant difference (p=0.310). In terms of the annual frequency of AVF occlusion after the rescue therapy of group A was lower than that of group B (0.59 versus 0.71), but there was no statistically significant difference (p=0.540). The AVF patency rates at 1, 2, 3, and 5 years after the first rescue therapy in group A were 52.6%, 31.5%, 21.0%, and 15.7%, respectively, and those in group B, they were 32.1%, 25.0%, 17.8%, and 7.14%, respectively. There was no statistically significant difference (p=0.402). ***Conclusion:*** Graft repair revealed comparable results. Although there was no statistically significant difference, the patent duration and annual frequency of AVF occlusion of group A were better than those of group B. Therefore, graft repair is considered as a safe and useful procedure for maintaining graft AVF.

Key words: 1. Fistula, arteriovenous
2. Hemodialysis
3. Thrombectomy

INTRODUCTION

A graft arteriovenous fistula (AVF) has a lower patency rate than native AVF because of the stenosis caused by excessive neointimal proliferation at the venous anastomosis site. In a study assessing the frequency of the performance of secondary surgery after graft AVF formation, Sicard et al. [1] reported that secondary surgery had to be performed at least three times in two years to maintain the graft AVF. When thrombotic occlusion occurs, rescue therapy must be performed proactively and appropriately to ensure the long-term use of AVF. In a study in 1,700 patients, Schild et al. [2] reported that a graft AVF had a higher rate of thrombosis than a native, In another study, there were no significant differ-

Department of Thoracic and Cardiovascular Surgery, Dankook University College of Medicine
Received: August 20, 2014, Revised: September 18, 2014, Accepted: October 8, 2014, Published online: February 5, 2015
Corresponding author: Jae-Wook Ryu, Department of Thoracic and Cardiovascular Surgery, Dankook University Hospital, Dankook University College of Medicine, 201 Manghyang-ro, Dongnam-gu, Cheonan 330-715, Korea
(Tel) 82-41-550-6269 (Fax) 82-41-556-0524 (E-mail) j3thorax@chol.com

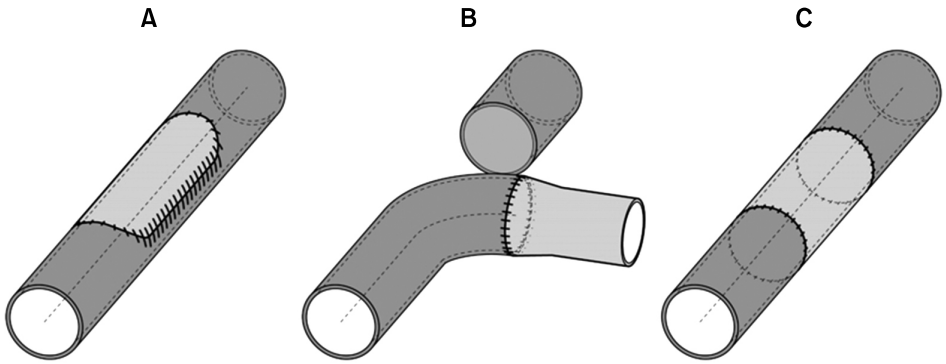

Fig. 1. Various surgical graft repair methods. (A) Patch angioplasty with bovine pericardium or graft; (B) graft extension to new vein, and (C) graft interposition.

ence in the long term patency rates between the graft group and the native group, that was due to the higher rescue rate in the graft group [2]. This result indicates the importance of rescue therapy. Rescue therapy is performed when AVF stenosis is ≥50% and when a hemodynamic, functional, or clinical abnormality is detected. In the past, rescue therapy was generally used for the surgical removal of the thrombus, but recently, it has also been used for interventional endovascular treatment [3].

Further, surgical treatment is commonly performed to remove the thrombosis that blocks the graft. Hemodialysis can be performed immediately after the surgery, as thrombectomy requires a short operation time and uses a graft segment without puncture during the operation. Graft repair is another type of surgical treatment. The severely stenotic AVF can be expanded via graft repair using a new graft or the bovine pericardium. Thus the graft AVF stenosis can be fundamentally resolved so that the wide blood flow through the AVF can be maintained for a long time after the surgery, and there would be less need for creating a new graft AVF. This study was conducted to investigate and compare the efficacy and safety of graft repair with those of conventional thrombectomy by analyzing the postoperative outcomes.

METHODS

This study was conducted in 79 patients who had undergone graft AVF formation at Dankook University Hospital between January 2008 and December 2012. AVF occlusion occurred in 65 of these 79 patients, and they were treated with rescue therapy through 128 surgical treatment procedures. Of the 65 patients who experienced AVF occlusion, 47 underwent follow-up, and the results of their primary surgical rescue therapy were analyzed. The clinical characteristics of these patients were retrospectively reviewed on the basis of the patients' medical records. In addition, an individual interview via telephone was performed when required. The patient's age, gender, and previous disease history, as well as the graft type and location used for the AVF formation, were reviewed, and the time to AVF occlusion, the type of rescue therapy performed, the AVF patency period and re-occlusion of AVF after the rescue therapy were examined. AVF occlusion was diagnosed by physical examination and auscultation of bruit. The patients were grouped according to the surgical treatment method used when AVF occlusion occurred initially, that is, in the graft repair group (group A) and the thrombectomy group (group B), and the postoperative results were compared between the two groups. The surgical treatment methods of graft repair included patch angioplasty with bovine pericardium or graft, graft extension, and graft interposition (Fig. 1).

The primary patency period of the AVF was defined as the time to initial AVF occlusion after AVF formation. The secondary patency period was defined as the time from the first rescue therapy due to the initial AVF occlusion to the surgery due to the second AVF occlusion. Seven patients who did not experience second AVF occlusion were excluded from the analysis for the comparison of patency periods after the rescue therapy.

The annual frequency of AVF occlusion was determined by assessing the number of operations performed due to AVF occlusion during the period from the performance of surgery

Table 1. Clinical characteristics of the patients

Characteristic	Group A (n=19)	Group B (n=28)	p-value
Age (yr)	58.3±15.1	62.5±15.5	0.366
Sex			0.435
Male	6 (31.6)	12 (42.9)	
Female	13 (68.4)	16 (57.1)	
Diabetes mellitus	13 (68.4)	14 (50.0)	0.210
Hypertension	15 (78.9)	23 (82.1)	0.785
Coronary artery disease	2 (10.5)	1 (3.6)	0.338
Operation site			0.754
Left	15 (78.9)	21 (75.0)	
Right	4 (21.1)	7 (25.0)	
Graft type			0.609
Type I	16 (84.2)	25 (89.3)	
Type U	3 (15.8)	3 (10.7)	

Values are presented as mean±standard deviation or number (%).

due to initial AVF occlusion to the end of this study. Statistical analysis was conducted using PASW Statistics for Windows software ver. 18.0 (SPSS Inc., Chicago, IL, USA), and the following methods of analysis were used: First, a cross-analysis was conducted to examine the differences in the general characteristics according to the group. Second, the Student's t-test and one-way analysis of variance were conducted to examine the differences in age, frequency of surgery, patency period, and the need for a new AVF between the two groups. Third, the Kaplan-Meier method was used to examine the AVF patency rates in the two groups according to the follow-up period. Fourth, the significance of the analysis results was tested at $p<0.05$, $p<0.01$, and $p<0.001$.

RESULTS

1) Clinical characteristics of the patients

Forty-seven patients were included in this study. Their mean age was 60.8±15.4 years (range, 20 to 85 years). Eighteen of these patients were males and 29 were females. The preoperative concurrent diseases included diabetes (57.4%), hypertension (80.9%), and coronary artery disease (6.4%). Nineteen of these 47 patients were assigned to group A (patients who had undergone both thrombectomy and graft repair), and 28 were assigned, to group B (patients who had undergone only thrombectomy). No statistically significant difference was found in the preoperative concurrent diseases between the two groups. With respect to the graft type, polytetrafluoroethylene (PTFE) graft was used in all of patients. AVF formation was performed in the left arm of 76.6% of the patients (n=36). With respect to the anastomotic pattern of the grafts, type I was observed in 41 patients (78.7%) and type U was observed, in six patients (21.3%). No statistically significant difference was found in the anastomotic patterns of the grafts between the two groups (Table 1). All patients underwent rescue therapy under local anesthesia and thrombectomy using a Fogarty catheter 4Fr at both the arterial and the venous side through a graft incision. Prolene 6-0 was used to repair the graft incision for thrombectomy. In graft repair, we used the Gore-Tex suture material. Nineteen patients underwent both thrombectomy and graft repair as rescue therapies for AVF occlusion. With respect to the graft repair method, patch angioplasty with bovine pericardium was performed in nine patients; patch angioplasty with a PTFE graft, in six patients; and graft extension, in four patients. Injury to the graft puncture site was observed in all of the patients, and the severely stenotic segment of graft was selected for surgical approach. Twenty-eight patients underwent only thrombectomy, and most of the surgeries were performed on the graft near the anastomotic site.

2) Patency rate of graft arteriovenous fistula and annual frequency of arteriovenous fistula occlusion

The primary AVF patency duration in group A was 24.5±21.9 months (range, 2.2 to 82.4 months), and that in group B was, 17.7±13.6 months (range, 0.03 to 48.8 months). The result indicates that there was no significant difference in the primary AVF patency duration between the two groups. The secondary AVF patency duration in group A was 28.0±40.1 months (range, 0.03 to 104.1 months), and that in group B was, 17.3±26.0 months (range, 0.03 to 63.6 months). Again, no statistically significant difference was observed in the secondary AVF patency duration between the two groups. Among the seven patients in whom AVF occlusion did not recur after the rescue therapy, five were from group A and two were, from group B.

The annual frequency of AVF occlusion in group A was

Table 2. Comparative analysis related clinical course after rescue therapy therapy the graft repair group (group A) and thrombectomy group (group B)

Variable	Group A	Group B	p-value
Patency duration (mo)	28.0±40.15 (0.03–104.13)	17.3±26.00 (0.03–63.63)	0.310
Arteriovenous fistula occlusion per patient-year	0.59±0.702	0.72±0.665	0.540
Number of new arteriovenous fistula	0.21±0.419	0.21±0.418	0.976

0.59/yr, and that in group B was, 0.72/yr. In group A, the annual frequencies of patch angioplasty with bovine pericardium, patch angioplasty with a PTFE graft, and graft extension were 0.85/yr, 0.20/yr, and 0.57/yr, respectively. The annual frequency of AVF occlusion was higher in group B than in group A, but no statistically significant difference was found between the two groups.

During the follow-up period, AVF formation was also performed in four patients who were unable to undergo rescue therapy with graft AVF due to severe injury. Two of these four patients were from group A and the other two were, from group B, but no statistically significant difference was found between the two groups (Table 2).

The patency rates of AVF after the initial surgery in the groups were compared using the Kaplan-Meier method. The seven patients in whom AVF occlusion did not recur were followed-up until December 31, 2013. The one-, two-, three-, and five-year AVF patency rates in group A were 52.6%, 31.5%, 21.0%, and 15.7% respectively, and in group B, 32.1%, 25.0%, 17.8%, and 7.14%, respectively. No significant difference was found in the AVF patency rates between the two groups (p=0.402) (Fig. 2).

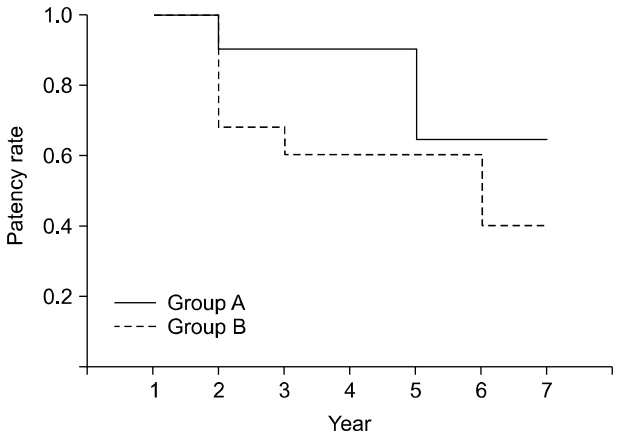

Fig. 2. Kaplan-Meier patency rate curves for the graft repair group (group A) and thrombectomy group (group B).

DISCUSSION

Chronic renal failure requires renal replacement treatments such as dialysis or renal transplantation. In Korea, more than 10,000 people were diagnosed with chronic renal failure in 2012. Seventy-five percent of people who undergo renal replacement therapy also undergo hemodialysis [4]. Therefore, for patients who undergo hemodialysis, AVF that guarantees a adequate blood flow is very important. In general, native AVF has a better patency rate than a graft AVF [5]. In 79% of the cases, a native vessel was used for the AVF formation procedures performed in Korea in 2012 [4]. However, the rate of performance of graft AVF formation is expected to increase gradually. In the United States, graft AVF formation recently accounted for 60% of all AVF formation procedures performed [6]. Today, most patients with chronic renal failure are older than those in the past. Most of these patients have concurrent severe diseases such as diabetes and hypertension. These conditions lead to peripheral vessel narrowing and atherosclerotic change. Therefore, it is becoming increasingly difficult to perform native AVF formation, and hence, the case of graft AVF formation are expected to increase [7,8].

In general, graft AVF has a lower long-term patency rate than native AVF, so it is very important to conduct studies for assessing the improvement of the patency rate of graft AVF and for determining the rescue therapy which treats thrombotic occlusion appropriately. Thus, further studies on graft and various treatment strategies for rescue therapy are required for improving the patency rate.

According to previous studies, the annual frequency of graft AVF occlusion has been reported to be 0.25 to 1.4/yr/patient [9]. In this study, the annual frequency of graft AVF occlusion in all of the patients of 0.66 was within this range. Graft AVF occlusion can be classified into short and long-term occlusion. The causes of short-term graft AVF occlusion include improper use of arteries and veins, improper anticoagulation therapy during surgery, bending and twisting

of the vascular graft, and excessive pressure or bleeding. Long-term graft AVF occlusion is known to be mainly caused by venous anastomic intimal hyperplasia [10]. Various treatments are required to prevent these causes and to correct AVF occlusion.

This study was conducted to develop a strategy for surgically removing excessive intimal hyperplasia, which is considered to be the main cause of long-term AVF occlusion. Severely damaged segment of the graft by repeated puncture, can be repaired during the surgical rescue therapy. The graft repair is performed to reconstruct the graft when the inner diameter of the graft becomes too narrow, so that the graft AVF can be effectively patent. Proactive graft repair may also preserve the blood vessels to be used in the future with good condition for a long time.

Homogeneity of the graft can be obtained after the graft repair by surgical removal of intimal hyperplasia and replacement of damaged graft segment. Homogeneity of inner surface of graft may useful to maintain the AVF longer. In this study, mean AVF patency duration in the graft repair group was 20.8 months, which was 3.5 months longer than that of thrombectomy alone group. The graft repair tend to prolong the operation time than thrombectomy, but it is not a significant problem. Furthermore, as the site of the damaged graft, which could be the main cause of AVF occlusion, is removed and then reconstructed, a homogenous blood contact surface may be achieved and the inner diameter of the graft may returns to normal, this technique would recover the laminar flow. Therefore, graft repair is useful as a rescue therapy for graft AVF occlusion.

This study is meaningful since the entire process from the performance of the rescue therapy to the study end-point was analyzed in detail according to the time to AVF occlusion after AVF formation with a prosthetic graft, and the rescue therapy method used to correct the AVF occlusion. However, it was difficult to determine the statistical significance of the study results due to the small number of subjects considered, which was the limitation of this study. Nonetheless, the efficacy and safety of graft repair were validated in this study. A further large-scale study is required to obtain more concrete evidence.

In conclusion, in patients with chronic renal failure who underwent hemodialysis via graft AVF, the graft repair group and the thrombectomy alone group were compared with respect to AVF occlusion. The results showed no statistically significant differences in the AVF patency duration and the annual frequency of the AVF occlusion between the two groups. Therefore, we suggest that graft repair is safer as a rescue therapy for AVF occlusion due to intimal hyperplasia and severe stenosis and it is also useful for increasing the effective patency duration of the AVF.

CONFLICT OF INTEREST

No potential conflict of interest relevant to this article was reported.

ACKNOWLEDGMENTS

This study was supported by a Grant of the Samsung Vein Clinic Network (Daejeon, Anyang, Cheongju, Cheonan) (Fund No. KTCS04-019).

REFERENCES

1. Sicard GA, Allen BT, Anderson CB. *PTFE grafts for vascular access.* In: Sommer BG, Henry ML, editors. *Vascular access for hemodialysis.* Chicago (IL): Pluribus Press; 1989. p. 17-31.
2. Schild AF, Perez E, Gillaspie E, Seaver C, Livingstone J, Thibonnier A. *Arteriovenous fistulae vs. arteriovenous grafts: a retrospective review of 1,700 consecutive vascular access cases.* J Vasc Access 2008;9:231-5.
3. Kang HS, Han KD, Choi EH, Park YS, Seo YH, Kim CS. *The comparative analysis between surgical thrombectomy and hybrid treatment in salvage operation.* Korean J Vasc Endovasc Surg 2012;28:207-11.
4. ESRD Registry Committee, Korean Society of Nephrology. *Current renal replacement therapy in Korea 2013.* Seoul: Korean Society of Nephrology; 2013.
5. Kim DS, Kim SW, Kim JC, Cho JH, Kong JH, Park CR. *Clinical analysis of hemodialysis vascular access: comparision of autogenous arterioveonus fistula & arteriovenous prosthetic graft.* Korean J Thorac Cardiovasc Surg 2011;44: 25-31.
6. Samuel E. *Vascular access principles and practice.* 5th ed. Philadelphia (PA): Lippincott Williams & Wilkins; 2010.
7. Jung HW, Lim YH, Lee YJ, et al. *The patency rate of he-*

modialysis vascular access and the analysis of patency-related factors: comparision of native arteriovenous fistula with arteriovenous graft, single center study. Korean J Nephrol 2008;27:70-7.

8. Dixon BS, Novak L, Fangman J. *Hemodialysis vascular access survival: upper-arm native arteriovenous fistula.* Am J Kidney Dis 2002;39:92-101.
9. Pereira BJ, Sayegh MH, Blake PG. *Chronic kidney disease, dialysis and transplantation: a companion to Brenner and Rector's the kidney.* 2nd ed. Philadelphia (PA): Saunders; 2005.
10. Kim SJ, Min SG. *Vascular access for hemodialysis.* Seoul: BMB; 2012.