

## RESEARCH ARTICLE

# *Opisthorchis viverrini* Infection Activates the PI3K/AKT/PTEN and Wnt/ $\beta$ -catenin Signaling Pathways in a Cholangiocarcinogenesis Model

Supak Yothaisong<sup>1,4</sup>, Malinee Thanee<sup>1,4</sup>, Nisana Namwat<sup>1,4</sup>, Puangrat Yongvanit<sup>1,4</sup>, Thidarut Boonmars<sup>2,4</sup>, Anucha Puapairoj<sup>3,4</sup>, Watcharin Loilome<sup>1,4\*</sup>

## Abstract

*Opisthorchis viverrini* (Ov) infection is the major etiological factor for cholangiocarcinoma (CCA), especially in northeast Thailand. We have previously reported significant involvement of PI3K/AKT/PTEN and Wnt/ $\beta$ -catenin in human CCA tissues. The present study, therefore, examined the expression and activation of PI3K/AKT/PTEN and Wnt/ $\beta$ -catenin signaling components during Ov-induced cholangiocarcinogenesis in a hamster animal model. Hamsters were divided into two groups; non-treated and Ov plus NDMA treated. The results of immunohistochemical staining showed an upregulation of PI3K/AKT signaling as determined by elevated expression of the p85 $\alpha$ -regulatory and p110 $\alpha$ -catalytic subunits of PI3K as well as increased expression and activation of AKT during cholangiocarcinogenesis. Interestingly, the staining intensity of activated AKT (p-AKT) increased in the apical regions of the bile ducts and strong staining was detected where the liver fluke resides. Moreover, PTEN, a negative regulator of PI3K/AKT, was suppressed by decreased expression and increased phosphorylation during cholangiocarcinogenesis. We also detected upregulation of Wnt/ $\beta$ -catenin signaling as determined by increased positive staining of Wnt3, Wnt3a, Wnt5a, Wnt7b and  $\beta$ -catenin, corresponded with the period of cholangiocarcinogenesis. Furthermore, nuclear staining of  $\beta$ -catenin was observed in CCA tissues. Our results suggest the liver fluke infection causes chronic inflammatory conditions which lead to upregulation of the PI3K/AKT and Wnt/ $\beta$ -catenin signaling pathways which may drive CCA carcinogenesis. These results provide useful information for drug development, prevention and treatment of CCA.

**Keywords:** *Opisthorchis viverrini* - PI3K/AKT/PTEN - Wnt/ $\beta$ -catenin - cholangiocarcinoma

*Asian Pac J Cancer Prev*, 15 (23), 10463-10468

## Introduction

*Opisthorchis viverrini* (Ov) infection has been recognized as a major cause of cholangiocarcinoma (CCA), a malignant tumor arising from the biliary tract epithelia which is a major public health problem in northeast Thailand, where the highest prevalence of CCA in the world is reported (Sithithaworn and Haswell-Elkins, 2003; Sripa et al., 2007). It is well documented that chronic inflammation induced by the carcinogenic liver fluke infection is the major risk factor of CCA in Thailand (Yongvanit et al., 2012). The results from epidemiologic investigations and animal models have demonstrated a strong relationship between Ov infection and CCA development (Thamavit et al., 1978; Watanapa and Watanapa, 2002).

Current understanding of the molecular underpinnings of CCA development as well as tumor treatment response is still unclear and requires more comprehensive research

to better understand and improve appropriate CCA prevention and treatment. To identify the candidate genes underlying Ov-induced CCA, we have previously investigated candidate genes that may underly Ov and NDMA-induced CCA in a hamster animal model and found that 1 downregulated and 23 upregulated transcripts are involved in CCA development (Loilome et al., 2006). Among the upregulated genes, the signal transduction protein kinase A regulatory subunit I $\alpha$  (*Prkar1a*) has been observed to be involved in CCA development and progression (Loilome et al., 2006). Moreover, *Prkar1a* inhibition lead to apoptosis in CCA cells together with a decrease in several protein kinase pathways, including PI3K/AKT, Wnt/ $\beta$ -catenin, JAK/STAT and MAPK signaling (Loilome et al., 2011). Recently, we have reported multiple kinases that are activated in both CCA cell lines and human CCA tissues, including the PI3K/AKT, Wnt/ $\beta$ -catenin, JAK/STAT and MAPK signaling pathways (Dokduang et al., 2013). Furthermore, we

<sup>1</sup>Department of Biochemistry, <sup>2</sup>Department of Parasitology, <sup>3</sup>Department of Pathology, Faculty of Medicine, <sup>4</sup>Liver Fluke and Cholangiocarcinoma Research Center, Khon Kaen University, Khon Kaen, Thailand \*For correspondence: watloi@yahoo.com

have demonstrated that the constitutive activation of PI3K/AKT pathway in human CCA tissues is due to the loss of PTEN expression as well as PTEN inactivation. Moreover, inhibition of PI3K/AKT pathway showed anti-cancer activity against CCA cells (Yothaisong et al., 2013). Apart from PI3K/AKT, we have also recently demonstrated the abundant expression of the Wnt protein family and  $\beta$ -catenin in human CCA tissues. Interestingly, inflammatory condition can cause Wnt/ $\beta$ -catenin activation in CCA cells (Loilome et al., 2014). The present study examined whether the alteration of PI3K/AKT/PTEN and Wnt/ $\beta$ -catenin signaling pathway occurred during Ov-induced CCA carcinogenesis in a hamster model. The results can provide insights into the molecular mechanism(s) which drive CCA development in order to develop therapeutic strategies to prevent CCA carcinogenesis.

## Materials and Methods

### Animals and tumor induction

The animal experiments were conducted according to the guidelines of the National Committee of Animal Ethics and the protocol was approved by the Animal Ethics Committee of the Faculty of Medicine, Khon Kaen University, Thailand (#AE002/2002). An induction of CCA in hamsters was done by combination treatment between Ov metacercariae infection and NDMA according to a previous study (Loilome et al., 2006). Male Syrian golden hamsters aged 6-8 weeks were divided into 2 groups: Group 1 was untreated and served as the control group; Group 2 was fed 50 Ov metacercariae by intragastric intubation combined with oral administration of 12.5 ppm NDMA (Sigma, St. Louis, MO, USA) for 2 months. Animals were fed a stock diet and water ad

libitum, housed under conventional conditions, and were sacrificed on days 14, 30, 90 and 180 after treatment. Liver tissue was collected and fixed in 10% (v/v) neutral buffered formalin and embedded in paraffin according to standard techniques. Samples were used for histological and immunohistochemical examinations.

### Immunohistochemical analysis

An alteration of several key protein components of the PI3K/AKT/PTEN and Wnt/ $\beta$ -catenin signaling pathways during CCA carcinogenesis was investigated by immunohistochemistry (IHC) staining. According to the IHC standard method, the paraffin embedded tissues were sectioned and mounted on poly-lysine-coated glass slides and air-dried overnight at room temperature, followed by deparaffinization with xylene for 5 min, two times. Slides were then rehydrated by decreasing concentrations of ethanol in twice for 5 min as follows: 100% ethanol, 90% ethanol, 80% ethanol and 70% ethanol. Rehydrated sections were kept in phosphate buffered saline (PBS) with subsequent by antigen retrieval in 100 mM sodium citrate buffer (pH 6.0) for 10 min in microwave oven. Sections were immersed in 0.3% hydrogen peroxide in PBS (V/V) for 30 min in order to quench their endogenous peroxidase activity. After blocking with 10% skim milk (w/v) in PBS for 45 min, the sections were incubated with the diluted primary antibody in PBS at 4°C overnight, as listed in Table 1. The sections were washed three times with PBS containing 0.1% (V/V) Tween 20 for 5 min and once times for PBS 5 min. Then, the sections were incubated with peroxidase-conjugated Envision™ secondary antibody (DAKO, Denmark) for 1h, and a peroxidase-labeled polymer, 0.1% diaminobenzidine tetrahydrochloride (DAB) solution was used for signal development for 10 min. After stopping the reaction

**Table 1. Primary Antibodies Used for Immunohistochemical Analysis**

Proteins	Clone	Company	Catalog no.	Dilution
PI3K(p85 $\alpha$ )	Polyclonal	Cell Signaling Technology (Danvers, MA)	4292	1:50
PI3K(p110 $\alpha$ )	Monoclonal	Cell Signaling Technology (Danvers, MA)	4249	1:50
Total-AKT1	Monoclonal	Abcam (Cambridge, MA)	ab32505	1:50
p-AKT(T308)	L32A4	Cell Signaling Technology (Danvers, MA)	5106	0.100
Total-PTEN	138G6	Cell Signaling Technology (Danvers, MA)	9559	1:50
p-PTEN(S380,T382/383)	Polyclonal	Abcam (Cambridge, MA)	ab47332	0.100
Wnt3	Polyclonal	Abcam (Cambridge, MA)	ab32249	0.300
Wnt3a	Polyclonal	Abcam (Cambridge, MA)	ab28472	0.200
Wnt5a	Polyclonal	Abcam (Cambridge, MA)	ab72583	1:50
W7b	Polyclonal	Abcam (Cambridge, MA)	ab94915	0.100
$\beta$ -catenin	Monoclonal	BD (Biosciences, San Jose, CA)	610154	1:50

**Table 2. The Expression and Localization of All Proteins in Each Cell Type**

Proteins	Normal bile duct	Hepatocyte	Inflammatory cell	Hyperplastic bile duct	Dysplastic bile duct	CCA
PI3K(p85 $\alpha$ )	+/-C	-	+C	+C	+C	+C
PI3K(p110 $\alpha$ )	-	+C	-	+C	+C	+C
Total-AKT1	+/-C	+/-C	+C, N	+C, N	+C, N	+C, N
p-AKT (T308)	-	+C	+C	+C	+C	+C
Total-PTEN	+C	+C	+C	+C	+/-C	+/-C
p-PTEN(S380, T382/383)	+/-C	+C	+C	+C	+C	+C,N
Wnt3	-	+C	+C,N	+C	+C,N	+C,N
Wnt3a	+/-M,C	+C,N	+C	+M,C	+M,C,N	+M,C,N
Wnt5a	+/-C	+C	+C	+C	+C	+C,N
W7b	-	-	+C	+C,N	+C,N	+C,N
$\beta$ -catenin	+/-M,C	-	+M,C,N	+M,C	+M,C,N	+M,C,N

\*Abbreviation C: cytoplasm, M: membrane, N: nucleus

in PBS, nuclear counterstaining was performed with Mayer's hematoxylin for 2 min. Finally, the sections were dehydrated through increasing concentrations of ethanol and mounted. For negative controls, incubation step with the primary antibody was omitted to detect any background staining or false-positive results. The stained sections were observed under a light microscope by using the high magnification power  $\times 200$  and  $\times 400$  (Axioscope A1, Carl Zeiss, Jena, Germany).

## Results

### *Histopathological changes*

Hamster liver tissues were collected at different times following treatment with Ov plus NDMA. The histological results confirmed the results of previous studies (Loilome et al., 2006). Briefly, the histopathological change was not detected in bile duct epithelial cells of the non-treated group. There were pathological changes have been observed as hyperplastic lesions at 30 days post-infection, precancerous lesions at 90 days post-infection and cancer at day 180 post-infection (p.i.) in Ov plus NDMA treated hamsters, respectively.

### *Altered expression of PI3K and increased activation of AKT along with PTEN suppression during CCA cholangiocarcinogenesis of Ov-infected hamster*

The expression pattern of PI3K/AKT/PTEN signaling molecules including PI3K-p85 $\alpha$ , PI3K-p110 $\alpha$ , AKT1,

p-AKT (T308), PTEN and p-PEN (S380, T382/383) during the carcinogenesis of Ov-induced hamster CCA was examined by IHC staining. The results are shown in Figure 1.

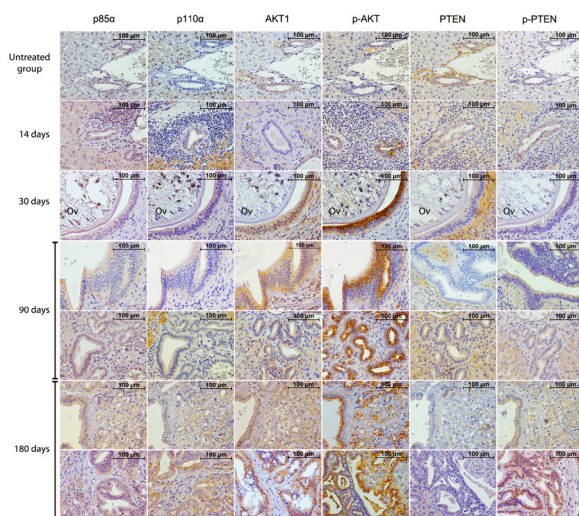
The expressions of two PI3K subunits, p85 $\alpha$  and p110 $\alpha$  were observed in cytoplasm of bile duct epithelia. A faint positive stain was seen in normal bile ducts of the untreated group. The intensity and frequency of p85 $\alpha$  positively stained bile duct epithelia increased in a time dependent manner in from hyperplastic bile ducts (14 days p.i), dysplastic bile ducts (90 days p.i) to cancer cells (180 days p.i.). Positive staining was observed also in inflammatory cells. A negative immunoreactivity for p110 $\alpha$  was detected in the normal biliary cells of the untreated group. In Ov plus NDMA treated groups, an intense p110 $\alpha$  staining was mainly detected in cancer cells developed at 180 days p.i. whereas low positive signals were observed at 14 days p.i., 30 days p.i. and 90 days p.i., respectively.

A very faint cytoplasmic signal of AKT1 staining was observed in the normal bile ducts of untreated group. In the Ov plus NDMA treated groups, the intensity of AKT1 positive stained cells increased in a time dependent manner during cholangiocarcinogenesis and the highest positive signal was seen when tumor has fully developed (180 days p.i.). Interestingly, nuclear staining of AKT1 was clearly observed in hyperplastic bile duct cells (30 days p.i), dysplastic bile duct cells (90 days p.i) as well as CCA cells and the highest positive signals were seen in cancer cells (180 days p.i.). An expression of p-AKT (T308) was not detected in the bile ducts of the untreated group. In Ov plus NDMA treated groups, the expression of p-AKT (T308) was detected in the cytoplasm of bile duct epithelia and the staining intensity is gradually increased during carcinogenesis process starting from 14 days to 180 days p.i especially the area where the liver fluke inhabit. In addition, the positive staining signals were seen also in hepatocytes and inflammatory cells.

The expression of PTEN was observed in normal bile duct cells. In the Ov plus NDMA treated group, decreased PTEN expression was detected along with the carcinogenesis processes especially in precancerous lesion (90 days p.i) and CCA tissues (180 days p.i.) where absent or very weak expression was found. Moreover, the expression of PTEN in the stromal cells, including fibroblasts, lymphocytes, and endothelial cells was higher than normal bile ducts, hyperplasia, precancerous and CCA tissues. In addition, weak positive staining of phosphorylated PTEN (p-PTEN) was detected in the untreated control group as well as at 14 days p.i. and 30 days p.i. of the Ov plus NDMA treated group while progressively increased of p-PTEN in dysplastic bile ducts (90 days p.i.) and cancer cells (180 days p.i.). Interestingly, the expression of p-PTEN in CCA cells was observed in both the nucleus and cytoplasm, whereas no nuclear staining was detected in other treatment groups.

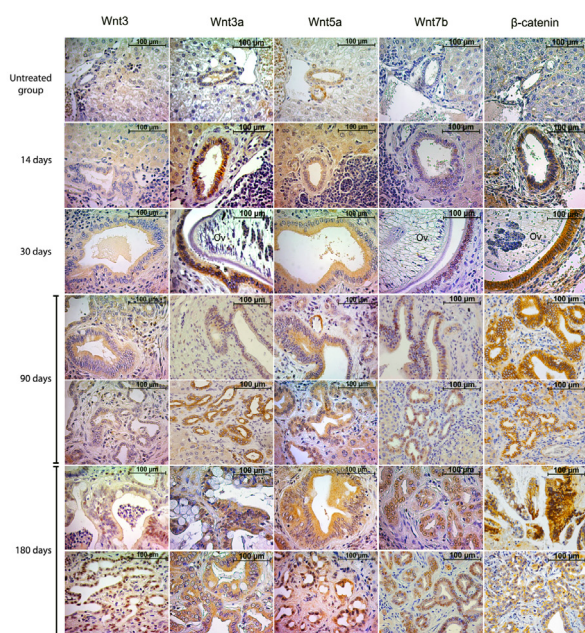
### *Wnt/ $\beta$ -catenin signaling pathway expression increased along with carcinogenesis processes*

Furthermore, we investigated the expression and localization of Wnt proteins including Wnt3, Wnt3a,



**Figure 1. Expression of Protein Components of the PI3K/AKT/PTEN Signaling Pathway in Hamster Liver Tissues at 14, 30, 90 and 180 Days Post-treatment Compared with an Untreated Group.** In the untreated group, weak positive signal of p85 $\alpha$ , AKT1, PTEN and p-PTEN were detected in biliary epithelia but negative staining of p110 $\alpha$  and p-AKT (T308) was observed. In the treatment groups, expressions of p85 $\alpha$ , p110 $\alpha$ , AKT1, p-AKT (T308) and p-PTEN (S380, T382/383) in biliary epithelia increased conforming to CCA carcinogenesis. In contrast, weak or no staining of PTEN in biliary epithelia was detected in precancerous and cancerous tissues at 90 and 180 days post-treatment, respectively. Nuclear staining of p110 $\alpha$  was detected at 90 and 180 days post-treatment. Nuclear staining of p-PTEN (S380, T382/383) was observed in the CCA group at 180 days post-treatment





**Figure 2. Expression of Protein Components of The Wnt/  $\beta$ -catenin Signaling Pathway in Hamster Liver Tissues at 14, 30, 90 and 180 days Post-Treatment Compared with an Untreated Group.** In the untreated group, poor signals of Wnt3a, Wnt5a and  $\beta$ -catenin in biliary epithelia were detected but no signal was detected for Wnt3 and Wnt7b. In treatment groups, expressions of all proteins in biliary epithelia increased in a time dependent manner during CCA carcinogenesis. Nuclear staining of Wnt7b was observed in all post-treatment time points. Nuclear staining of Wnt3, Wnt3a and  $\beta$ -catenin was detected in precancerous and cancerous tissues at 90 and 180 days post-treatment, respectively. Nuclear staining of Wnt5a was found only in the CCA group at 180 days after treatment

Wnt5a and Wnt7b as well as  $\beta$ -catenin, which are key effectors of canonical Wnt signaling during tumorigenesis of opisthorchiasis-associated CCA in a hamster model. The results are shown in Figure 2.

In the control group, the expression of Wnt3 was not observed, whereas the Wnt3 expression increased and was related to the progression of carcinogenesis processes in the treatment groups. At 14 days p.i. and 30 days p.i., Wnt3 expression was detected only in the cytoplasm of biliary epithelial cells while positive staining in both cytoplasm and nucleus of Wnt3 was observed at 90 days p.i. at which precancerous bile ducts were developed. The highest positive signal of Wnt3 was found in cytoplasmic and nucleus of cancer cells (180 days p.i.). In addition, positive staining of Wnt3 was seen in cytoplasm of hepatocyte while the expression was observed in cytoplasm and nucleus of inflammatory cells.

Wnt3a expression was detected in both untreated and treated groups. In the untreated group, Wnt3a was expressed in the cytoplasm and cell membrane of biliary epithelial cells, although the signal was faint. The number of positive cells and staining intensity of Wnt3a in cytoplasm and cell membrane were increased in treated groups related to CCA development. In addition, increased nuclear accumulation of Wnt3a was found in precancerous lesions (90 days p.i.) as well as CCA cells (180 days

p.i.). In addition, Wnt3a expression in hepatocytes and inflammatory cells was recognized.

Expression of Wnt5a was found in both the untreated and treated groups. The results show that Wnt5a is localized in the cytoplasm of the normal bile ducts, the hyperplastic bile duct and precancerous lesions. In tumor cells, Wnt5a is localized in both the cytoplasm and the nucleus. The intensity of Wnt5a positive signals increased over the time during the 14 days p.i. to 180 days p.i. at which CCA fully developed. The expression of Wnt5a in cytoplasm of hepatocytes and inflammatory cells was also observed.

No positive immunostaining of Wnt7b was detected in the tissues of the untreated group. In the Ov plus NDMA treated groups, expression of Wnt7b was observed in both the cytoplasm and nucleus of biliary cells and the expression increased in a time dependent manner during carcinogenesis. However, the most intense reaction of Wnt7b immunostaining was prominently seen the nucleus of the bile duct epithelial cells, whereas cytoplasmic staining signals were faint.

We next examined the expression of  $\beta$ -catenin, a key downstream player of the Wnt signaling cascade. As shown in Figure 2,  $\beta$ -catenin immunoreactivity was observed in all animal groups. In the control group, expression of  $\beta$ -catenin exhibited faint cytoplasmic and cell membrane staining in normal biliary cells while there was an increase in the number of positively stained cells in both the cytoplasm and the cell membrane in treatment groups. Moreover, at 90 days p.i. and 180 days p.i. when precancerous lesions and CCA had developed, the remarkable nuclear localization of  $\beta$ -catenin was observed.

The expressions of all proteins in the present study are summarized in Table 2.

## Discussion

Several studies has indicated that CCA is caused by dysregulation of the tumor suppressor genes or oncogenes (Loilome et al., 2011; Namwat et al., 2012; Dokduang et al., 2014) However, the molecular mechanism(s) for CCA carcinogenesis remains unclear. Several studies have demonstrated that alteration of PI3K/AKT/PTEN and Wnt/ $\beta$ -catenin was found in many cancers and these pathways may serve as the potential targets for cancer treatment (Gong et al., 2012; Pandurangan, 2013; Jannesari-Ladani et al., 2014; Tan et al., 2014). This is the first report of the alteration of the protein components comprising the PI3K/AKT/PTEN and Wnt/ $\beta$ -catenin pathway in a hamster model of Ov-induced CCA carcinogenesis. Previous studies, we have demonstrated an increase in PI3K/AKT activation, which correlated with PTEN suppression by loss of activation and phosphorylation in human CCA tissues (Yothaisong et al., 2013). Moreover, another study has indicated that a secretory product, parasitic glutathione S-transferase (GST) produced from Ov can promote cell proliferation through increased activation of AKT (Daorueang et al., 2012). Here we demonstrated an elevated expression as well as activation of the PI3K/AKT pathway during CCA carcinogenesis. Furthermore, strong

staining of p-AKT (T308) was observed in the bile ducts in close proximity to Ov, suggesting that activation of AKT is related to infection and inflammation which might contribute to increased cell proliferation. In addition, increased expression of p110 $\alpha$  in the CCA group was consistent with our previous findings that demonstrated overexpression of p110 $\alpha$  with 90% in human CCA tissues (Yothaisong et al., 2013). In addition, the present study has shown a decreased expression of a tumor suppressor PTEN in the precancerous and CCA groups which was consistent with increased PTEN phosphorylation at these time points. This indicated that the tumor activity of PTEN was suppressed by the loss of expression and phosphorylation as has been shown in previous studies (Yang et al., 2013; Yothaisong et al., 2013). Additionally, these results are consistent with Xu et al., who found similar results in a mouse model (Xu et al., 2006). Moreover, our results show that the positive staining signals of phosphorylated PTEN in CCA group were seen in the cytoplasm as well as in the nucleus of tumor cells. This may be due to the effect of phosphorylation of PTEN at Ser380/Threo382/Threo383 which may promote nuclear accumulation (Patel et al., 2013). Moreover the expression of phosphorylated PTEN has been detected in many cancers, such as lung cancer (David, 2001), prostate cancer (Koumakpayi et al., 2010; Patel et al., 2013), and glioblastoma (Fenton et al., 2012). Therefore, our results suggest that PTEN inactivation by phosphorylation is responsible for PI3K/AKT activation during CCA carcinogenesis.

Recently, we have demonstrated that expression of Wnt3a, Wnt5a, Wnt7b and  $\beta$ -catenin was significantly increased in human CCA tissues (Loilome et al., 2014), which led us to hypothesize that activation of Wnt/ $\beta$ -catenin signaling could also be a driving force during CCA development. Therefore, we investigated the expression of Wnt proteins and a  $\beta$ -catenin in the present study. Our results showed that all the Wnt3, Wnt3a, Wnt5a, Wnt7b proteins examined, and a key downstream  $\beta$ -catenin were up-regulated in Ov-induced hamster CCA. The expression patterns of all Wnt/ $\beta$ -catenin components studied in Ov-induced hamster CCA were consistent with expression patterns in human CCA which we have previously reported (Loilome et al., 2014). Our results show nuclear positive staining in CCA group for all Wnt proteins examined. Positive nuclear staining cells of Wnt3 and Wnt3a occurred in bile ducts in the precancerous lesions (90 days p.i.). Moreover, the nuclear positive staining cells of Wnt7b were found at all time points after treatment with the maximum intensity and maximum numbers of positive staining cells present when tumors had developed. These data suggest that nuclear localization of Wnt proteins may play important roles in cancer development. In addition, Wnt proteins expression are found in the nuclear part of the other cancer types, such as in melanoma (Bachmann et al., 2005; Da Forno et al., 2008) and gastric cancer (Yuan et al., 2013).

Additionally, we revealed that the expression of  $\beta$ -catenin was seen in the membrane and the cytoplasm of positive cells which were observed in both the control and treatment groups. However, the intensity of  $\beta$ -catenin immunoreactivity was faint in the control

group. Furthermore, accumulation of nuclear localization of  $\beta$ -catenin was found in the precancerous lesions (90 days p.i) and increased positive nuclear staining cells with high intensity was found when CCA had fully developed (180 days p.i). These results support previous studies that demonstrated the accumulation of nuclear  $\beta$ -catenin in CCA tissues (Sugimachi et al., 2001; Lim et al., 2008; Loilome et al., 2014).

In conclusion, our results showed that activation of the PI3K/AKT signaling pathway along with PTEN suppression was potentially responsible for Ov-induced CCA development. Moreover, the increased expression of the Wnt protein family during CCA carcinogenesis was related to  $\beta$ -catenin nuclear translocation, which serves as a modulator of cell proliferation. This indicates that increased activation of PI3K/AKT/PTEN and Wnt/ $\beta$ -catenin signaling might be the underlying mechanisms which drive the development of CCA. Therefore, targeting components of these particular pathways may prove beneficial for the development of effective and treatment and prevention strategies for CCA.

## Acknowledgements

This study is supported by the grant of the Thailand Research Fund (Grant No.MRG5400834), the invitation research grant (Grant No. I56130) and the Research Assistantship Grant of the Faculty of Medicine, Khon Kaen University (Grant No. AS55203) to WL, the Scholarship of the Liver Fluke and Cholangiocarcinoma Research Center to SY and the grants from the Higher Education Research Promotion and National Research University Project of Thailand, Office of the Higher Education Commission, through the Center of Excellence in Specific Health Problems in Greater Mekong Sub-region cluster (SHeP-GMS), Khon Kaen University allocated to WL. We thank Professor Ross H Andrews for editing the MS via Publication Clinic KKU, Thailand.

## References

- Bachmann IM, Straume O, Puntervoll HE, et al (2005). Importance of P-cadherin, beta-catenin, and Wnt5a/frizzled for progression of melanocytic tumors and prognosis in cutaneous melanoma. *Clin Cancer Res*, **11**, 8606-14.
- Da Forno PD, Pringle JH, Hutchinson P, et al (2008). WNT5A expression increases during melanoma progression and correlates with outcome. *Clin Cancer Res*, **14**, 5825-32.
- Daorueang D, Thuwajit P, Roittrakul S, et al (2012). Secreted *Opisthorchis viverrini* glutathione S-transferase regulates cell proliferation through AKT and ERK pathways in cholangiocarcinoma. *Parasitol Int*, **61**, 155-61.
- David O (2001). Akt and PTEN: new diagnostic markers of non-small cell lung cancer? *J Cell Mol Med*, **5**, 430-3.
- Dokduang H, Juntana S, Techasen A, et al (2013). Survey of activated kinase proteins reveals potential targets for cholangiocarcinoma treatment. *Tumour Biol*, **34**, 3519-28
- Dokduang H, Techasen A, Namwat N, et al (2014). STATs profiling reveals predominantly-activated STAT3 in cholangiocarcinoma genesis and progression. *J Hepatobiliary Pancreat Sci*, **21**, 767-76.
- Fenton TR, Nathanson D, Ponte de Albuquerque C, et al (2012). Resistance to EGF receptor inhibitors in glioblastoma

- mediated by phosphorylation of the PTEN tumor suppressor at tyrosine 240. *Proc Natl Acad Sci USA*, **109**, 14164-9.
- Gong C, Liao H, Wang J, et al (2012). LY294002 induces G0/G1 cell cycle arrest and apoptosis of cancer stem-like cells from human osteosarcoma via down-regulation of PI3K activity. *Asian Pac J Cancer Prev*, **13**, 3103-7.
- Jannesari-Ladani F, Hossein G, Izadi-Mood N (2014). Differential Wnt11 expression related to Wnt5a in high- and low-grade serous ovarian cancer: implications for migration, adhesion and survival. *Asian Pac J Cancer Prev*, **15**, 1489-95.
- Koumakpayi IH, Le Page C, Mes-Masson AM, et al (2010). Hierarchical clustering of immunohistochemical analysis of the activated ErbB/PI3K/Akt/NF-kappaB signalling pathway and prognostic significance in prostate cancer. *Br J Cancer*, **102**, 1163-73.
- Lim K, Han C, Xu L, et al (2008). Cyclooxygenase-2-derived prostaglandin E2 activates beta-catenin in human cholangiocarcinoma cells: evidence for inhibition of these signaling pathways by omega 3 polyunsaturated fatty acids. *Cancer Res*, **68**, 553-60.
- Loilome W, Bungkanjana P, Techasen A, et al (2014). Activated macrophages promote Wnt/beta-catenin signaling in cholangiocarcinoma cells. *Tumour Biol*, **35**, 5357-67.
- Loilome W, Juntana S, Namwat N, et al (2011). *PRKARIA* is overexpressed and represents a possible therapeutic target in human cholangiocarcinoma. *Int J Cancer*, **129**, 34-44.
- Loilome W, Yongvanit P, Wongkham C, et al (2006). Altered gene expression in *Opisthorchis viverrini*-associated cholangiocarcinoma in hamster model. *Mol Carcinog*, **45**, 279-87.
- Namwat N, Chusorn P, Loilome W, et al (2012). Expression profiles of oncomir miR-21 and tumor suppressor let-7a in the progression of opisthorchiasis-associated cholangiocarcinoma. *Asian Pac J Cancer Prev*, **13**, 65-9.
- Pandurangan AK (2013). Potential targets for prevention of colorectal cancer: a focus on PI3K/Akt/mTOR and Wnt pathways. *Asian Pac J Cancer Prev*, **14**, 2201-5.
- Patel R, Gao M, Ahmad I, et al (2013). Sprouty2, PTEN, and PP2A interact to regulate prostate cancer progression. *J Clin Invest*, **123**, 1157-75.
- Sithithaworn P, Haswell-Elkins M (2003). Epidemiology of *Opisthorchis viverrini*. *Acta Trop*, **88**, 187-94.
- Sripa B, Kaewkes S, Sithithaworn P, et al (2007). Liver fluke induces cholangiocarcinoma. *PLoS Med*, **4**, 201.
- Sugimachi K, Taguchi K, Aishima S, et al (2001). Altered expression of beta-catenin without genetic mutation in intrahepatic cholangiocarcinoma. *Mod Pathol*, **14**, 900-5.
- Tan HK, Moad AI, Tan ML (2014). The mTOR signalling pathway in cancer and the potential mTOR inhibitory activities of natural phytochemicals. *Asian Pac J Cancer Prev*, **15**, 6463-75.
- Thamavit W, Bhamarapravati N, Sahaphong S, et al (1978). Effects of dimethylnitrosamine on induction of cholangiocarcinoma in opisthorchis viverrini-infected syrian golden hamsters. *Cancer Res*, **38**, 4634-9.
- Watanapa P, Watanapa WB (2002). Liver fluke-associated cholangiocarcinoma. *Br J Surg*, **89**, 962-70.
- Xu X, Kobayashi S, Qiao W, et al (2006). Induction of intrahepatic cholangiocellular carcinoma by liver-specific disruption of Smad4 and Pten in mice. *J Clin Invest*, **116**, 1843-52.
- Yang Z, Yuan XG, Chen J, et al (2013). Reduced expression of PTEN and increased PTEN phosphorylation at residue Ser380 in gastric cancer tissues: a novel mechanism of PTEN inactivation. *Clin Res Hepatol Gastroenterol*, **37**, 72-9.
- Yongvanit P, Pinlaor S, Bartsch H (2012). Oxidative and nitrate DNA damage: key events in opisthorchiasis-induced carcinogenesis. *Parasitol Int*, **61**, 130-5.
- Yothaisong S, Dokduang H, Techasen A, et al (2013). Increased activation of PI3K/AKT signaling pathway is associated with cholangiocarcinoma metastasis and PI3K/mTOR inhibition presents a possible therapeutic strategy. *Tumour Biol*, **34**, 3637-48.
- Yuan G, Regel I, Lian F, et al (2013). WNT6 is a novel target gene of caveolin-1 promoting chemoresistance to epirubicin in human gastric cancer cells. *Oncogene*, **32**, 375-87.