

## Radiolucent rim as a possible diagnostic aid for differentiating jaw lesions

Hamed Mortazavi<sup>1</sup>, Maryam Baharvand<sup>1,\*</sup>, Somayeh Rahmani<sup>1</sup>, Soudeh Jafari<sup>1</sup>, Parvin Parvaei<sup>1</sup>

<sup>1</sup>Department of Oral Medicine, School of Dentistry, Shahid Beheshti University of Medical Sciences, Tehran, Iran

### ABSTRACT

In this study, we formulate a new proposal that complements previous classifications in order to assist dental practitioners in performing a differential diagnosis based on patients' radiographs. We used general search engines and specialized databases such as Google Scholar, PubMed, PubMed Central, MedLine Plus, Science Direct, Scopus, and well-recognized textbooks to find relevant studies by using keywords such as "jaw disease," "jaw lesions," "radiolucent rim," "radiolucent border," and "radiolucent halo." More than 200 articles were found, of which 70 were broadly relevant to the topic. We ultimately included 50 articles that were closely related to the topic of interest. When the relevant data were compiled, the following eight lesions were identified as having a radiolucent rim: periapical cemento-osseous dysplasia, focal cemento-osseous dysplasia, florid cemento-osseous dysplasia, cemento-ossifying fibroma, osteoid osteoma, osteoblastoma, odontoma, and cementoblastoma. We propose a novel subcategory, jaw lesions with a radiolucent rim, which includes eight entities. The implementation of this new category can help improve the diagnoses that dental practitioners make based on patients' radiographs. (*Imaging Sci Dent 2015; 45: 253-61*)

**KEY WORDS:** Jaw diseases, Diagnosis, Osseous Dysplasia

### Introduction

Despite the development of several modern imaging modalities, the radiograph remains the first and the most important mode of investigation for evaluating jaw lesions.<sup>1</sup> Many jaw lesions resemble each other radiographically, making them difficult to diagnose correctly.<sup>2</sup> Focusing on the patient's history, along with an analytical approach to radiographs, helps to narrow the differential diagnosis.<sup>1</sup> Some authors have developed classifications and guidelines to help clinicians evaluate radiographs more precisely.<sup>1-3</sup> Wood and Goaz<sup>4</sup> presented one of the most comprehensive classifications in 1997. In this classification, jaw lesions are categorized into three major groups depending on whether their radiographic appearance is completely radiolucent, mixed, or totally radio-

paque. Each group is divided into several subgroups that represent a subclassification of the lesions based on more subtle radiographic differences. The main categories of their classification are periapical radiolucencies, pericoronal radiolucencies, inter-radicular radiolucencies, solitary cyst-like radiolucencies not necessarily contacting teeth, multilocular radiolucencies, solitary radiolucencies with ragged and poorly defined borders, multiple separate well-defined radiolucencies, mixed radiolucent-radiopaque lesions associated with or without teeth, periapical radiopacities, solitary radiopacities not necessarily contacting teeth, multiple separate radiopacities, and generalized radiopacities.

Based on a review of the literature, we propose a new subcategory, jaw lesions with a radiolucent rim, which contains eight entities (Table 1). When a clinician encounters a lesion with a radiolucent rim, he/she should first consider these entities in the differential diagnosis. This will help dental practitioners make more accurate diagnoses and better treatment plans based on patients' radiographs.

Received June 22, 2015; Revised September 1, 2015; Accepted September 5, 2015

\*Correspondence to : Prof. Maryam Baharvand

Department of Oral Medicine, School of Dentistry, Shahid Beheshti University of Medical Sciences, Chamran Highway, Tabnak St., Daneshjoo Blvd, Zip code: 1983963113, Tehran, Iran  
Tel) 98-21-29902311, Fax) 98-21-22403194, E-mail) m-baharvand@sbm.ac.ir

Copyright © 2015 by Korean Academy of Oral and Maxillofacial Radiology

This is an Open Access article distributed under the terms of the Creative Commons Attribution Non-Commercial License (<http://creativecommons.org/licenses/by-nc/3.0>) which permits unrestricted non-commercial use, distribution, and reproduction in any medium, provided the original work is properly cited.

Imaging Science in Dentistry · pISSN 2233-7822 eISSN 2233-7830

**Table 1.** General characteristics of jaw lesions with a radiolucent rim

Entity	Gender predilection	Age predilection (years)	Most commonly affected jaw	Region	Distinguishing features
Periapical cemento-osseous dysplasia	F > M	> 30	Mandible	Anterior	Vital involved teeth, circular, size < 1 cm, often multiple lesions
Focal cemento-osseous dysplasia	F > M	Mean = 37	Mandible (86%)	Posterior	Local jaw expansion and mild discomfort
Florid cemento-osseous dysplasia	F > M	Middle-aged to elderly	Both jaws	Molar-premolar	Bilateral, often symmetrical, and usually extensive lesions in all four posterior quadrants
Cemento-ossifying fibroma	F > M	10-40	Mandible (93%)	Molar (61%)	Round, expansive, painless, slow-growing mass, possible displacement of adjacent teeth roots and root resorption
Osteoid osteoma	F > M	Mean = 19	Long bones (80%), jaws (1%)		Nocturnal pain
Osteoblastoma	F > M	Mean = 23	Mandible (74%)	Mandibular body	Slight pain, swelling, and expansion of bone cortex
Compound odontoma	F > M	Children and adolescents	Maxilla	Anterior	Pericoronal lesions with denticles Slow and non-aggressive growth
Complex odontoma	F > M		Mandible	Posterior	
Cementoblastoma	M > F	10-30	Mandible	First molar	Nodular expansive, asymptomatic lesion

## Literature review

We used general search engines and specialized databases such as Google Scholar, PubMed, PubMed Central, MedLine Plus, Science Direct, Scopus, and well-recognized textbooks to find relevant studies by using keywords such as “jaw disease,” “jaw lesions,” “radiolucent rim,” “radiolucent border,” and “radiolucent halo.” More than 200 articles were found, of which 70 were broadly relevant to the topic. We ultimately included 50 articles that were closely related to the topic of interest. When the relevant data were compiled, the following eight lesions were identified as having a radiolucent rim: periapical cemento-osseous dysplasia, focal cemento-osseous dysplasia, florid cemento-osseous dysplasia, cemento-ossifying fibroma, osteoid osteoma, osteoblastoma, odontoma, and cementoblastoma. We propose a novel subcategory, jaw lesions with a radiolucent rim, which includes eight entities. The implementation of this new category can help improve the diagnoses that dental practitioners make based on patients’ radiographs.

### Definition of a radiolucent rim

A radiolucent rim or soft-tissue capsule is a kind of well-

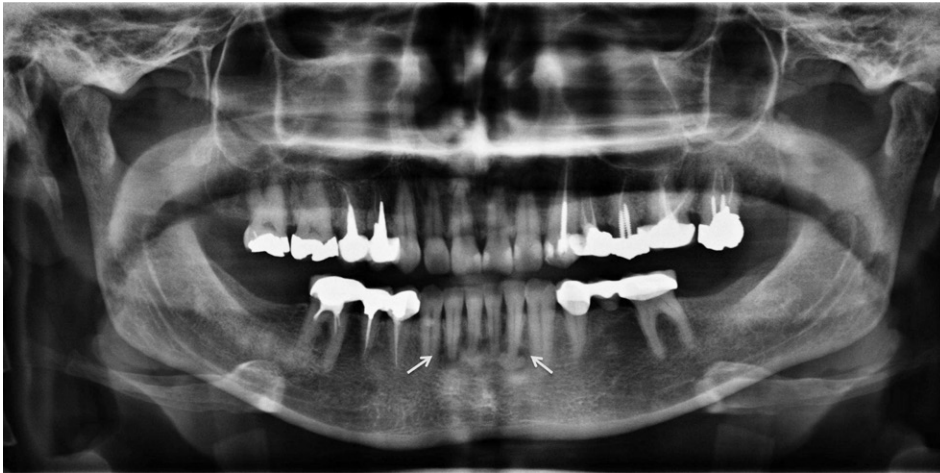defined border at the periphery of radiopaque jaw lesions that presents as a radiolucent line. It can be observed in association with a corticated border.<sup>1-3</sup>

### Osseous dysplasia/cemento-osseous dysplasia

The most common fibro-osseous lesion is cemento-osseous dysplasia. It is considered to be a non-neoplastic fibro-osseous lesion in which bone is replaced by fibrous connective tissue along with cemental masses.<sup>5</sup> In a 2005 publication, the World Health Organization described three clinical presentations of osseous dysplasia/cemento-osseous dysplasia: periapical, focal, and florid osseous dysplasia/cemento-osseous dysplasia.<sup>6</sup>

In many cases of cemento-osseous dysplasias, evaluating intraoral radiographs suffices for diagnosis. The radiographic findings of all subtypes of cemento-osseous dysplasia lesions can be divided into an early stage (radiolucency without radiopaque inclusion), a mixed stage (radiolucency with radiopaque inclusion), and a mature (radiopaque) stage.<sup>7</sup>

Kawai et al.<sup>8</sup> classified cemento-osseous dysplasia lesions into six types based on the following radiographic parameters: (A) radiolucency, (B) calcifications, (C) target appearance, (D) lobular or spherical calcified masses, (E)



**Fig. 1.** A panoramic radiograph shows a radiolucent rim at the periphery of lesions (arrows) diagnosed as periapical cemento-osseous dysplasia.

multiple periapical radiopacities, and (F) active hypercementosis in multiplex form. They studied the radiographic findings of 54 patients, and found that Type D was the most frequent pattern, manifesting as lobular or spherical calcified masses enveloped by a complete or partial radiolucent rim. In partially radiolucent rims, calcified masses were in close proximity to the peripheral bone without any association with the neighboring teeth. Type C was the second most common pattern, occurring in 35% of cases. The pathognomonic radiographic features in the diagnosis of cemento-osseous dysplasia lesions are features C and D. The presence of a radiolucent rim at the periphery of radiopacities is also very significant for diagnosis.<sup>8</sup>

Alsufyani and Lam<sup>9</sup> found that the frequency of a radiolucent rim or band at the periphery of cemento-osseous dysplasia was 78.4% when the images were interpreted by oromaxillofacial radiologists, but 64% when analyzed by general dentists. Likewise, the studies of Alsufyani and Lam,<sup>7</sup> Kawai et al.,<sup>8</sup> Beylouni et al.,<sup>10</sup> and Brannon and Fowler<sup>11</sup> noted the presence of a complete or partial radiolucent rim in cases of cemento-osseous dysplasia.

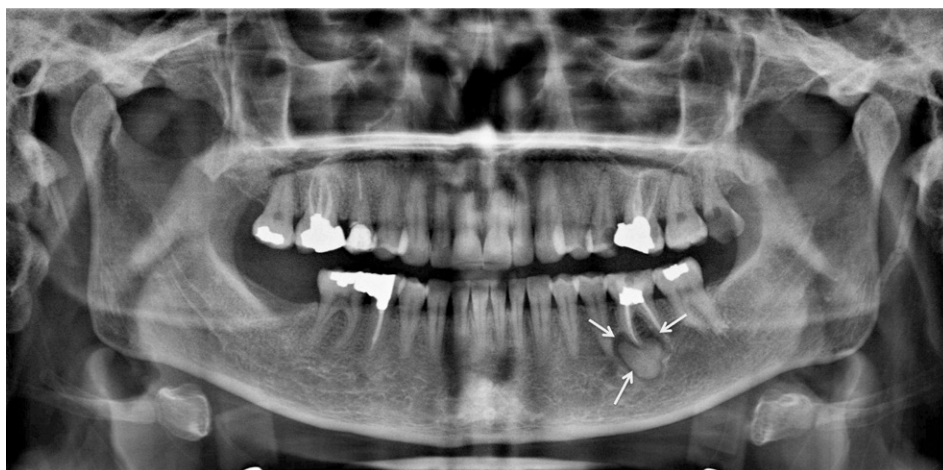
#### Periapical cemento-osseous dysplasia

Periapical cemento-osseous dysplasia arises in the anterior mandible, generally in patients over 30 years of age. A female predilection has been found, and almost 70% of cases occur in blacks. Periapical cemento-osseous dysplasia has no symptoms and the teeth in the affected area remain vital. Hence, the lesion is detected in routine radiographs. A majority of periapical cemento-osseous dysplasias are delineated with a well-defined radiolucent border.<sup>12</sup> The incidence of periapical cemento-osseous dysplasia is 2-3/1000 in the general population.<sup>13</sup> The radiographic appearance of periapical cemento-osseous dys-

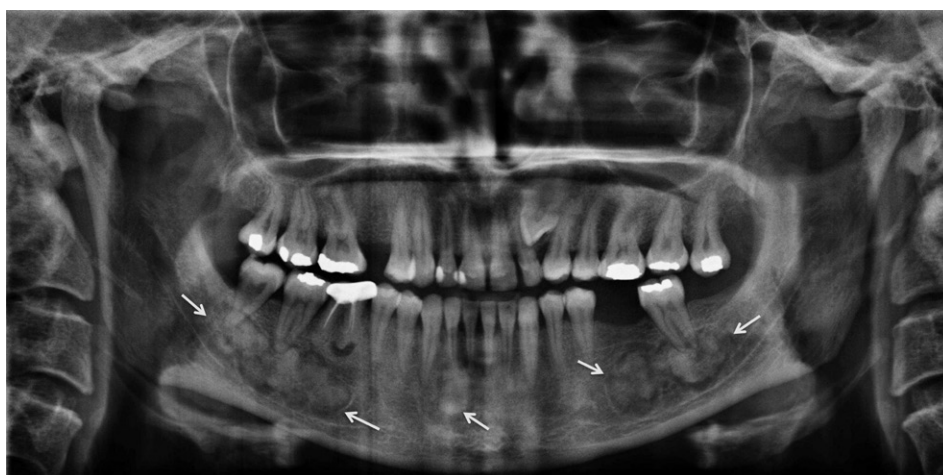plasia may vary widely. In the early stage, lesions show a periapical radiolucent defect that subsequently develops very small radiopacities. In the later stage, tiny radiopaque foci enlarge, coalesce, and undergo further substantial opacification. They consist of dense cementum-like and/or ground-glass areas rimmed by a radiolucent halo.<sup>7</sup> Eskandarloo and Yousefi<sup>12</sup> reported a case in which a radiolucent rim was found around the radiopaque lesion in the teeth apices (Fig. 1). The same finding was reported by Komabayashi and Zhu.<sup>14</sup>

#### Focal cemento-osseous dysplasia

Focal cemento-osseous dysplasia was first described by Summerlin and Tomich<sup>15</sup> based on the location of the involved bone (tooth-bearing areas of the posterior jaws and extraction sites). Although the etiology is unknown, some triggering factors such as trauma, caries, periodontal disease, infection, and systemic diseases have been identified. The periodontal ligament has been suggested as a probable origin for focal cemento-osseous dysplasia. Zegarelli et al.<sup>13</sup> suggested that hormonal imbalance may also be a causative factor. It causes no symptoms and is detected only on radiographic examination. The majority of focal cemento-osseous dysplasia lesions occur in the mandible. Almost one third of patients with focal cemento-osseous dysplasia present with local jaw expansion and mild discomfort.<sup>16</sup> This entity has three stages of maturation: early (a well-defined radiolucency at the apices of the mandibular teeth), intermediate (a radiolucent-opaque lesion with a well-defined radiolucent halo) and late (a radiopaque lesion, often with an ill-defined periphery).<sup>17</sup> Rao et al.<sup>18</sup> described focal cemento-osseous dysplasia as a small well-defined radiopacity surrounded by a uniform radiolucent halo (Fig. 2).



**Fig. 2.** Focal cemento-osseous dysplasia is seen at the periapex of the left mandibular first molar with a radiolucent rim (arrow) on a panoramic radiograph.

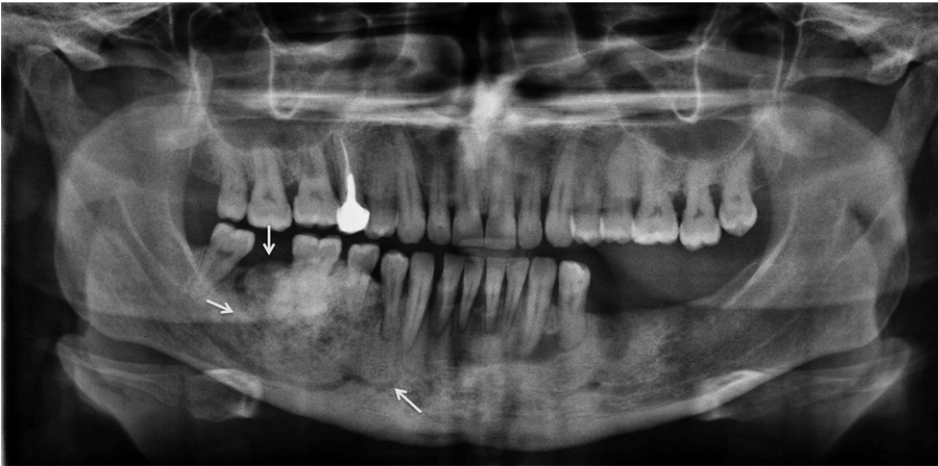


**Fig. 3.** Florid cemento-osseous dysplasia is situated at the right, left, and anterior portions of the mandible, surrounded by a radiolucent rim (arrows).

### Florid cemento-osseous dysplasia

Florid cemento-osseous dysplasia has also been described using the terms multiple cemento-ossifying fibroma, sclerosing osteomyelitis, multiple osteoma, sclerosing osteitis, periapical cementoblastoma, multiple enostosis, gigantiform cementoma, and florid osseous dysplasia.<sup>10,19</sup> The exact etiology of florid cemento-osseous dysplasia is still unknown. Most authorities have suggested that the pathogenesis of florid cemento-osseous dysplasia is related to the periodontal ligament, because most florid cemento-osseous dysplasias are seen close to the periodontal ligament with identical histopathologic features. However, a few authors have suggested that remnants of cementum in the bone after extraction might play a role in the etiology of this type of lesion.<sup>19</sup> Florid cemento-osseous dysplasia may be familial, with an autosomal dominant inheritance pattern, but few examples of a familial pattern have been reported in the literature.<sup>20</sup> It predominantly occurs in middle-aged to older black women, and the male-to-female

ratio has been reported as 1 : 2.6.<sup>19</sup> Florid cemento-osseous dysplasia most commonly appear as bilateral, symmetrical, and extensive lesions in all four posterior quadrants of the jaws, in the molar and premolar regions.<sup>10</sup> Florid cemento-osseous dysplasia has three types of radiographic appearance depending on its stage: the first or osteolytic stage (a well-defined radiolucent area with loss of lamina dura and periodontal ligament), the second or cementoblastic stage (small radiopacities appear in the radiolucent area due to the deposition of cementum-like droplets in fibrous tissue), and the last stage (lobular radiopacity throughout the lesion, surrounded by a radiolucent area).<sup>19</sup> Beylouni et al.<sup>10</sup> noticed cyst-like radiolucent areas around some radiopaque lesions in florid cemento-osseous dysplasia. Köse et al.<sup>19</sup> and Kutluay Köklü et al.<sup>20</sup> reported ovoid radiopaque masses in wide radiolucent spaces in the periapical areas of all molars in both quadrants of the mandible in the panoramic view (Fig. 3).



**Fig. 4.** A very large cemento-ossifying fibroma is located in the right aspect of the mandible with a radiolucent rim around the lesion (arrow).

### Cemento-ossifying fibroma

According to Wood and Goaz,<sup>4</sup> this entity has also been categorized as a fibro-osseous lesion of the jaw arising from the progenitor cells of periodontium, which are able to produce fibrous tissue, cementum, bone or a combination thereof.<sup>4,21</sup> This lesion has also been designated as central ossifying fibroma, cementifying fibroma, and ossifying fibroma.<sup>21,22</sup> The pathogenesis of cemento-ossifying fibroma is not clear, but trauma and congenital abnormalities in the maturation of dental tissue may play a key role in its development. It usually affects patients in their second to fourth decade of life, with a 1 : 5 male-to-female ratio. This lesion occurs much more frequently in the mandible (93%) than in the maxilla (7%), and it is most frequently seen in the molar region (61%), followed by the premolar (28%), and canine/incisor (11%) regions.<sup>21-23</sup> Clinically, it is a round, expansive, painless, slow-growing mass that may displace the roots of the adjacent teeth, sometimes causing root resorption.<sup>22</sup> Radiographically, early-stage lesions are small and radiolucent. As they mature, they become mixed radiolucent and radiopaque lesions, and eventually become radiopaque.<sup>21-23</sup> K et al.,<sup>21</sup> Chang et al.,<sup>22</sup> Trijolet et al.,<sup>23</sup> and Khan et al.<sup>24</sup> have reported that the presence of a radiolucent rim around a mixed or radiopaque cemento-ossifying fibroma is a characteristic feature of this entity (Fig. 4).

### Osteoid osteoma

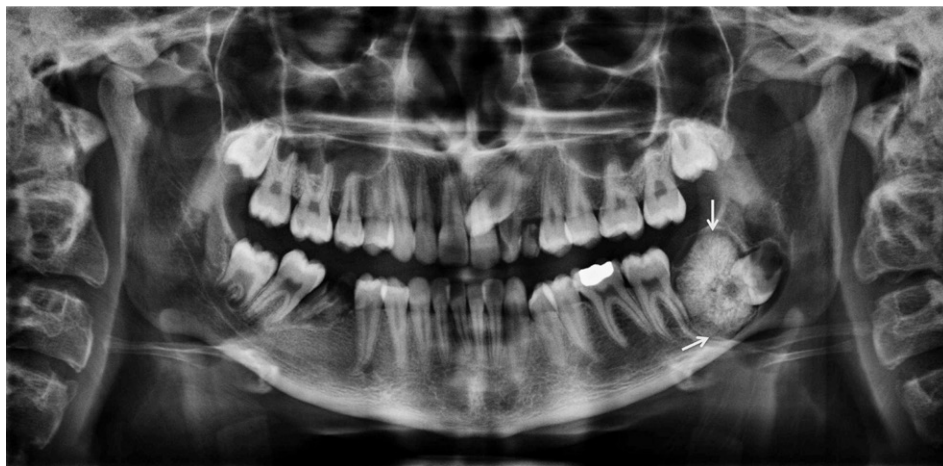Osteoid osteoma is a benign lesion that comprises 3% of all primary bone tumors and approximately 10% of bone tumors. Approximately 80% of lesions occur in the long bones, while less than 1% occur in the jaws; it is therefore a rare phenomenon in the orofacial region and might easily be misdiagnosed.<sup>25</sup> Osteoid osteoma is most frequently

observed in the second or third decades of life, and the average age at presentation is 19 years. It is more prevalent in females, with a male-to-female ratio of 1 : 2. Most patients present with nocturnal pain of the involved bone that is usually alleviated by non-steroidal anti-inflammatory drugs.<sup>26</sup>

An et al.<sup>26</sup> found that approximately 80% of cases had a mixed or high-density appearance. More than 50% of the cases were accompanied by surrounding sclerosis and 24 % presented with periosteal reaction. The presence of a radiolucent rim or border around mixed or radiopaque osteoid osteoma was reported by Ida et al.,<sup>25</sup> An et al.,<sup>26</sup> and Liu et al.<sup>27</sup>

### Osteoblastoma

Osteoblastoma is a benign and slow-growing bone neoplasm characterized by the formation of osteoid and bone with a great number of osteoblasts. This lesion comprises up to 1% of all primary bone tumors and 15% of maxillofacial lesions.<sup>28</sup> It has been found to occur in patients ranging in age from three to 78 years, with a mean age of 23 years. Patients between 20 and 30 are most commonly affected. Men are affected twice as frequently as women. Instances of mandibular involvement have been found to outnumber cases of maxillary involvement by 74% to 26%, and the mandibular body is most commonly affected.<sup>28,29</sup> The primary etiology of osteoblastoma is not clear, but trauma, inflammation, an abnormal local response of tissue to injury, and local alterations in bone physiology have been documented as possible causative factors.<sup>30</sup> The clinical features of osteoblastoma include mild pain, swelling, and expansion of the cortical bone. It is characterized by a limited growth pattern and does not exceed 4 cm in diameter.<sup>30</sup> The pain does not have a nocturnal



**Fig. 5.** A complex odontoma with a radiolucent rim in conjunction with a corticated border around the lesion (arrows).

pattern, and is not relieved by aspirin or other non-steroidal anti-inflammatory drugs, as is the case for osteoid osteoma.<sup>31</sup> A combination of radiopaque and radiolucent patterns, depending on the degree of calcification and the absence of a perilesional sclerotic border, is a common radiographic feature for osteoblastoma.<sup>30</sup> Jones et al.<sup>31</sup> found that more than half of the cases analyzed in their study had mixed or complete radiopaque patterns. Manjunatha et al.<sup>28</sup> reported similar findings.

The presence of a radiolucent rim or halo around mixed or radiopaque osteoblastomas has been noted by Manjunatha et al.,<sup>28</sup> Alvares Capelozza et al.,<sup>29</sup> Bokhari et al.,<sup>30</sup> Jones et al.,<sup>31</sup> Oztürk et al.,<sup>32</sup> and Shah et al.<sup>33</sup> in a range of case reports and systematic reviews.

### Odontoma

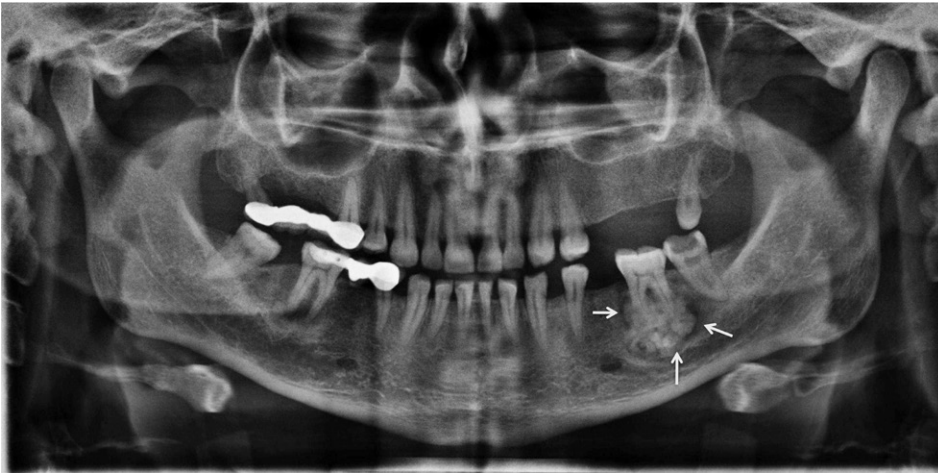Odontoma is the most frequent benign odontogenic tumor, and involves a combination of mesenchymal and epithelial dental elements. A variety of dental tissues, including enamel, dentin, cementum, and, in some cases, pulp tissue, can be found within the tumor. Two kinds of odontoma have been identified according to the latest classification of the World Health Organization (2005)<sup>6</sup>: complex odontoma and compound odontoma, which is twice as common as the complex type. Odontoma manifests in three clinical forms: central (intra-osseous), peripheral (extra-osseous or soft-tissue), and erupted odontoma.<sup>34</sup> The site that is most commonly affected by compound odontoma is the anterior portion of the maxilla, where it appears as a pericoronal lesion around unerupted teeth or as an inter-radicular lesion. Odontoma is usually unilocular and contains several radiopaque, small denticles (tooth-like structures).<sup>34</sup> Complex odontoma grows slowly and non-aggressively, and is slightly more com-

mon in the mandible, especially in the second and third molar areas.<sup>34,35</sup> The etiology of odontoma is unknown, but some researchers have suggested that trauma, infection, or genetic mutations may be causative factors.<sup>36</sup> Odontomas are usually slow-growing and nonaggressive, and occur most frequently in children and adolescents.<sup>37</sup> Odontoma does not have a marked gender predilection. Clinically, odontomas are asymptomatic lesions that are often associated with altered tooth eruption in the permanent or deciduous dentition. They are usually diagnosed based on routine panoramic and/or intraoral X-rays, or by assessing the cause of delayed tooth eruption. It is believed that 37%-78% of all eruption disorders in the dentition are caused by odontomas.<sup>37</sup> Occasionally, odontomas are discovered due to the presence of retained deciduous teeth, eruption problems, pain, swelling, infection or inflammation, or dental malposition.<sup>35-37</sup>

Radiographically, compound odontomas present as well-delineated lesions containing radiodense foci with a radiolucent halo. Several follicular structures contain denticles, which are separated by fibrous septae. However, in complex odontomas, opaque foci present as haphazard masses with no similarity to dental structures.<sup>38</sup> The presence of a radiolucent rim on the border of odontoma has been noted by Piattelli et al.,<sup>35</sup> Reddy et al.,<sup>36</sup> Hidalgo-Sánchez et al.,<sup>38</sup> Philipsen et al.,<sup>39</sup> and Garcia-Consuegral et al.<sup>40</sup> (Fig. 5).

### Cementoblastoma

Cementoblastoma constitutes less than 6% of all odontogenic tumors. According to current World Health Organization classification of odontogenic tumors, it is classified as an ectomesenchymal tumor with or without odontogenic epithelium.<sup>41</sup> Cementifying fibroma and cementoblastoma are considered to be true neoplasms of cemental



**Fig. 6.** Cementoblastoma is seen at the periapex of the left second mandibular molar. A radiolucent halo is apparent at the periphery of the lesion (arrows).

origin.<sup>41-43</sup> Cementoblastoma originates from the roots of teeth, and is marked by the formation of cementum-like tissue.<sup>44,45</sup> Clinically, the lesion appears as a nodular expansive mass in the alveolar ridge area that is hard to elastic in consistency.<sup>45</sup> The tumors have been reported to range in size from 0.5 cm to 5.5 cm, with a mean diameter of 2.1 cm.<sup>46</sup> Cementoblastoma is usually asymptomatic and is generally detected upon radiographic examination.<sup>42,43</sup> Symptoms may be completely absent, but if present, pain, swelling, and cortical expansion are frequent findings.<sup>42,47,48</sup> Paresthesia of the lower lip or pathologic fracture of the jaws rarely occurs.<sup>42-48</sup> It can also act in a locally aggressive manner, resulting in bony expansion, root resorption, displacement of adjacent teeth, and jaw deformity. Jaw expansion and perforation of the cortex are common findings in recurrent tumors.<sup>42</sup> Most benign cementoblastomas occur in the mandible.<sup>47,49</sup> The mandible is affected three times as often as the maxilla. The most commonly affected tooth is the mandibular first molar, which remains vital.<sup>47,48</sup> Benign cementoblastoma has also been reported in the maxillary sinus, and is accompanied by deciduous and unerupted permanent teeth.<sup>41,43,45</sup> Caucasians are more commonly affected than blacks. The male-to-female ratio of its prevalence is 2.1 : 1. Young adults in their second and third decades of life are most commonly affected.<sup>41-48</sup>

Radiographically, cementoblastoma presents as a well-defined radiopaque mass surrounded by a thin, radiolucent rim of non-mineralized tissue, in close association with roots of the involved tooth (Fig. 6). Root resorption, loss of usual outline, and obliteration of the periodontal ligament are common radiographic features.<sup>50,51</sup> Attachment of the lesion to the roots of the involved tooth is nearly pathognomonic. Additional radiographic findings consist of invasion of the root canal, bony expansion, displacement

and involvement of adjacent teeth, and cortical erosion.<sup>29</sup> A radiolucent rim at the periphery of cementoblastoma has been pointed out by Sharma,<sup>41</sup> Sankari and Ramakrishnan,<sup>42</sup> Kumar et al.,<sup>43</sup> Iannaci et al.,<sup>45</sup> Huber and Folk,<sup>47</sup> Bilodeau et al.,<sup>48</sup> Harada et al.,<sup>49</sup> Pacifici et al.,<sup>50</sup> and Monks et al.<sup>51</sup>

## Discussion

We propose the novel subcategory of jaw lesions with a radiolucent rim, which has the advantage of helping clinicians to rule out improbable diagnoses and arrive at the correct diagnosis timely and in a logical manner. This subcategory consists of eight entities: periapical cemento-osseous dysplasia, focal cemento-osseous dysplasia, florid cemento-osseous dysplasia, cemento-ossifying fibroma, osteoid osteoma, osteoblastoma, odontoma, and cementoblastoma.

Of particular note is the pattern of female predominance in all of the above lesions except for cementoblastoma. With respect to location, only compound odontoma has a tendency to occur in the maxilla, and the remaining lesions are most commonly encountered in the mandible. However, florid cemento-osseous dysplasia can involve both jaws simultaneously. Moreover, with the exception of compound odontoma and periapical cemento-osseous dysplasia, the posterior mandible is the most common site of involvement. Osteoid osteoma and osteoblastoma have been reported to cause pain, while the other six jaw lesions in this category remain asymptomatic until they are noticed due to cortical expansion or during a routine examination. Most jaw lesions with a radiolucent rim manifest as periapical lesions with or without association with the teeth, but odontomas occur as pericoronal lesions. How-

ever, the ability to expand the cortical plates varies among these lesions; some entities, such as periapical cemento-osseous dysplasia, remain less than 1 cm in diameter with no expansion, while cemento-ossifying fibroma and cementoblastoma are capable of expanding the jaw bone considerably.<sup>4,10,12,16,17,19,22,26,28,29,34,45</sup>

This newly-proposed category of jaw lesions allows practitioners to narrow the differential diagnosis and arrive at the most probable diagnosis via a systematic method.

### Acknowledgements

The authors are especially thankful to Dr. Seyed Hosein Hoseini Zarch and Dr. Hamed Kermani for providing figures.

### References

- Neyaz Z, Gadodia A, Gamanagatti S, Mukhopadhyay S. Radiographical approach to jaw lesions. *Singapore Med J* 2008; 49: 165-77.
- George G, Padiyath S. Unicystic jaw lesions: a radiographic guideline. *J Indian Acad Oral Med Radiol* 2010; 22: S31-6.
- Curé JK, Vattoth S, Shah R. Radiopaque jaw lesions: an approach to the differential diagnosis. *Radiographics* 2012; 32: 1909-25.
- Wood NK, Goaz PW. Differential diagnosis of oral and maxillofacial lesions. 5th ed. St Louis: Mosby-Year Book Inc.; 1997. p.415-48.
- Sanjai K, Kumarswamy J, Kumar VK, Patil A. Florid cemento osseous dysplasia in association with dentigerous cyst. *J Oral Maxillofac Pathol* 2010; 14: 63-8.
- Barnes L, Eveson JW, Reichart P, Sidransky D. Pathology and genetics of head and neck tumours. World Health Organization Classification of Tumours. Lyon: IARC Press; 2005.
- Alsufyani NA, Lam EW. Osseous (cement-osseous) dysplasia of the jaws: clinical and radiographic analysis. *J Can Dent Assoc* 2011; 77: b70.
- Kawai T, Hiranuma H, Kishino M, Jikko A, Sakuda M. Cemento-osseous dysplasia of the jaws in 54 Japanese patients: a radiographic study. *Oral Surg Oral Med Oral Pathol Oral Radiol Endod* 1999; 87: 107-14.
- Alsufyani NA, Lam EW. Cemento-osseous dysplasia of the jaw bones: key radiographic features. *Dentomaxillofac Radiol* 2011; 40: 141-6.
- Beylouni I, Farge P, Mazoyer JF, Coudert JL. Florid cemento-osseous dysplasia: report of a case documented with computed tomography and 3D imaging. *Oral Surg Oral Med Oral Pathol Oral Radiol Endod* 1998; 85: 707-11.
- Brannon RB, Fowler CB. Benign fibro-osseous lesions: a review of current concepts. *Adv Anat Pathol* 2001; 8: 126-43.
- Eskandarloo A, Yousefi F. CBCT findings of periapical cemento-osseous dysplasia: a case report. *Imaging Sci Dent* 2013; 43: 215-8.
- Zegarelli E, Kutscher A, Napoli N, Iurono F, Hoffman P. The cementoma. A study of 230 patients with 435 cementomas. *Oral Surg Oral Med Oral Pathol* 1964; 17: 219-24.
- Komabayashi T, Zhu Q. Cemento-osseous dysplasia in an elderly Asian male: a case report. *J Oral Sci* 2011; 53:117-20.
- Summerlin DJ, Tomich CE. Focal cemento-osseous dysplasia: a clinicopathologic study of 221 cases. *Oral Surg Oral Med Oral Pathol* 1994; 78: 611-20.
- Bhandari R, Sandhu SV, Bansal H, Behl R, Bhullar RK. Focal cemento-osseous dysplasia masquerading as a residual cyst. *Contemp Clin Dent* 2012; 3(Suppl 1): S60-2.
- Eversole R, Su L, ElMofty S. Benign fibro-osseous lesions of the craniofacial complex. A review. *Head Neck Pathol* 2008; 2: 177-202.
- Rao GS, Kamalapur MG, Acharya S. Focal cemento-osseous dysplasia masquerading as benign cementoblastoma: a diagnostic dilemma. *J Oral Maxillofac Pathol* 2014; 18: 150.
- Köse TE, Köse OD, Karabas HC, Erdem TL, Ozcan I. Findings of florid cemento-osseous dysplasia: a report of three cases. *J Oral Maxillofac Res* 2014; 4: e4.
- Kutluay Köklü H, Cankal DA, Bozkaya S, Ergün G, Bar E. Florid cemento-osseous dysplasia: report of a case documented with clinical, radiographic, biochemical and histological findings. *J Clin Exp Dent* 2013; 5: e58-61.
- K L K, R S AB, P S, Kumaran S. Pericoronal occurrence of cemento-ossifying fibroma: an unexemplified and unusual case report with review of literature. *J Clin Diagn Res* 2014; 8: 277-9.
- Chang CC, Hung HY, Chang JY, Yu CH, Wang YP, Liu BY, et al. Central ossifying fibroma: a clinicopathologic study of 28 cases. *J Formos Med Assoc* 2008; 107: 288-94.
- Trijolet JP, Parmentier J, Sury F, Goga D, Mejean N, Laure B. Cemento-ossifying fibroma of the mandible. *Eur Ann Otorhinolaryngol Head Neck Dis* 2011; 128: 30-3.
- Khan SA, Sharma NK, Raj V, Sethi T. Ossifying fibroma of maxilla in a male child: report of a case and review of the literature. *Natl J Maxillofac Surg* 2011; 2: 73-9.
- Ida M, Kurabayashi T, Takahashi Y, Takagi M, Sasaki T. Osteoid osteoma in the mandible. *Dentomaxillofac Radiol* 2002; 31: 385-7.
- An SY, Shin HI, Choi KS, Park JW, Kim YG, Benavides E, et al. Unusual osteoid osteoma of the mandible: report of case and review of the literature. *Oral Surg Oral Med Oral Pathol Oral Radiol* 2013; 116: e134-40.
- Liu CJ, Chang KW, Chang KM, Cheng CY. A variant of osteoid osteoma of the mandible: report of a case. *J Oral Maxillofac Surg* 2002; 60: 219-21.
- Manjunatha BS, Sunit P, Amit M, Sanjiv S. Osteoblastoma of the jaws: report of a case and review of literature. *Clin Pract* 2011; 1: e118.
- Alvares Capelozza AL, Gião Dezotti MS, Casati Alvares L, Negrão Fleury R, Sant'Ana E. Osteoblastoma of the mandible: systematic review of the literature and report of a case. *Dentomaxillofac Radiol* 2005; 34: 1-8.
- Bokhari K, Hameed MS, Ajmal M, Togoo RA. Benign osteoblastoma involving maxilla: a case report and review of the literature. *Case Rep Dent* 2012; 2012: 351241.
- Jones AC, Prihoda TJ, Kacher JE, Odingo NA, Freedman PD. Osteoblastoma of the maxilla and mandible: a report of 24



- cases, review of the literature, and discussion of its relationship to osteoid osteoma of the jaws. *Oral Surg Oral Med Oral Pathol Oral Radiol Endod* 2006; 102: 639-50.
32. Oztürk M, Ozeç I, Aker H, Müslehiddinoğlu A. Osteoblastoma of the mandible with root resorption: a case report. *Quintessence Int* 2003; 34: 135-8.
  33. Shah S, Kim JE, Huh KH, Yi WJ, Heo MS, Lee SS. Recurrent osteoblastoma of the maxilla. *Dentomaxillofac Radiol* 2013; 42: 20100263.
  34. Junquera L, de Vicente JC, Roig P, Olay S, Rodríguez-Recio O. Intraosseous odontoma erupted into the oral cavity: an unusual pathology. *Med Oral Patol Oral Cir Bucal* 2005; 10: 248-51.
  35. Piattelli A, Perfetti G, Carraro A. Complex odontoma as a periapical and interradicular radiopacity in a primary molar. *J Endod* 1996; 22: 561-3.
  36. Reddy GS, Reddy GV, Sidhartha B, Sriharsha K, Koshy J, Sultana R. Large complex odontoma of mandible in a young boy: a rare and unusual case report. *Case Rep Dent* 2014; 2014: 854986.
  37. Ohtawa Y, Ichinohe S, Kimura E, Hashimoto S. Erupted complex odontoma delayed eruption of permanent molar. *Bull Tokyo Dent Coll* 2013; 54: 251-7.
  38. Hidalgo-Sánchez O, Leco-Berrocal MI, Martínez-González JM. Metaanalysis of the epidemiology and clinical manifestations of odontomas. *Med Oral Patol Oral Cir Bucal* 2008; 13: E730-4.
  39. Philipsen HP, Reichart PA, Praetorius F. Mixed odontogenic tumours and odontomas. Considerations on interrelationship. Review of the literature and presentation of 134 new cases of odontomas. *Oral Oncol* 1997; 33: 86-99.
  40. Garcia-Consuegra L, Junquera LM, Albertos JM, Rodriguez. Odontomas. A clinical-histological and retrospective epidemiological study of 46 cases. *Med Oral* 2000; 5: 367-72.
  41. Sharma N. Benign cementoblastoma: a rare case report with review of literature. *Contemp Clin Dent* 2014; 5: 92-4
  42. Sankari LS, Ramakrishnan K. Benign cementoblastoma. *J Oral Maxillofac Pathol* 2011; 15: 358-60.
  43. Kumar S, Prabhakar V, Angra R. Infected cementoblastoma. *Natl J Maxillofac Surg* 2011; 2: 200-3.
  44. Gulsels A, Bayar GR, Aydin C, Sencimen M. A case of a benign cementoblastoma treated by enucleation and apicoectomy. *Gen Dent* 2012; 60: e380-2.
  45. Iannaci G, Luise R, Iezzi G, Piattelli A, Salierno A. Multiple cementoblastoma: a rare case report. *Case Rep Dent* 2013; 2013: 828373.
  46. Brannon RB, Fowler CB, Carpenter WM, Corio RL. Cementoblastoma: an innocuous neoplasm? A clinicopathologic study of 44 cases and review of the literature with special emphasis on recurrence. *Oral Surg Oral Med Oral Pathol Oral Radiol Endod* 2002; 93: 311-20.
  47. Huber AR, Folk GS. Cementoblastoma. *Head Neck Pathol* 2009; 3: 133-5.
  48. Bilodeau E, Collins B, Costello B, Potluri A. Case report: a pediatric case of cementoblastoma with histologic and radiographic features of an osteoblastoma and osteosarcoma. *Head Neck Pathol* 2010; 4: 324-8.
  49. Harada H, Omura K, Mogi S, Okada N. Cementoblastoma arising in the maxilla of an 8-year-old boy: a case report. *Int J Dent* 2011; 2011: 384578.
  50. Pacifici L, Tallarico M, Bartoli A, Ripari A, Cicconetti A. Benign cementoblastoma: a clinical case of conservative surgical treatment of the involved tooth. *Minerva Stomatol* 2004; 53: 685-91.
  51. Monks FT, Bradley JC, Turner EP. Central osteoblastoma or cementoblastoma? A case report and 12 year review. *Br J Oral Surg* 1981; 19: 29-37.