

Neuropathic Arthropathy of the Shoulder Associated with Cervical Syringomyelia: A Case Report

Jaehyun Park, Taekang Im, Jinsun Moon¹, Yongbeom Lee^{2✉}

Department of Orthopedic Surgery, Eulji General Hospital, Seoul, ¹Department of Orthopedic Surgery, Gwangmyeong Saewoom Hospital, Gwangmyeong, ²Department of Orthopedic Surgery, Hallym University Sacred Heart Hospital, Anyang, Korea

Neuropathic shoulder arthropathy or Charcot's shoulder is an extremely rare disease, and sometimes it is associated with cervical syringomyelia. Clinical symptoms of the disease include edema of the shoulder and restriction in range of motion. Radiological diagnosis can be made through plain radiography through a characteristic, atrophic destruction of the joint. We experienced a Charcot's joint of the shoulder wherein destruction of the joint progressed extremely quickly and reviewed the literature concerning this condition.

(*Clin Shoulder Elbow* 2015;18(4):261-265)

Key Words: Shoulder; Neurogenic arthropathy; Cervical syringomyelia

Charcot's joint is an extremely uncommon disease, and it is infrequently associated with cervical syringomyelia. A quarter of patients with cervical syringomyelia have been shown to have concomitant neuropathic arthropathy, 5% to 6% of which occur in the shoulder.¹⁾ The number of reported cases of this disease is very few and those existing are cited in the international literature; the Korean literature has yet to report of a case. The clinical symptoms of the disease include restriction in shoulder range of motion (ROM) and cellulitis associated with hypoesthesia or with edema. The authors encountered a patient whose Charcot's joint of a shoulder and joint destruction proceeded at an extremely fast pace. We report this case along with a review of the literature concerning this disease.

Case Report

A male patient aged 44 years had suffered from restriction in ROM and severe swelling a week previous to his admission to hospital. The patient has a history of a 4th thoracic vertebral fracture 20 years ago for which he received conservative management and a history of syringomyelia 11 years ago. For the treatment syringomyelia the patient had received, at a different

hospital, surgical treatment. The postoperative hypoesthesia of the bilateral upper limbs and paralysis of the lower body he sustained permanently meant that the patient has had to live with the aid of a wheelchair.

The patient had a medical history of a suspected cellulitis of the same shoulder 4 months previous to the current visit, for which the patient had been given oral antibiotics. The patient's symptoms improved with medication. Four months later, the patient complained of mild pain around the shoulders. With physical examination, we found that the right shoulder presented with severe swelling and focal flaring, causing us to suspect septic arthritis. The active shoulder ROMs of the patient were an anterior flexion of 90°, external rotation of 80°, and an internal rotation to the 3rd lumbar spine, and the passive shoulder ROMs were an anterior flexion of 140°, external rotation of 90°, and an internal rotation to the 1st lumbar spine. The results of blood tests taken at the time of admission were higher than normal: a white blood cell count of 9,100 cells/cm², an erythrocyte sedimentation rate of 67 mm/h, and a C-reactive protein level of 20.2 mg/d. In addition, the plain radiography of the right shoulder showed osteopenia of the humeral head, destructive changes of the glenohumeral joint, and intra- and extra-articular detachment of

Received November 24, 2015. **Revised** December 3, 2015. **Accepted** December 4, 2015.

✉ **Correspondence to:** Yongbeom Lee

Department of Orthopedic Surgery, Hallym University Sacred Heart Hospital, 22 Gwanpyeong-ro 170beon-gil, Dongan-gu, Anyang 14068, Korea
Tel: +82-31-380-3770, **Fax:** +82-31-380-4118, **E-mail:** drleeyb@naver.com

Financial support: None. **Conflict of interests:** None.

fracture fragments. But, intriguingly, a plain radiography of the same arm taken 4 months before showed no such signs of joint destruction (Fig. 1). Results of magnetic resonance imaging (MRI) confirmed those of plain radiographs, on a T2-weighted image we found osteopenia of the right humeral head, destruction of the glenohumeral joint, synovial hypertrophy, decreased flow of synovial fluid in the surrounding soft tissue, intra and extra-articular detachment of fracture fragments that were associated with rotator cuff tears (Fig. 2). Altogether, the symptoms such

as the increased inflammatory markers at the time of hospitalization were suggestive of infection. Radiography showed that within just 4 months a destruction of the joint had progressed at an alarming pace; we suspected that this was either septic arthritis or tubercular arthritis and had carried out an arthroscopic debridement to treat it (Fig. 3).

Arthroscopically, we found evidence of severe synovitis but not exudation. When we tested the patient using bacterial culture test and an Acid-Fast Bacilli smear test, the results of both

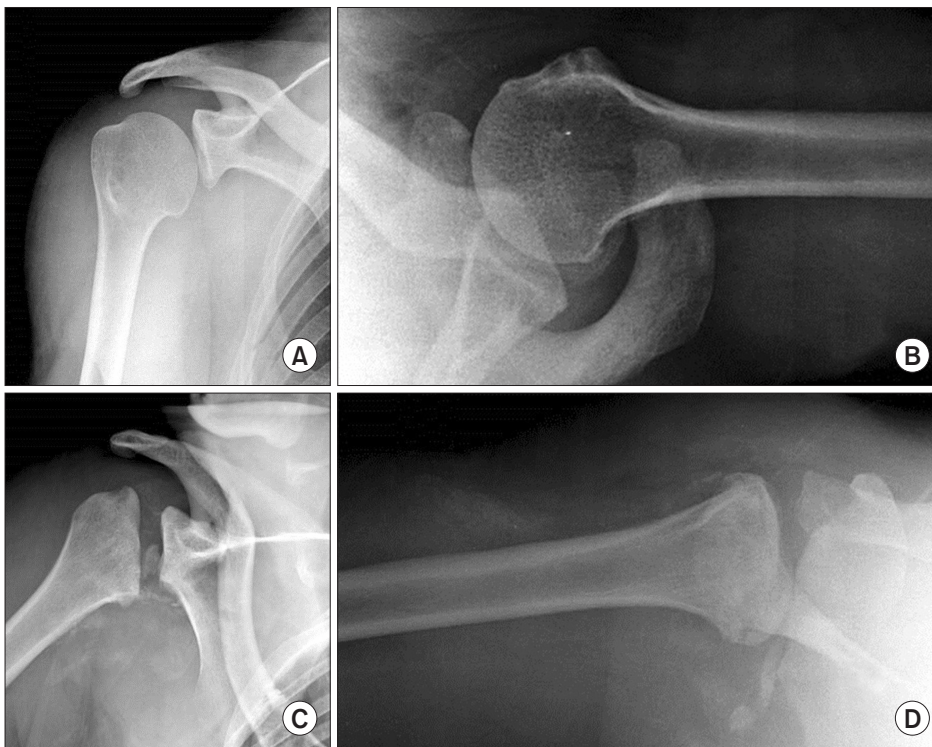


Fig. 1. (A, B) Radiographs of the right shoulder anteroposterior (AP) and axial view showing no abnormal finding. (C, D) Radiographs of the right shoulder AP and axial view showing destruction of the head of the humerus giving rise to its blunted amputated appearance and increased joint space. The proximal right humerus and glenoid cavity are sclerosed and the proximal humerus is subluxated superiorly. Loose intra-articular bony fragments and para-articular debris are seen in the soft tissues around the right shoulder joint.

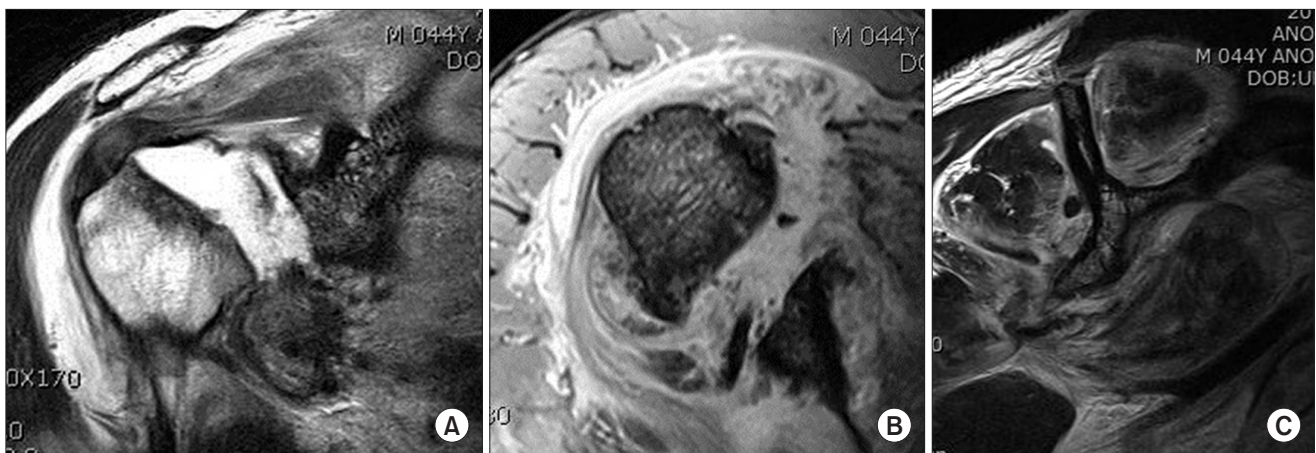


Fig. 2. Magnetic resonance imaging showed destruction of the head of the humerus. (A) A large quantity of fluid collection was seen in and around the right shoulder joint. Bony fragments and para-articular debris were seen within the fluid collection. And also synovial thickening was seen. Tear and atrophy of muscles around the shoulder joint, namely the supraspinatus, infraspinatus, and subscapularis muscles were seen. (B) Glenoid cavity was shallow and showed destructive changes. (C) Sagittal oblique image shows diffuse muscle edema of the supraspinatus, infraspinatus and subscapularis.

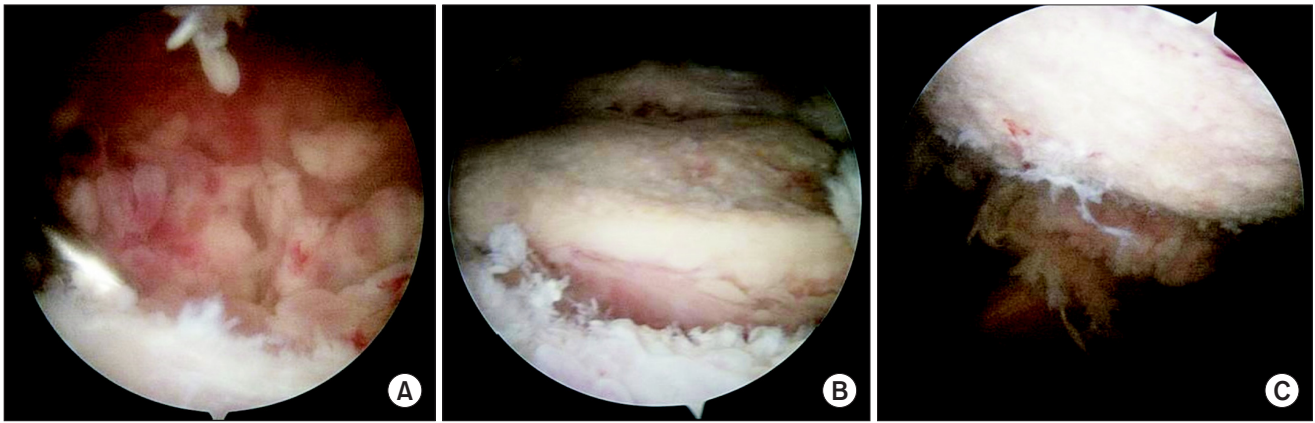


Fig. 3. (A-C) Arthroscopic exploration shows severe synovitis. And (B) shows shallow destruction and cartilage injuries of proximal humeral head and glenoid.

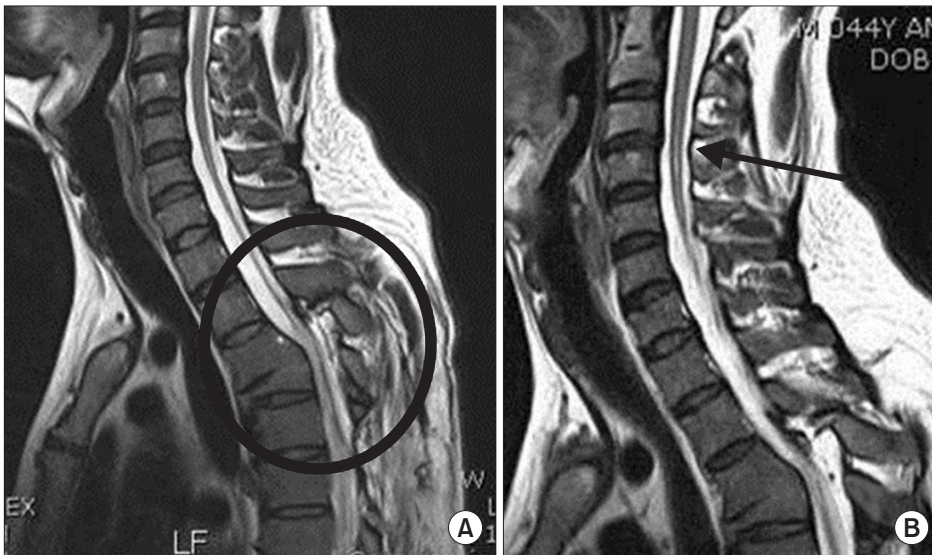

Fig. 4. (A) Magnetic resonance imaging of cervical spine shows old fracture deformity of T4 and spinal stenosis between T3 and T4 (circle). (B) And shows syrinx extending from C3 to C5 (arrow).

were negative. Accordingly, the operative and the bacterial test results did not match the preoperative diagnosis of septic or tubercular infection. We subsequently questioned the patient and took a medical history of the patient and found that the patient had a history of cervical syringomyelia and that the destructive changes of the shoulder bone were brought about in a very short space of time, such findings prompted us to suspect a Charcot's joint of the right shoulder secondary to cervical syringomyelia and to take diagnostic cervical MRI.

We found the syrinx situated between the 2nd to the 5th cervical vertebra (Fig. 4) on T2-weighted images using cervical MRI. Although the patient presented with bilateral hypoesthesia of the arms and reduced shoulder ROM, because symptoms such as edema were improved we surveyed the patient postoperatively rather than taking surgical actions for these symptoms. But at the 4th postoperative month and at the 2-year follow-up, rather than more improvement, we found that the symptoms had deteriorated further; the extent of humeral head destruction, proxi-

mal to the neck, was greater and bone resorption was more progressed by this time (Fig. 5). At the 2-year follow-up, we found that the active ROMs of the patient were anterior flexion of 60°, external rotation of 60°, and internal rotation to the 5th lumbar spine and the passive ROM were anterior flexion of 140°, external rotation of 80°, and internal rotation to the 3rd lumbar spine. Shoulder instability was so severe that during wheelchair use the patient could not bear weight on his shoulders.

Discussion

Charcot's joint is associated with a decrease in sensory innervations, a common phenomenon in chronic degenerative arthropathies. Two theories have been proposed that explain the etiological origin of neuropathic arthropathy: the neurovascular theory and the neurotrauma theory. The neurovascular theory states that injury to the automatic nerve leads to a disregulated neurovascular reflex surrounding the joint. The resulting failure

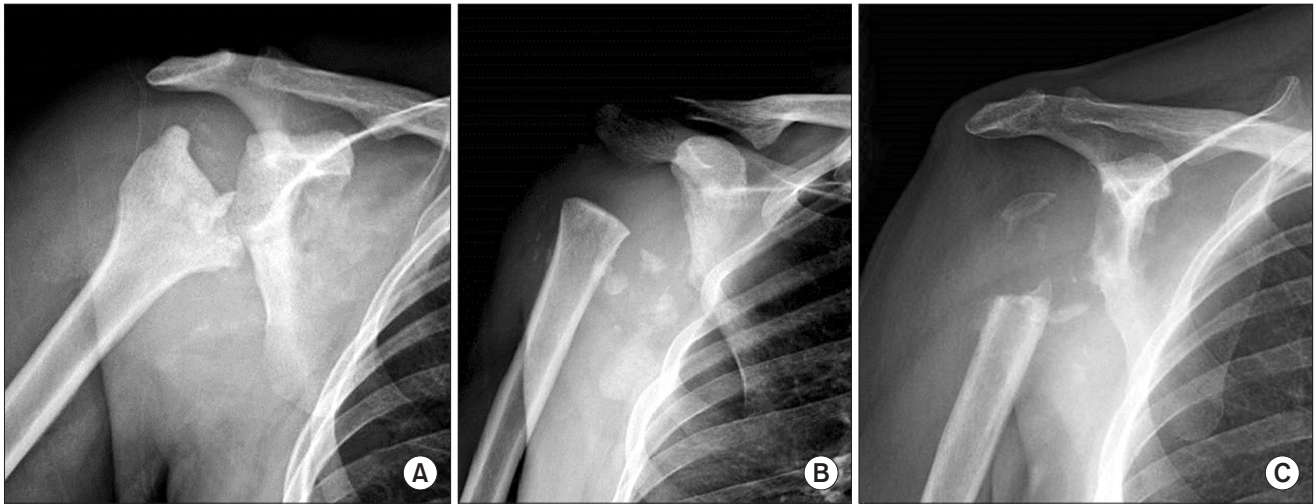


Fig. 5. (A) Preoperative radiograph of the right shoulder anteroposterior (AP) view showing destruction of the head of the humerus giving rise to its blunted amputated appearance and increased joint space. (B) Radiograph of the right shoulder AP view, 4 months after operation, showing complete destruction and bone resorption of humeral head. And also remnant humeral shaft is migrated superiorly. (C) Radiograph of the right shoulder AP view, 2 years after operation, showing progression of resorption of remnant bone.

in vasoregulation cause hyperemia, neovascularization, and activation of osteoclasts that in turn increase bone resorption, osteopenia, and joint destruction.²⁾ Whereas the neurotrauma theory states that the loss in the somatic muscle reflex protective of joints leads to accumulation injury from repetitive trauma and thereby joint destruction.³⁾ Of the many pathophysiological roots, diabetes, syphilis, and cervical syringomyelia are the 3 main causes of neuropathic arthropathy. Neuropathic arthropathy occurs mostly in the ankles in diabetic patients and in the knees in syphilis patients. It is known to occur mostly in the shoulder and the elbows in patients with cervical syringomyelia.⁴⁾ Neuropathic arthropathy in the shoulder is rare and is associated with destruction of the proximal humerus and of the glenoid and with inflammation of the joints.⁵⁾ The pathogenesis of neuropathic arthropathy secondary to cervical syringomyelia has not been clearly defined but it is thought that an expanded syrinx blocks the lateral spinothalamic tract, the posterior column fibrotic cells, the anterior horn of the spinal cord, and the sympathetic tract, which is the condition under which neuropathic arthropathy can be induced by repetitive trauma and by loss of nociception and of thermoception.⁶⁾

A standard treatment for neuropathic arthropathy has consisted of conservative measures such as the use of non-weight bearing brace for the immobilization of joints. A study by Hatzis et al.⁷⁾ have suggested that with regards to the treatment of neuropathic shoulder arthropathy maintaining shoulder joint function takes precedence over fixation through arthrodesis. In line with this, Matsushashi et al.⁸⁾ proposed that a favorable treatment of neuropathic arthropathy secondary to cervical syringomyelia is to surgically decompress the syrinx and to repair rotator cuff through hemiarthroplasty; 3 patients who received a rotator cuff

repair and a shoulder hemiarthroplasty showed good shoulder function and a preserved component at the 10-year follow-up. But this mode of treatment is restricted to patients without paralysis and without sepsis, with an early stage of the disease, and in whom the greater tuberosity of the humerus is well preserved.

In the case that was described in this report, we found that the clinical indicators of infection such as edema and flaring improved after treatment. We had planned to address the secondary shoulder hemiarthroplasty when infection parameters, indicated through blood tests, normalized at the postoperative follow-ups, but during the follow-up we noticed that joint destruction had already occurred at a very fast pace. Therefore, in patients who have had a history of cervical syringomyelia and of symptoms of edema or dysfunction of the shoulder, as in the patient we described, these precursory condition may have been a clinical indicator of neuropathic arthropathy secondary to cervical syringomyelia. With this possibility in mind, the patient should have been follow-uped appropriately. If cervical syringomyelia is suspected at an early stage of disease, a cervical MRI can be taken to see whether the syrinx shows signs of weakening and whether it could be a surgically decompressed. If as in our case a lower body paralysis necessitates wheelchair dependency, an electric wheelchair should be recommended to lessen unnecessary weight bearing on shoulder joints as much as possible. When humeral head destruction is not severe, Matsushashi et al.⁹⁾ suggested that a rotator cuff repair and shoulder hemiarthroplasty be performed.

Charcot's joint of the shoulder associated with cervical syringomyelia is an extremely rare condition. When they occur, destruction of the joints culminates within months. For it has a debilitating outcome neuropathic arthropathy should be sus-

pected and examined for even in patients with swelling of the shoulder or suboptimal shoulder function with non-severe pain through plain radiography and through medical history taking. Radiographs should be used to differentiate diseases that also present with acute joint destruction such as avascular necrosis, dialysis arthropathy, rheumatoid arthritis, septic arthritis, and Milwaukee syndrome.^{9,10} With diagnosis of a Charcot's shoulder, it is important to prevent exacerbation of joint injury caused by repetitive trauma by application of an immobilization brace but at the same time to maintain functional shoulder ROM.

References

1. Floyd W, Lovell W, King RE. The neuropathic joint. *South Med J.* 1959;52(5):563-9.
2. Johnson JT. Neuropathic fractures and joint injuries. Pathogenesis and rationale of prevention and treatment. *J Bone Joint Surg Am.* 1967;49(1):1-30.
3. Allman RM, Brower AC, Kotlyarov EB. Neuropathic bone and joint disease. *Radiol Clin North Am.* 1988;26(6):1373-81.
4. Jones J, Wolf S. Neuropathic shoulder arthropathy (Charcot joint) associated with syringomyelia. *Neurology.* 1998;50(3):825-7.
5. Rawat B, Bell RS. Case report: rapidly progressive neuropathic arthropathy in syringohydromyelia: radiographic and magnetic resonance imaging findings. *Clin Radiol.* 1994;49(7):504-7.
6. Yanik B, Tuncer S, Seçkin B. Neuropathic arthropathy caused by Arnold-Chiari malformation with syringomyelia. *Rheumatol Int.* 2004;24(4):238-41.
7. Hatzis N, Kaar TK, Wirth MA, Toro F, Rockwood CA Jr. Neuropathic arthropathy of the shoulder. *J Bone Joint Surg Am.* 1998;80(9):1314-9.
8. Matsushashi T, Nagahama K, Suenaga N, Oizumi N, Minami A. Midterm outcomes after humeral head replacement with rotator cuff repair in patients with syringomyelia shoulder neuroarthropathy: a report on three cases. *J Shoulder Elbow Surg.* 2011;20(8):e8-15.
9. Nguyen VD. Rapid destructive arthritis of the shoulder. *Skeletal Radiol.* 1996;25(2):107-12.
10. Epis O, Viola E, Bruschi E, Benazzo F, Montecucco C. Milwaukee shoulder syndrome (apatite associated destructive arthritis): therapeutic aspects. *Reumatismo.* 2005;57(2):69-77.