

The Exception Case about the Diagnose Forward Head Posture using the CranioVertebra Angle, CranioRotation Angle and Cobb angle : a Case Report

Han-Kyu Park, PT, MS · Sang-Yeol Lee, PT, PhD^{1†} · Tae-Ho Kim, PT, PhD²

Department of Rehabilitation Science, Graduate School, Daegu University

¹Department of Physical Therapy, College of Health Science, Kyung Sung University

²Department of Physical Therapy, College of Rehabilitation Sciences, Daegu University

Received: February 24, 2015 / Revised: February 28, 2015 / Accepted: April 2, 2015

© 2015 J Korean Soc Phys Med

| Abstract |

PURPOSE: The purpose of present study was to introduces an exceptional case in measurement methods (CVA, CRA and Cobb angle) to identify the FHP with verified reliability and validity. Subjects: Three males aged 30 years were recruited: A Normal, B and C who have FHP.

METHODS: All the subjects were measured CVA, CRA and Cobb angle with the Photogrammetry and Radiography.

RESULTS: The results revealed that it is not enough for measurement methods to identify the FHP using CVA, CRA and Cobb angle. On Photogrammetry values; CVA had 65°, CRA was 148° of Normal subject A and CVA had 61°, CRA was 149° of FHP subject B and CVA had 51°, CRA was 149° of FHP subject C. On Radiography values; CVA had 73°, CRA was 148° and Cobb was 50° of Normal subject A and CVA had 70°, CRA was 150° and Cobb was 53° of FHP subject B and CVA had 61°, CRA was 153° and Cobb was 31° of FHP subject C.

CONCLUSION: The reliable CVA, CRA and Cobb angle use methods from the previous studies might not be suitable for the diagnose the FHP. We think that it is necessary to have more detailed evaluation methods and the radiography is also needed for clear evaluations because of some possible exceptions.

Key Words: Cobb angle, Craniorotation Angle, Craniovertebra Angle

I. Introduction

Head position and poor posture are affected by vision, the vestibular system, proprioception in the neck, position of the hyoid bone, malocclusion of the teeth and activation of the neuromuscular system (Cuccia & Carola, 2009). A common postural problem is forward head posture (Yoo, 2013). Research has identified that FHP is a clinical disorder and is an important factor in several musculoskeletal pain syndromes. FHP is an archetypal case of poor posture and is mainly related to stress, tension, and physiological changes that affect cervical regions (Seaman & Troyanovich, 2000). FHP is common in patients who use a video display terminal (e.g., computer). In other words, this posture is seen in white-collars workers who

†Corresponding Author : sjslh486@hanmail.net

This is an Open Access article distributed under the terms of the Creative Commons Attribution Non-Commercial License (<http://creativecommons.org/licenses/by-nc/3.0>) which permits unrestricted non-commercial use, distribution, and reproduction in any medium, provided the original work is properly cited.

perform highly repetitive tasks in the same position, which causes a static load on the muscles (Hagberg & Wegman, 1987). FHP has been defined as an abnormal alignment in which the external auditory meatus is positioned anterior to the vertical line through the shoulder joint (Kendall et al, 2005). The craniovertebra angle (CVA), cranirotation angle (CRA), and Cobb angle are widely used to measure and diagnose FHP.

Previous studies have used several methods to measure FHP, as follows: Quek et al. (2013) used CVA to evaluate the relationship between the kyphosis of thoracic and cervical movement in elderly patients. Harrison et al. (2000) used Cobb analysis to evaluate curvature, lordosis, and kyphosis of the cervical spine on radiography. Miyazaki et al. (2008) also used the Cobb angle to measure the cervical spine and evaluate the alignment of normal lordosis, efficient movement, and cervical function. To evaluate FHP in women, Salahzadeh et al. (2014) used a digital camera to evaluate CVA. Chansirinukor et al.¹⁰ used CVA, as developed by Wickens and Kiputh (1937) to evaluate the effects of students' book bags on their cervical and shoulder posture. In a study on the pressure-pain threshold and FHP, Chae (2002). used CVA and CRA as test markers to verify the reliability and validity of the results. These previous studies used three main methods of measurement to identify FHP. However, the present study introduces an exceptional case because it is expected that it will use a new measurement method to identify FHP and confirm the reliability and validity of the results.

II. METHODS

The Subjects were as follow: A, a 34 years-old adult male who works in a S hospital in Busan: two males, B (34 years-old) and C (30 years-old), both of whom had FHP. All subjects understood the purpose of the study and gave their written consent to participate. The Subjects had

no pathological progression in their bones, no history of cervical trauma or surgery and no prior surgical or neurological disease. Moreover, they showed no particular signs of abnormality in regular annual health check-ups, and they had not been to hospital during the previous six months. The subjects were healthy adult males with no diagnosis of disk or cervical disease, and they showed no neurological symptoms or morphological changes. Subject A has been married for six years. He is a physical therapist who has been in charge of clinical therapy for the central nervous system for the last ten years. He enjoys one hour of table tennis three times a week, and he takes care of his body by stretching at the beginning and the end of his daily routine. Subject B has been married for two years and is a typical office worker. He has worked on a computer for eight hours every day, on average, for the last ten years. He also plays computer and smartphone games for two extra hours a day. He plays soccer once a week because he enjoys the physical activity. Subject C is not married. He also has worked on a computer for eight hours every day, on average, for the last six years. He enjoys playing soccer or baseball once a week.

This study used the following methods to conduct measurements: CVA and CRA were measured with a digital camera. The distance between the camera and subject was 150 cm, and the height of the camera was held at the shoulder height of each subject. The subjects were told to find their natural head position by gradually reducing the angle with full flexion and extension of the neck until a comfortable position was attained. To enhance the reliability, the subjects were told to stand in their bare feet on a pre-designed outline of human feet (Salahzadeh et al., 2014). The subjects were instructed to fix their eyes on a marker that was attached to the front wall at eye height of eye while they were comfortably standing straight. First, to measure CVA, the subjects were told to stand comfortably while they were photographed from the lateral position. At this time, both the ear tragus and the surface

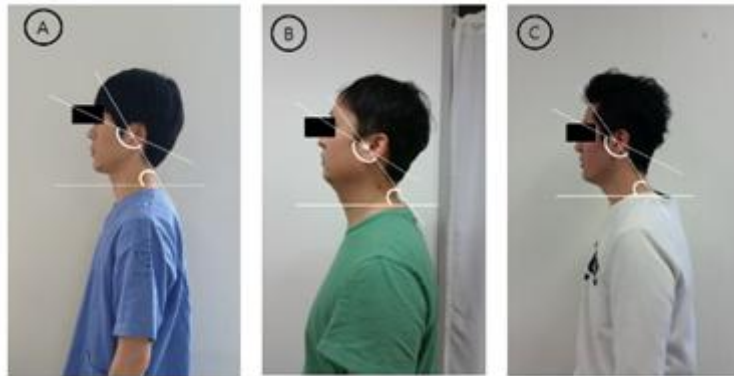


Fig. 1. CVA, CRA angle on photogrammetry(A: CVA- 65°, CRA- 148°, B: CVA- 61°, CRA- 149°, C: CVA- 51°, CRA- 149°).

of C7 spinous process were marked and printed out in order to measure the angle at which the horizontal line(through which the C7 spinous process passes) and the ear tragus meet. One line connects the spinous process of C7 to the ear tragus, and another line connects the ear tragus to the lateral canthus of the eyes. The angle at which these two lines meet is called the CRA. The CVA, CRA and the Cobb angle are also measured by radiography in the same way. However, the research angle of the image diagnosis equipment is 180 cm in distance. Hence, the external auditory meatus was selected as the measurement spot because the ear tragus is invisible in radiography. First, regarding the Cobb angle by radiography, lines that passed front and rear articular process of C1 and the inferior end plate of C7 were drawn. A further two lines were drawn parallel to the previous two lines. Finally, the angle at which each two sets of lines crossed was measured. For the CVA by radiography, a parallel line that passed the peak of C7 spinous process was drawn first. Then the angle at which the parallel line and the crossing point across the external auditory meatus(instead of the tragus) was measured (Harrison et al., 2000). For the CRA by radiography, the angle at which the spinous process of C7, the line that passed the external auditory meatus, and the line that passed both the external auditory meatus and

the lateral canthus met was measured. Three researchers each performed one measurement, and the mean value of the three measurements was adopted. The present study was conducted under the Treaty of Helsinki.

III. RESULTS

They were 32.6 ± 2.3 years in age, 174.3 ± 7.5 cm in height and 69.0 ± 6.2 kg in weight. On Photogrammetry values; CVA had 65°, CRA was 148°of Normal subject A and CVA had 61°, CRA was 149°of FHP subject B and CVA had 51°, CRA was 149°of FHP subject C (Figure 1). On Radiography values; CVA had 73°, CRA was 148°and Cobb was 50°of Normal subject A and CVA had 70°, CRA was 150°and Cobb was 53°of FHP subject B and CVA had 61°, CRA was 153°and Cobb was 31°of FHP subject C (Table 1)(Figure 2, 3).

IV. DISCUSSION

In previous studies, the CVA used to measure the FHP showed excellent test-retest reliability correlation = 0.88~0.98). In particular, the small angle of the CVA

Table 1. A comparison of CVA, CRA, Cobb angle on Photogrammetry and Radiography

	Photogrammetry		Radiography		
	CVA	CRA	CVA	CRA	Cobb
A	65°	148°	73°	148°	50°
B	61°	149°	70°	150°	53°
C	51°	149°	61°	153°	31°

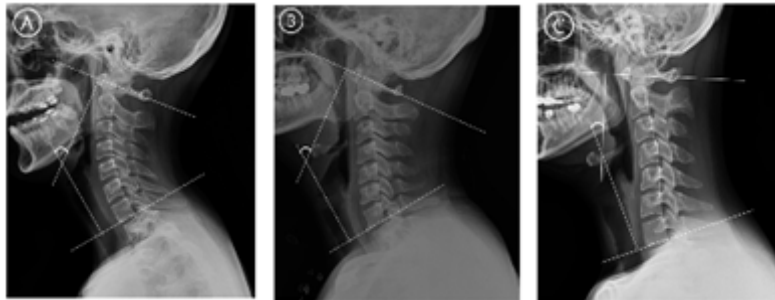


Fig. 2. Cobb angle on radiography(A- 50°, B- 53°, C- 31°)

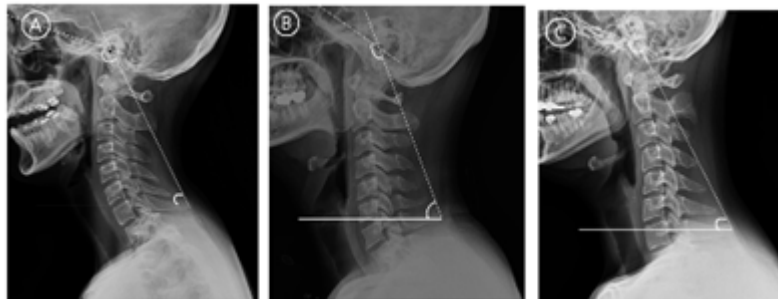


Fig. 3. CVA, CRA angle on radiography(A: CVA- 73°, CRA- 148°, B: CVA- 70°, CRA- 150°, C: CVA- 61°, CRA- 153°).

showed severe FHP. In addition, subjects with FHP showed a smaller CVA angle, which indicated that the flexion of the lower cervical was increased (Brunton et al. 2003). An angle less than 40° indicates severe FHP, between 40°~48° indicates a medium level of FHP, between 48°~55° indicates light FHP and an angle greater than 55° indicates normal status⁹⁾. In the present study, the CVA of subject A was 65°, which indicated normal status. The CVA of subject B was 61°, which was also classified as normal. The CVA of subject C was 51°, which indicates slight FHP, according to the classifications used in previous

studies. In subject B, even though FHP was observed externally, the CVA value was normal. This finding indicates that the CVA measurements used in previous studies might not be suitable for diagnosing Subject B as having FHP.

Normal CRA is >145° (Chansirinukor et al., 2001). The CRA angle in patients with FHP is larger than normal. In these patients, the head is rotated upward because of the extension of the upper cervical spine¹²⁾. The results of the present study showed that the CRA of subject A was 148° larger than 145°, which means that his head is

upward rotated because of the extension of the upper cervical spine. The CRA of subject B was 149° larger than normal. Similar results were found in subject C (149°). The result was the CRA value in subject B and subject C were 1° larger than in subject A. These findings supported a previous studies, in which the CRA in the subject with FHP was larger than normal.

In the present study, the radiographic images showed the following CVA values: Subject A, 73°; subject B, 70°; subject C, 61°. Subjects A and B showed similar CVAs. However, the CVA value in subject C (typical FHP) was 5° smaller than in subjects A and B. However, it was larger than the CVA value shown in images taken by the digital camera. This finding can be considered erroneous: the value was determined by measuring the external auditory meatus because the ear tragus does not show on radiographic images. In addition, because subject B had FHP, it was expected that he would show a smaller CVA value than subject A would. However, a similar value was not found. Thus, it can be concluded that the CVA measurements have low reliability in diagnosing subject B as having FHP.

In the present study, the radiographic images showed the following CRA values: Subject A, 148°; subject B, 150°; subject C, 153°. The CRA values in Subjects C and B (with FHP) were similar, but they were larger than that of subject A. These results supported a previous study in which the CRA values of subjects with FHP were larger than normal.

The traditional method of Cobb angle analysis uses cervical, thoracic, lumbar and lateral radiography to evaluate the curve status of lordosis and kyphosis of the spine on the sagittal plane by lateral radiography. This method is known to yield high interobserver and intraobserver correlations (Harrison et al., 2000). In C1, if the Cobb angle of C7 is smaller than 0°, it is classified as kyphosis. If the angle is between 0° to 15°, it is straight, if it is between 15° to 30°, it is hypolordosis. If the angle is between 30° to 45°, it is normal, if the angle is larger

than 45°, it can be classified as hyperlordosis⁸⁾. According to the results of the present study, Subject A was classified as having hyperlordosis because the Cobb angle was 50°. Similarly, Subject B was classified as having hyperlordosis because his Cobb angle was 53°. However, subject C was classified as normal because his Cobb angle was 31°. Subject A, the cervical curve shown by radiography indicated hyperlordosis, which supports the findings of the previous study. However, even though subjects B and C were straight, their Cobb angle values indicated hyperlordosis and normal status, respectively. Therefore, the results of the present study indicate that the Cobb angle was not sufficient to explain the cervical curve.

V. Conclusion

In conclusion, based on the results of the present study, we recommend a detailed evaluation method, in addition to CVA, CRA and Cobb measurements, which are widely used to diagnose FHP. Furthermore, because of possible exceptions, radiography is also needed to provide clear evaluations.

REFERENCES

- Brunton J, Brunton E, Aoife NM. Reliability of measuring natural head posture using the craniocervical angle. *Irish Ergonomics Review*. 2003;37-41.
- Chansirinukor W, Wilson D, Grimmer K, et al. Effects of backpacks on students: measurement of cervical and shoulder posture. *Aust J Physiother*. 2001;47(2):110-6.
- Chae YW. The measurement of forward head posture and pressure pain threshold in neck muscle. *J Korean soc Phys Ther*. 2002;14(1):117-24.
- Cuccia AM, Carola C. The measurement of craniocervical posture: a simple method to evaluate head position.

- Int J Pediatr Otorhinolaryngol. 2009;73(12):1732-6.
- Hagberg M, Wegman DH. Prevalence rates and odds ratios of shoulder-neck diseases in different occupational groups. Br J Ind Med. 1987;44(9):602-10.
- Harrison DE, Harrison DD, Cailliet R, et al. Cobb method or Harrison posterior tangent method: which to choose for lateral cervical radiographic analysis. Spine. 2000;25(16):2072-8.
- Kendall PF, Kendall ME, Geise PP, et al. Muscles: Testing and Function with Posture and Pain. Baltimore, MD: Lippincott Williams and Wilkins. 2005.
- Miyazaki M, Hymanson HJ, Morishita Y, et al. Kinematic analysis of the relationship between sagittal alignment and disc degeneration in the cervical spine. Spine. 2008;33(23):870-6.
- Salahzadeh Z, Maroufi N, Ahmadi A, et al. Assessment of forward head posture in females: observational and photogrammetry methods. J Back Musculoskeletal Rehabil. 2014;27(2):131-9.
- Seaman D, Troyanovich S. The Forward Head Posture, Dynamic Chiropractic. 2000;18:1-7.
- Quek J, Pua YH, Clark RA, et al. Effects of thoracic kyphosis and forward head posture on cervical range of motion in older adults. Man Ther. 2013;18(1):65-71.
- Wickens JS, Kiputh OW. Body mechanic analysis of Yale University freshmen. Research Quarterly. 1937; 8(4):37-48.
- Yoo WG. Effect of the Neck Retraction Taping (NRT) on Forward Head Posture and the Upper Trapezius Muscle during Computer Work. J Phys Ther Sci. 2013;25(5):581-2.