

# Computer-assisted Virtual Surgery and Splint Fabrication for Paediatric Mandible Fracture

Jung-woo Lee, D.M.D., M.S.D., Ph.D.

*Oral & Maxillofacial Surgery, Kyung Hee University School of Dentistry, Seoul, Korea*

Closed reduction using acrylic splints with circummandibular fixation has been known to be useful techniques in pediatric mandibular fractures. However, this technique has some shortcomings, including needs for impression taking or additional laboratory process, which can increase the exposure time of general anesthesia or make an additional sedation visit. Recently, the advancement of computer-aided maxillofacial surgery offers to clinicians to expansion of its application. This case report represents a technique of computer-assisted virtual reconstruction and computer-aided designed splint fabrication in a 2-year-old boy with mandibular body fracture.

**Key Words** Pediatric mandibular fracture · Computer-assisted surgery · Virtual simulation.

**Received:** November 24, 2015 / **Revised:** November 25, 2015 / **Accepted:** November 30, 2015

**Address for correspondence:** Jung-woo Lee, D.M.D., M.S.D., Ph.D.

Oral & Maxillofacial Surgery, Kyung Hee University School of Dentistry, 23 Kyunghedae-ro, Dongdaemun-gu, Seoul 02447, Korea

**Tel:** 82-2-958-9440, **E-mail:** omsace@gmail.com

## Introduction

Computer-assisted virtual surgery is a rapidly emerging topic in the dentistry field (1). Recent developments of high resolution computed tomography (CT) has enabled a better understanding of the complex anatomical structure. The combination of high resolution CT, three-dimensional reformatted images, and stereolithographic models have improved the convenience and accuracy in oral and maxillofacial surgery (1, 2). This short communication reports a technique of computer-assisted virtual reconstruction and splint fabrication in a 2-year-old boy with mandibular fracture.

## Case Report

A 2-year-old boy with no systemic and familial history visited to our clinic with chief complaint of facial trauma due to fall down. Clinically, the left facial swelling was observed with limited mouth opening. There was tenderness to palpation on the right side of condylar area. Facial CT revealed the left mandibular body and the right condylar fracture. Closed reduction of fractured mandible was planned under general anesthesia.

For virtual reconstruction, preoperative CT scans (1-mm fine cut) of the patients were obtained. Digital imaging and communication in medicine (DICOM) data obtained from the CT scans were imported into the Mimics 14.01 software (Materialise, Leuven, Belgium) to enable computer-assisted simulation, and the images were reconstructed to establish a three-dimensional virtual model (Fig. 1).

A segmentation procedure was performed on the patient's virtual displaced mandible along the fracture line. The mandible segments were virtually reduced to the native anatomic mandible contour considering the occlusal relationship (Fig. 2). The computer-assisted design (CAD) image of the splint was drawn on the reduced virtual mandible model covering the mandibular teeth, and the generated data was saved as a stereolithographic file (Fig. 3). Finally, the splint used for mandibular reduction was fabricated using a rapid prototyping technique.

Under general anesthesia, the patient placed in prefabricated splint with circummandibular wires, ensuring that the occlusion was centric and stable (Fig. 4). A postoperative facial CT was obtained to verify adaptation of the fractured segments. A week later, the patient was discharged to home.

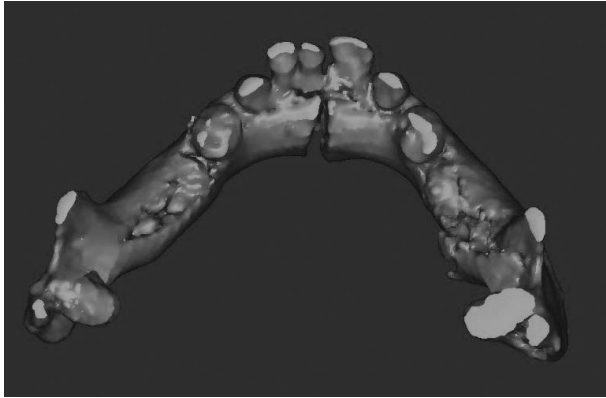


Fig. 1.

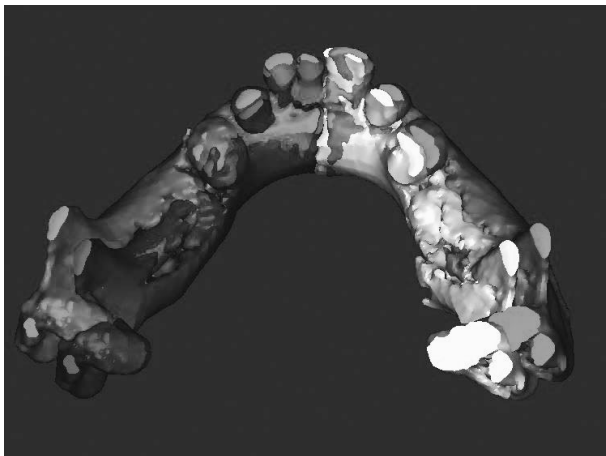


Fig. 2.

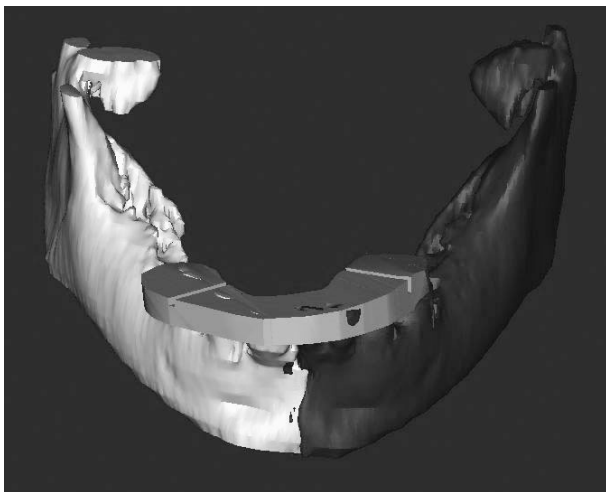


Fig. 3.

## Discussion

Pediatric mandibular fracture needs special considerations to clinicians and the management should be different from that of adults in respect of future mandibular growth and dentition development (3). Thus, more conservative approach, such as

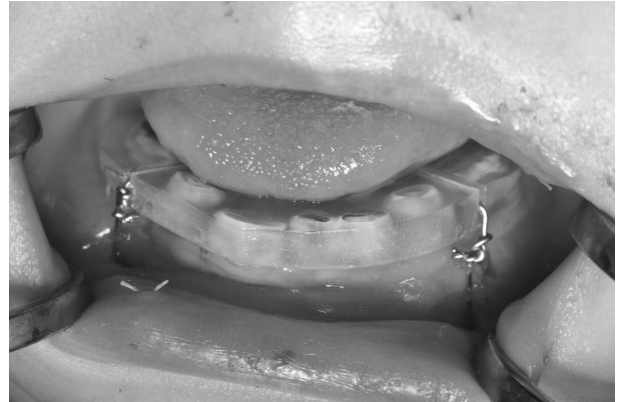

Fig. 4.

minimal manipulation without affecting functional impairment, is mandatory in children (4).

In cases of displaced mandible fracture in young children, closed reduction using acrylic splints with circummandibular wiring techniques have been shown to be effective for ensuring mandibular stability after reduction. This method has several advantages, including cost-effectiveness, ease of application and removal, and minimal trauma for adjacent anatomic structures, compared with open reduction and internal fixation or intermaxillary fixation (5, 6).

Prior to performing these techniques, impression taking and model fabrication are necessary. Sometimes, it is difficult to take impression because of restricted mouth opening due to fracture or lack of cooperation in children (7).

Mock surgery also needs to achieve proper reduction before acrylic splint fabrication (4, 6). It may need more time while the laboratory working done. All of these procedures usually performed in general anesthesia during surgery or under additional sedation prior to surgery. Thus, it may increase exposure time under anesthesia for the patient, increasing toxicity of general anesthesia. Prolonged anesthesia has been known to be a predisposing factor of perioperative complications (8). If impression taking is performed under general anesthesia, there might be increased possibilities for contamination of operation fields.

Such disadvantages can be minimized by CAD splints which are no needs for a laboratory process, such as model and splint fabrication, through this technique. Furthermore, CAD splints have been known to be high degree of precision (9). Circummandibular fixation using CAD splints may offer a considerably precise fit and reproducibility to reduction of mandibular contours.

The findings presented in this case indicate that computer-assisted virtual surgery and splint fabrication is an alternative approach to achieve effective, accurate, and simply feasible reduction and avoid long-time exposure to general anesthesia or additional sedation in pediatric mandibular fractures.

## Conclusion

Computer-assisted virtual surgery in pediatric mandibular fracture treatment reduces operation time and exposure of general anesthesia. In addition, functional and esthetic results were acquired.

## Acknowledgements

The authors declare that they have no conflicts of interest to disclose.

## References

1. Mustafa SF, Key SJ, Evans P, Sugar AW. Virtual reconstruction of defects of the orbital floor using the morphometry of the opposite maxillary sinus. *British Journal of Oral and Maxillofacial Surgery* 2010;48(5):392-93
2. Stokbro K, Aagaard E, Torkov P, Bell R, Thygesen T. Virtual planning in orthognathic surgery. *International Journal of Oral and Maxillofacial Surgery* 2014;43(8):957-65
3. Amaratunga NdS. Mandibular fractures in children-a study of clinical aspects, treatment needs, and complications. *Journal of Oral and Maxillofacial Surgery* 1988;46(8):637-40.
4. Aizenbud D, Hazan-Molina H, Emodi O, Rachmiel A. The management of mandibular body fractures in young children. *Dental Traumatology* 2009;25(6):565-70
5. Hegab A. Management of mandibular fractures in children with a split acrylic splint: a case series. *British Journal of Oral and Maxillofacial Surgery* 2012;50(6):e93-e95
6. Kocabay C, Ataç MS, Öner B, Güngör N. The conservative treatment of pediatric mandibular fracture with prefabricated surgical splint: a case report. *Dental Traumatology* 2007;23(4):247-50
7. Romeo GP, Davies S, Costello BJ. A Method for Direct Fabrication of a Lingual Splint for Management of Pediatric Mandibular Fractures. *Plastic and Reconstructive Surgery Global Open* 2013;1(7):e51
8. Farwell DG, Reilly DF, Weymuller Jr EA, Greenberg DL, Staiger TO, Futran NA. Predictors of perioperative complications in head and neck patients. *Archives of Otolaryngology-Head & Neck Surgery* 2002;128(5):505-11
9. Xia JJ, Gateno J, Teichgraber JF, Christensen AM, Lasky RE, Lemoine JJ, et al. Accuracy of the computer-aided surgical simulation (CASS) system in the treatment of patients with complex cranio-maxillofacial deformity: A pilot study. *Journal of Oral and Maxillofacial Surgery* 2007;65(2):248-54