

## Clinical Article

# Acute Contralateral Radiculopathy after Unilateral Transforaminal Lumbar Interbody Fusion

Kyoung-Min Jang, M.D., Seung-Won Park, M.D., Ph.D., Young-Baeg Kim, M.D., Ph.D., Yong-Sook Park, M.D., Ph.D., Taek-Kyun Nam, M.D., Ph.D., Young-Seok Lee, M.D.

Department of Neurosurgery, College of Medicine, Chung-Ang University, Seoul, Korea

**Objective :** Cases of contralateral radiculopathy after a transforaminal lumbar interbody fusion with a single cage (unilateral TLIF) had been reported, but the phenomenon has not been explained satisfactorily. The purpose of this study was to determine its incidence, causes, and risk factors.

**Methods :** We did retrospective study with 546 patients who underwent a unilateral TLIF, and used CT and MRI to study the causes of contralateral radicular symptoms that appeared within a week postoperatively. Clinical and radiological results were compared by dividing the patients into the symptomatic group and asymptomatic group.

**Results :** Contralateral symptoms occurred in 32 (5.9%) of the patients underwent unilateral TLIF. The most common cause of contralateral symptoms was a contralateral foraminal stenosis in 22 (68.8%), screw malposition in 4 (12.5%), newly developed herniated nucleus pulposus in 3 (9.3%), hematoma in 1 (3.1%), and unknown origin in 2 patients (6.3%). 16 (50.0%) of the 32 patients received revision surgery. There was no difference in visual analogue scale and Oswestry disability index between the two groups at discharge. Both preoperative and postoperative contralateral foraminal areas were significantly smaller, and postoperative segmental angle was significantly greater in the symptomatic group comparing to those of the asymptomatic group ( $p < 0.05$ ).

**Conclusion :** The incidence rate is not likely to be small (5.9%). If unilateral TLIF is performed for cases when preoperative contralateral foraminal stenosis already exists or when a large restoration of segmental lordosis is required, the probability of developing contralateral radiculopathy is increased and caution from the surgeon is needed.

**Key Words :** Spinal stenosis · Complication · Radiculopathy · Lumbar manipulation · Lordosis.

## INTRODUCTION

Blume and Rojas<sup>2)</sup> first published in the 1980s a modified unilateral approach of posterior lumbar interbody fusion (PLIF), named transforaminal lumbar interbody fusion (TLIF). Harms and Jeszensky<sup>12)</sup> confirmed its treatment outcome and contributed to the popularization of TLIF during the 1990s. Humphreys et al.<sup>18)</sup> and Hankenberg et al.<sup>11)</sup> reported that TLIF led to minimal loss of normal structure compared with PLIF, and that it showed no differences in blood loss, operation time, and hospital day. Recently, TLIF has shown a high success rate and a low complication rate, and it has been widely used as an effective treatment for various degenerative lumbar spinal disorders<sup>11,14,20,25,26)</sup>.

When initially performing TLIF, two cages were usually inserted through bilateral approaches<sup>2,12)</sup>. As there have been several reports that unilateral cage showed no significant difference

in treatment outcome and complications compared with bilateral cage and that it is biomechanically stable, TLIF with a single cage (unilateral TLIF) has been performed widely in recent years<sup>3,8)</sup>. In the unilateral TLIF, the approach side is decided according to the side of the patient's symptom. On the other hand, contralateral foramen can be indirectly decompressed by increased disc height with a single cage inserted in the ipsilateral side<sup>17,20)</sup>. However, Hunt et al.<sup>19)</sup> recently reported a case showing postoperative contralateral side leg pain as a complication of a unilateral TLIF. Although the authors did not present precise data, they hypothesized that an increase of lordosis during surgery might have effect on contralateral foraminal stenosis and contralateral leg symptoms.

Despite the possibility of developing contralateral radicular symptom after a unilateral TLIF, there have been no studies analyzing causes of this phenomenon. We tried to investigate risk

• Received : July 1, 2015 • Revised : September 14, 2015 • Accepted : October 12, 2015

• Address for reprints : Seung-Won Park, M.D., Ph.D.

Department of Neurosurgery, College of Medicine, Chung-Ang University, 102 Heukseok-ro, Dongjak-gu, Seoul 06973, Korea  
Tel : +82-2-6299-3190, Fax : +82-2-821-8409, E-mail : nspsw@cau.ac.kr

• This is an Open Access article distributed under the terms of the Creative Commons Attribution Non-Commercial License (<http://creativecommons.org/licenses/by-nc/3.0>) which permits unrestricted non-commercial use, distribution, and reproduction in any medium, provided the original work is properly cited.

factors to find out causes of contralateral radiculopathy after a unilateral TLIF in this study.

## MATERIALS AND METHODS

### Patient populations

We did a retrospective study with patients who received TLIF in the L1–S1 area between January 2005 and December 2013. We performed unilateral TLIF for a total of 592 patients, complaining low back pain and unilateral radicular symptoms, under diagnosis of degenerative stenosis with ipsilateral foraminal stenosis, spondylolisthesis, and repeated postoperative herniated nucleus pulposus (HNP). Patients with congenital or degenerative spinal deformities were not included in the study group. We performed bilateral TLIF and decompression for the patients with bilateral radicular symptoms, who were not included in this study either. A total of 546 patients were enrolled in this study excluding 46 patients who received the operation upon a diagnosis of infectious spondylitis, spine tumor, or fracture at the index level.

MRI was performed for all patients who had radicular symptoms which did not solved with medication and nerve blocks for more than 1 month. CT was prescribed for the patients who were indicated for surgery according to the MRI findings. Foraminal stenosis was diagnosed as root compression and loss of perineural fat layer at the neural foramen on MRI. There was no foraminal stenosis on the contralateral side even though some patients had smaller contralateral foraminal area comparing to those of other asymptomatic levels.

The patients were divided into two groups : one group comprised those who presented with new leg symptoms including pain, hypoesthesia, paresthesia, and motor weakness, in the side contralateral to the original symptom side within 1 week after surgery (symptomatic group), and the other group comprised those without contralateral symptom after surgery (asymptomatic group).

### Surgical techniques and postoperative management

Unilateral TLIF was performed by two different neurosurgeons. Their TLIF procedures are almost same. The patient was positioned with lumbar extension by placing pillows at the chest and pelvis. After midline vertical skin incision, unilateral partial laminectomy and facetectomy were done. Contralateral side decompression was not performed and the contralateral ligamentum flavum was saved in unilateral TLIF. After a meticulous endplate preparation for upper and lower endplates, disc space was filled with autologous bone chips from lamina and facet, and the CAPSTONER<sup>®</sup> PEEK cage (Medtronic Sofamor Danek Inc., Memphis, TN, USA) filled with the autologous bone chips was inserted obliquely. The cage was located in the center and crossed midline of the disc space. Pedicle screw fixation was done after the cage insertion. Rod compression was not performed routinely due to prevent contralateral foraminal ste-

nosis where the decompression was not performed. The wound was closed after bilateral pedicle screw fixation.

Simple radiograph and CT were taken for all the patients with postoperative contralateral radicular symptoms. MRI was taken if further evaluation was needed additional to the CT study. Nerve blocks for medial branch and root were performed for initial pain control. Revision surgery was indicated in cases the nerve blocks were not effective. However, revision surgery was immediately performed when root compression was definitive on image studies or motor weakness was accompanied. Revision surgeries, such as facetectomy, discectomy, screw reposition, and hematoma removal, were done for the contralateral pathologies.

### Causes of contralateral symptoms

The causes of contralateral symptoms in the symptomatic group were categorized into five, contralateral foraminal stenosis, newly developed HNP, screw malposition, hematoma, and unknown origin. Contralateral foraminal stenosis was defined as a decreased postoperative foraminal area (FA) compared with the preoperative value; HNP as a newly developed HNP on the side contralateral to the TLIF side; and screw malposition as invasion of contralateral pedicle screw into central canal or neural foramen. Hematoma meant epidural hematoma formed in the surgical wound compressing dural sac.

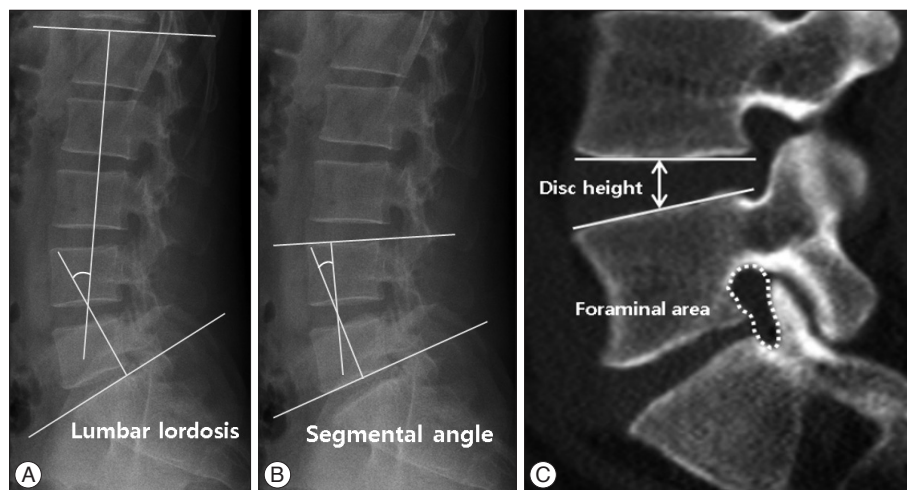
### Clinical outcome

To assess the difference in clinical outcomes between the symptomatic and asymptomatic groups, visual analogue scale (VAS) scores and Oswestry disability index (ODI) were measured immediately before surgery and at 3 months after surgery.

### Radiographic measurement

Disc height (DH), lumbar lordosis (LL), and segmental angle (SA) were measured with plain radiographs before and after the surgery. DH was defined as the distance between the upper and lower endplates at the center of the disc space at the index level. LL was measured as the angle between the two upper endplates of L1 and S1. SA was measured as the angle between the upper and lower endplates at the disc level where surgery was performed (Fig. 1)<sup>24</sup>. Postoperative changes of LL and SA were calculated by subtracting the preoperative angle from the postoperative angle in each group. Preoperative and postoperative DH, LL, and SA values were compared in each group, and postoperative changes of LL and SA were also compared. Contralateral foraminal areas (FA) were checked from preoperative and postoperative CT. FA (mm<sup>2</sup>) was defined as the area of bony neural foramen at the center of pedicle from the sagittal view of CT. Postoperative change of FA was measured as the difference between preoperative and postoperative FAs.

All the factors were measured 3 times blindly for patient information, and the mean values were used for this study.



**Fig. 1.** Measurement of lumbar lordosis, segmental angle, disc height and contralateral foraminal area. A : Lumbar lordosis : the angle between L1 and S1 upper endplates. B : Segmental angle : the angle between the upper and lower endplates at the disc space where surgery was done. C : Disc height: the distance between the upper and lower endplates at the center of the disc space at the surgical site from the sagittal view in the plain radiograph. Foraminal area : the area of bony neural foramen.

**Table 1.** Demographic characteristics of symptomatic and asymptomatic groups

	Symptomatic group	Asymptomatic group	<i>p</i> -value
Number	32 (5.9%)	514 (94.1%)	
Age (years)	57.4±19.5	61.5±17.7	0.201
Sex (M/F)	13/20	212/301	0.858
Diagnosis			0.958
Spinal stenosis	25 (78.1%)	373 (72.5%)	
Degenerative spondylolisthesis	5 (15.6%)	85 (16.5%)	
Repeated disc herniation	3 (9.3%)	51 (9.9%)	
Others	0	4 (0.8%)	
No. of levels operated	1.6±1.0	2.1±2.0	0.155
Operation level			0.813
L2-3	0	12 (2.3%)	
L3-4	3 (9.3%)	45 (8.7%)	
L4-5	19 (59.3%)	340 (66.2%)	
L5-S1	11 (34.3%)	116 (22.6%)	
Operation time (minutes)	192.5±100.8	210.5±120.8	0.402
BMD T-score	-1.8±1.0	-2.0±1.5	0.450

*p*<0.05 was considered statistically significant. BMD : bone mineral density

### Statistical analysis

Data obtained through the measured VAS and ODI scores and radiological analysis of LL, SA, and FA were analyzed for statistical significance by using Student's t-test, and a *p*-value of <0.05 was considered to be statistically significant.

## RESULTS

The incidence of contralateral radiculopathy after a unilateral TLIF surgery was 5.9% (32/546). There was no statistically significant difference in mean age, sex ratio, bone mineral density T-score, and the number of operated levels between symptomatic and asymptomatic groups (Table 1).

### Causes of contralateral symptoms

The most common cause was contralateral foraminal stenosis (22 patients, 68.8%), followed by screw malposition (4 pa-

tients, 12.5%), HNP (3 patients, 9.3%), hematoma (1 patients, 3.1%), and unknown origin (2 patients, 6.3%) (Table 2).

### Revision surgery

Revision surgery was performed for 16 (50.0%) of the 32 patients in the symptomatic group. Revision surgery was performed for 10 cases of contralateral foraminal stenosis (45.5%), 4 cases of screw malposition (100%), 1 case of HNP (33.3%), and 1 case of hematoma (100%). The 2 cases of unknown origin were successfully treated with nerve block.

### Radiological factors

Pre- and postoperative disc heights were not different significantly between the two groups. The changes of disc height after surgery were similar in both groups (Table 3).

Preoperative LLs were 35.8±10.3° and 37.2±11.8°, and postoperative LLs were 39.2±12.8° and 38.7±13.6° in symptomatic

and asymptomatic groups, respectively, showing no significant difference between the two groups. The change of LL was higher in symptomatic group ( $3.0\pm 3.5^\circ$ ) than asymptomatic group ( $2.7\pm 1.8^\circ$ ), but there was no statistical significance (Table 3).

Pre- and postoperative SAs of asymptomatic group were  $14.8\pm 9.1^\circ$  and  $15.9\pm 10.2^\circ$ , which showed no significant difference between the two angles. On the contrary, pre- and postoperative SAs of symptomatic group were  $13.7\pm 8.8^\circ$  and  $19.6\pm 12.8^\circ$ , which showed a significant increase of the angle after surgery ( $p<0.05$ ). The amount of change in SAs after surgery were  $6.0\pm 2.7^\circ$  and  $1.5\pm 2.0^\circ$  in symptomatic and asymptomatic groups, respectively, revealing a significantly large increase in symptomatic group ( $p<0.01$ ) (Table 4). In conclusion, SA and change of SA were seem to be an important factor for occurrence of contralateral radiculopathy after unilateral TLIF, whereas LA was not.

Preoperative contralateral FA value of symptomatic group ( $56.2\pm 13.3\text{ mm}^2$ ) was significantly smaller than that of asymptomatic group ( $69.2\pm 19.3\text{ mm}^2$ ) ( $p<0.01$ ). Postoperative contralateral FAs were  $38.8\pm 9.3\text{ mm}^2$  and  $78.2\pm 18.3\text{ mm}^2$  in symp-

tomatic and asymptomatic groups, indicating marked decrease in the symptomatic group ( $p<0.01$ ). Furthermore, postoperative changes of FA were  $-16.4\pm 6.3\text{ mm}^2$  and  $10.6\pm 5.9\text{ mm}^2$  in symptomatic and asymptomatic groups, showing significant increase of the area after surgery in symptomatic group ( $p<0.01$ ) (Table 4).

### Clinical outcomes

Preoperative VAS scores were  $5.8\pm 3.2$  and  $6.0\pm 2.9$  in symptomatic and asymptomatic groups, and VAS scores at 3 months after surgery were  $1.8\pm 1.1$  and  $1.6\pm 1.2$ , respectively, without significant difference between the two groups (Table 4). Preoperative ODI's were  $66.8\pm 21.7\%$  and  $61.0\pm 23.5\%$  in symptomatic and asymptomatic groups, and ODI's at 3 months after surgery were  $18.6\pm 10.5\%$  and  $20.2\pm 12.8\%$ , respectively, showing no significant difference between the two groups (Table 5).

## DISCUSSION

TLIF operation has been widely used due to its excellent surgical outcome, relatively few complications, and high fusion rate<sup>11,22,26</sup>. Additionally, the TLIF technique can preserve normal structures such as the facet joint and muscles at the contralateral side by using the unilateral approach<sup>4,11,15,29</sup>.

Contralateral radiculopathy after a unilateral TLIF is a complication spine surgeons often encounter<sup>19,20</sup>. Although its causes have been studied through case reports, to our best knowledge, there has been no detailed study analyzing the cause. The incidence of contralateral radiculopathy after a unilateral TLIF was 5.9% based on our results. It seems to be closely related with con-

**Table 2.** Causes of contralateral radiculopathy after unilateral TLIF

Cause of the symptom	No. of patients	Revision surgery
Contralateral foraminal stenosis	22 (68.8%)	10 (45.5%)
Screw malposition	4 (12.5%)	4 (100%)
HNP	3 (9.3%)	1 (33.3%)
Postoperative hematoma	1 (3.1%)	1 (100%)
Unknown	2 (6.3%)	0 (0%)
Total	32 (100%)	16 (50%)

TLIF : transforaminal lumbar interbody fusion, HNP : herniated nucleus pulposus

**Table 3.** Pre- and Postoperative disc height and lumbar lordosis for unilateral TLIF

	Disc height			Lumbar lordosis		
	Pre-op	Post-op	Change	Pre-op	Post-op	Change
Symptomatic group	$8.0\pm 3.3$	$11.8\pm 3.9$	$3.9\pm 0.9$	$35.8\pm 10.3$	$39.2\pm 12.8$	$3.0\pm 3.5$
Asymptomatic group	$8.5\pm 3.1$	$12.0\pm 3.4$	$3.6\pm 1.1$	$37.2\pm 11.8$	$38.7\pm 13.6$	$2.7\pm 1.8$
<i>p</i> -value	0.371	0.626	0.125	0.506	0.837	0.390

$p<0.05$  was considered statistically significant. Pre-op : preoperative, Post-op : postoperative, TLIF : transforaminal lumbar interbody fusion

**Table 4.** Pre- and postoperative segmental angle and contralateral foraminal area for unilateral TLIF

	Segmental angle			Contralateral foraminal area		
	Pre-op	Post-op	Change	Pre-op	Post-op	Change
Symptomatic group	$13.7\pm 8.8$	$19.6\pm 12.8$	$6.0\pm 2.7$	$56.2\pm 13.3$	$38.8\pm 9.3$	$-16.4\pm 6.3$
Asymptomatic group	$14.8\pm 9.1$	$15.9\pm 10.2$	$1.5\pm 2.0$	$69.2\pm 19.3$	$78.2\pm 18.3$	$10.6\pm 5.9$
<i>p</i> -value	0.501	$<0.05^*$	$<0.01^*$	$<0.01^*$	$<0.01^*$	$<0.01^*$

\* $p<0.05$  was considered statistically significant. Pre-op : preoperative, Post-op : postoperative, TLIF : transforaminal lumbar interbody fusion

**Table 5.** Visual analogue scale (VAS) and Oswestry disability index (ODI) data for symptomatic and asymptomatic groups

	Symptomatic group	Asymptomatic group	<i>p</i> -value
Pre-op VAS	$5.8\pm 3.2$	$6.0\pm 2.9$	0.703
Post-op VAS	$1.8\pm 1.1$	$1.6\pm 1.2$	0.352
Pre-op ODI (%)	$66.8\pm 21.7$	$61.0\pm 23.5$	0.168
Post-op ODI (%)	$18.6\pm 10.5$	$20.2\pm 12.8$	0.483

$p<0.05$  was considered statistically significant. Pre-op : immediate preoperative, Post-op : 3 months after surgery



tralateral foraminal stenosis, newly developed HNP, screw malposition, hematoma, among which contralateral foraminal stenosis was the most common cause. The contralateral complication itself didn't seem to affect the clinical results, which, we think, might be related with early diagnosis and proper management.

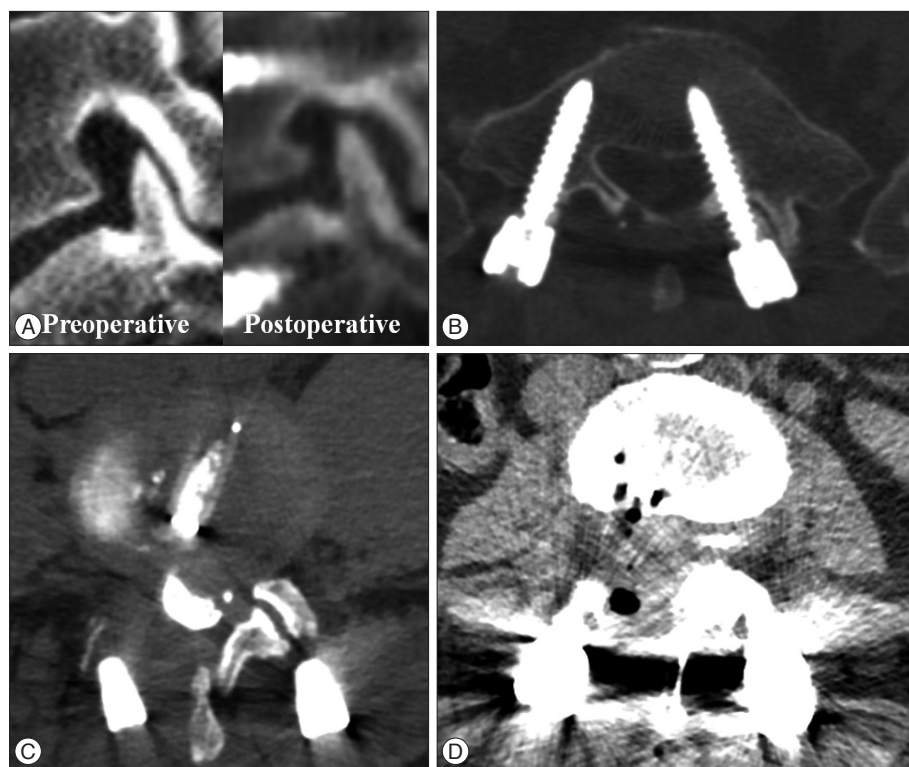
Although there have been many studies on various postoperative complications of lumbar spinal surgery through a number of literatures<sup>1,5,6,10,27</sup>, there have been no study on the incidence of contralateral radiculopathy after a unilateral TLIF. Thus, it is difficult to directly compare the degree of incidence shown in this study. However, the incidence rate of 5.9% is not likely to be small, considering the high frequency of TLIF use<sup>28</sup>. The reasons of unexpectedly high incidence seem to be the sporadic development of the complication, mild and transient symptom which can be controlled well with conservative management. So, it seems that we considered indiscreetly or ignored the complication. Therefore, the postoperative contralateral radiculopathy seems to be an important complication of unilateral TLIF surgeons should be cautious in the sense of not only its high incidence but also its unpredictability. So, analyzing its causes might be helpful in reducing or sometimes predicting the complication in the future.

Neural foramen decompression during TLIF operation is crucial for improving radiculopathy<sup>20,32</sup>. Hunt et al.<sup>19</sup> indicated contralateral foraminal stenosis after a unilateral TLIF might be the cause of contralateral symptoms. But their report didn't seem to have an objective evidence because of a lack of quantitative analysis with a large number of cases. We were able to confirm the causes in a relatively objective manner by analyzing var-

ious factors in a large number of patients in this study.

Iwata et al.<sup>20</sup> reported the morphological change in the contralateral lumbar foramen after surgery in 58 patients who underwent unilateral TLIF. They proved the contralateral foraminal size was significantly increased with unilateral TLIF, which showed the possibility of indirect decompression of the contralateral side by unilateral insertion of a single cage. However, they reported that contralateral decompression was not highly effective when preoperative contralateral foraminal stenosis was present. This is comparable with the previous report of Hunt et al.<sup>19</sup> that preexisting foraminal stenosis on the contralateral side might be the cause of contralateral symptoms. In our study, the contralateral foraminal area was already significantly smaller preoperatively and its size decreased significantly after surgery in the patients of symptomatic group. It seems to be ideal that establishing proper indications of unilateral or bilateral TLIF according to contralateral foraminal size, which must be investigated in the future study.

Appropriate restoration of lordosis during lumbar spine surgery is important for improving clinical outcomes and preventing failed back surgery syndrome with an iatrogenic flat back<sup>7,9,16,21,30,31</sup>. On the other hand, increase in segmental lordotic angle of the operative level can cause contralateral foraminal stenosis<sup>19,20</sup>. Our study showed similar results, both postoperative segmental angle and its change after surgery at the index level were found to be significant risk factors for contralateral radiculopathy after unilateral TLIF. However, the lordotic angle of whole lumbar spine did not have any effect on postoperative contralateral symptoms. Therefore, it seems that contralateral foraminal de-



**Fig. 2.** Cases of contralateral radiculopathy after unilateral TLIF. A : Contralateral foraminal stenosis after surgery, showing superior and ventral subluxation of the superior articular process of inferior vertebra. B : Contralateral screw malposition. C : Newly developed HNP at the contralateral side. D : Epidural hematoma. TLIF : transforaminal lumbar interbody fusion, HNP : herniated nucleus pulposus.

compression or inserting bilateral cages might be safer when increase of segmental lordosis by surgery is predicted especially in the patients who already have narrow contralateral foramen preoperatively.

Lumbar foraminal stenosis can be caused by superior and ventral subluxations of the superior articular process of the inferior vertebra<sup>13,24</sup>. The same changes were also observed in some of our patients of symptomatic group (Fig. 2). The superior or ventral displacement of superior articular process in the neural foramen seem to be related with inappropriately high grade rod compression at the contralateral side after the cage insertion or inappropriately high grade lordosis at the index level, respectively. The effect of superior articular process subluxation on the postoperative contralateral foraminal stenosis must be greater in the patients whose contralateral foraminal area was already smaller preoperatively. So, the size and insertion angle of cage seem to be risk factors for contralateral foraminal stenosis after unilateral TLIF. The curved cage was reported to be superior to the straight cage for making lumbar segmental angle<sup>23</sup>. But we used the straight cage for all cases in this study because of surgeons' preference. So, further study probing the mechanism or risk factors of contralateral foraminal stenosis related with cage seems to be necessary in the future.

It was difficult to understand the mechanism of the newly developed HNP contralateral to the operation side at first. But we now are understanding that the unilaterally inserted cage might push the disc material to the contralateral side and result in contralateral disc herniation. It seems to be related with the insufficient disc removal remaining large amount of disc material in the disc space.

Because this was conducted as a retrospective study, a prospective study will be needed in the future for a controlled study on more diverse factors. Although we were able to find several causes by analyzing various factors before and after surgery, we believe that there must be more risk factors which occur during surgery. CT was mainly used as a postoperative examination to avoid MRI artifacts caused by screw and rod. However, the disadvantage was that changes in soft tissues such as ligament and annulus in the foramen were not able to be counted properly by CT. The preoperative contralateral neural foraminal size seems to be an important risk factor, but unfortunately we did not assess the critical foraminal size which may provoke contralateral symptom after surgery.

The contralateral symptoms after unilateral TLIF may be reduced by being cautious to the risk factors. But we think another surgical techniques : bilateral TLIF, bilateral decompression with unilateral TLIF, should be needed to prevent the complication.

## CONCLUSION

Postoperative contralateral radiculopathy is a complication of unilateral TLIF which can be caused by contralateral foraminal stenosis, screw malposition, newly developed HNP, and hema-

toma. The contralateral foraminal stenosis seems to be related with preoperative foraminal stenosis and postoperative increase of segmental angle. Considering its relatively high incidence and unpredictability, finding risk factors and mechanisms will be helpful to prevent or solve the problem.

## • Acknowledgements

This work was supported by the Technology Innovation Program (ATC; Advanced Technology Center, 10048523, Development of fluorography system under 50% irradiation dose with image quality on par with angiographic equipment to global leader in next generation) funded By the Ministry of Trade, industry & Energy (MI, Korea).

## References

- Barnes B, Rodts GE Jr, Haid RW Jr, Subach BR, McLaughlin MR : Allograft implants for posterior lumbar interbody fusion : results comparing cylindrical dowels and impacted wedges. *Neurosurgery* 51 : 1191-1198; discussion 1198, 2002
- Blume H, Rojas C : Unilateral lumbar interbody fusion (posterior approach) utilizing dowel graft. *J Neurol Orthop Surg* 2 : 171-175, 1981
- Chiang MF, Zhong ZC, Chen CS, Cheng CK, Shih SL : Biomechanical comparison of instrumented posterior lumbar interbody fusion with one or two cages by finite element analysis. *Spine (Phila Pa 1976)* 31 : E682-E689, 2006
- Cutler AR, Siddiqui S, Mohan AL, Hillard VH, Cerabona F, Das K : Comparison of polyetheretherketone cages with femoral cortical bone allograft as a single-piece interbody spacer in transforaminal lumbar interbody fusion. *J Neurosurg Spine* 5 : 534-539, 2006
- DiPaola CP, Molinari RW : Posterior lumbar interbody fusion. *J Am Acad Orthop Surg* 16 : 130-139, 2008
- Elias WJ, Simmons NE, Kaptain GJ, Chaddock JB, Whitehill R : Complications of posterior lumbar interbody fusion when using a titanium threaded cage device. *J Neurosurg* 93 (1 Suppl) : 45-52, 2000
- Farcy JB, Schwab FJ : Management of flatback and related kyphotic decompensation syndromes. *Spine (Phila Pa 1976)* 22 : 2452-2457, 1997
- Fogel GR, Toohey JS, Neidre A, Brantigan JW : Is one cage enough in posterior lumbar interbody fusion : a comparison of unilateral single cage interbody fusion to bilateral cages. *J Spinal Disord Tech* 20 : 60-65, 2007
- Glassman SD, Bridwell K, Dimar JR, Horton W, Berven S, Schwab F : The impact of positive sagittal balance in adult spinal deformity. *Spine (Phila Pa 1976)* 30 : 2024-2029, 2005
- Goz V, Weinreb JH, Schwab F, Lafage V, Errico TJ : Comparison of complications, costs, and length of stay of three different lumbar interbody fusion techniques : an analysis of the Nationwide Inpatient Sample database. *Spine J* 14 : 2019-2027, 2014
- Hackenberg L, Halm H, Bullmann V, Vieth V, Schneider M, Liljenqvist U : Transforaminal lumbar interbody fusion : a safe technique with satisfactory three to five year results. *Eur Spine J* 14 : 551-558, 2005
- Harms JG, Jerszensky D : The unilateral, transforaminal approach for posterior lumbar interbody fusion. *Orthop Traumatol* 6 : 88-99, 1998
- Hasegawa T, An HS, Haughton VM, Nowicki BH : Lumbar foraminal stenosis : critical heights of the intervertebral discs and foramina. A cryomicrotome study in cadavera. *J Bone Joint Surg Am* 77 : 32-38, 1995
- Hey HW, Hee HT : Lumbar degenerative spinal deformity : surgical options of PLIF, TLIF and MI-TLIF. *Indian J Orthop* 44 : 159-162, 2010
- Houten JK, Post NH, Dryer JW, Errico TJ : Clinical and radiographically/neuroimaging documented outcome in transforaminal lumbar interbody fusion. *Neurosurg Focus* 20 : E8, 2006
- Hsieh PC, Koski TR, O'Shaughnessy BA, Sugrue P, Salehi S, Ondra S, et

- al. : Anterior lumbar interbody fusion in comparison with transforaminal lumbar interbody fusion : implications for the restoration of foraminal height, local disc angle, lumbar lordosis, and sagittal balance. *J Neurosurg Spine* 7 : 379-386, 2007
17. Hu SS, Tribus CB, Diab M, Ghanayem AJ : Spondylolisthesis and spondylolysis. *J Bone Joint Surg Am* 90 : 656-671, 2008
  18. Humphreys SC, Hodges SD, Patwardhan AG, Eck JC, Murphy RB, Covington LA : Comparison of posterior and transforaminal approaches to lumbar interbody fusion. *Spine (Phila Pa 1976)* 26 : 567-571, 2001
  19. Hunt T, Shen FH, Shaffrey CI, Arlet V : Contralateral radiculopathy after transforaminal lumbar interbody fusion. *Eur Spine J* 16 Suppl 3 : 311-314, 2007
  20. Iwata T, Miyamoto K, Hioki A, Fushimi K, Ohno T, Shimizu K : Morphologic changes in contralateral lumbar foramen in unilateral cantilever transforaminal lumbar interbody fusion using kidney-type intervertebral spacers. *J Spinal Disord Tech* 28 : E270-E276, 2015
  21. Jang JS, Lee SH, Min JH, Kim SK, Han KM, Maeng DH : Surgical treatment of failed back surgery syndrome due to sagittal imbalance. *Spine (Phila Pa 1976)* 32 : 3081-3087, 2007
  22. Kim CW, Siemionow K, Anderson DG, Phillips FM : The current state of minimally invasive spine surgery. *J Bone Joint Surg Am* 93 : 582-596, 2011
  23. Kim JT, Shin MH, Lee HJ, Choi DY : Restoration of lumbopelvic sagittal alignment and its maintenance following transforaminal lumbar interbody fusion (TLIF) : comparison between straight type versus curvilinear type cage. *Eur Spine J*, 2015 [Epub ahead of print]
  24. Kim SB, Jeon TS, Heo YM, Lee WS, Yi JW, Kim TK, et al. : Radiographic results of single level transforaminal lumbar interbody fusion in degenerative lumbar spine disease : focusing on changes of segmental lordosis in fusion segment. *Clin Orthop Surg* 1 : 207-213, 2009
  25. Lee CK, Park JY, Zhang HY : Minimally invasive transforaminal lumbar interbody fusion using a single interbody cage and a tubular retraction system : technical tips, and perioperative, radiologic and clinical outcomes. *J Korean Neurosurg Soc* 48 : 219-224, 2010
  26. Lee YS, Kim YB, Park SW, Chung C : Comparison of transforaminal lumbar interbody fusion with direct lumbar interbody fusion : clinical and radiological results. *J Korean Neurosurg Soc* 56 : 469-474, 2014
  27. Molinari RW, Gerlinger T : Functional outcomes of instrumented posterior lumbar interbody fusion in active-duty US servicemen : a comparison with nonoperative management. *Spine J* 1 : 215-224, 2001
  28. Mummaneni PV, Dhall SS, Eck JC, Groff MW, Ghogawala Z, Watters WC 3rd, et al. : Guideline update for the performance of fusion procedures for degenerative disease of the lumbar spine. Part 11 : interbody techniques for lumbar fusion. *J Neurosurg Spine* 21 : 67-74, 2014
  29. Potter BK, Freedman BA, Verwiebe EG, Hall JM, Polly DW Jr, Kuklo TR : Transforaminal lumbar interbody fusion : clinical and radiographic results and complications in 100 consecutive patients. *J Spinal Disord Tech* 18 : 337-346, 2005
  30. Schwab F, Patel A, Ungar B, Farcy JP, Lafage V : Adult spinal deformity-postoperative standing imbalance : how much can you tolerate? An overview of key parameters in assessing alignment and planning corrective surgery. *Spine (Phila Pa 1976)* 35 : 2224-2231, 2010
  31. Smith A, O'Sullivan P, Straker L : Classification of sagittal thoraco-lumbo-pelvic alignment of the adolescent spine in standing and its relationship to low back pain. *Spine (Phila Pa 1976)* 33 : 2101-2107, 2008
  32. Yan DL, Pei FX, Li J, Soo CL : Comparative study of PILF and TLIF treatment in adult degenerative spondylolisthesis. *Eur Spine J* 17 : 1311-1316, 2008