



A simple method of intraoperative intubation tube change

Jin Yong Cho, Hyeon Min Kim, Jae Young Ryu

Department of Oral and Maxillofacial Surgery, Gachon University Gil Medical Center, Incheon, Korea

Abstract (J Korean Assoc Oral Maxillofac Surg 2014;40:250-252)

Nasotracheal intubation should be performed in patients with jaw fractures because maxillomandibular fixation is required. However, when there are concomitant fractures of the nose and facial bones, an intubation tube positioned at the nose makes it difficult to perform an intricate surgery. In order to overcome these problems, a variety of ways to change the position of the tube have been introduced. We describe a simple technique of switching the tube from a nasal to oral position, which was easily executed in a patient with concomitant nasal and mandibular fractures, accompanied by a literature review.

Key words: Airway management, Intubation, Jaw fractures

[paper submitted 2014. 6. 2 / revised 2014. 7. 8 / accepted 2014. 7. 17]

I. Introduction

Airway maintenance through naso-endotracheal intubation enables a surgeon to perform a successful surgery and avoid tube interference in patients requiring maxillo-mandibular fixation. However, if a patient is undergoing simultaneous nasal and oral surgery, nasal intubation can be an impediment in performing an accurate and esthetically successful procedure. Typically, naso-endotracheal intubation has been considered inappropriate in orthognathic surgery with rhinoplasty or concomitant fracture of the jaw and/or nasal bone.

In order to overcome this problem, Werther et al.¹ contrived an effective way to convert nasal intubation to oral intubation without extubation. Submental intubation was described in 1986² as an alternative method to avoid tracheostomy and allow free intraoperative access to dental occlusion and to the nasal bone in severe maxillofacial trauma patients. Retromolar intubation³ is another method involving placement of a flexible armored tube in the retromolar area. Other

options to manage the airway while maintaining an adequate arrangement for surgery include removing and replacing the tube, delaying the operation, and tracheostomy.

We describe a simple technique of switching the tube from a nasal to oral position, first introduced by Werther et al.¹, which was easily executed in a patient with concomitant nasal and mandibular fractures.

II. Case Report

In the presented case, an ordinary nasal intubation was conducted by an anesthesiologist, and an adequate reduction of facial fractures with maxillomandibular fixation was completed. The fracture site was fixed with a plate and screws to stabilize the fractured segments. Before completion of the oral surgery, mobility between bony pieces during mouth opening was assessed. Because a considerable amount of mouth opening was needed to switch from the nasal tube to the oral tube, it was important to stably fix the fractures. All of the drapes around the patient's head were removed to ensure proper visualization and prepare for an emergency if the airway was compromised. The patient was then hyperoxygenated through the nasal tube.(Fig. 1)

To prevent migration of the tube or accidental extubation, the tube was grasped firmly at the level of the tongue base using a long hemostat. After removal of the tube connector, the nasal tube was cut just outside of the naris.(Fig. 2) Then, the tube connector was assessed to ensure that it could be

Jae Young Ryu

Department of Oral and Maxillofacial Surgery, Gachon University Gil Medical Center, 21 Namdong-daero 774beon-gil, Namdong-gu, Incheon 405-760, Korea
TEL: +82-32-460-3373 FAX: +82-32-460-3101
E-mail: face@gilhospital.com

©This is an open-access article distributed under the terms of the Creative Commons Attribution Non-Commercial License (<http://creativecommons.org/licenses/by-nc/3.0/>), which permits unrestricted non-commercial use, distribution, and reproduction in any medium, provided the original work is properly cited.

Copyright © 2014 The Korean Association of Oral and Maxillofacial Surgeons. All rights reserved.

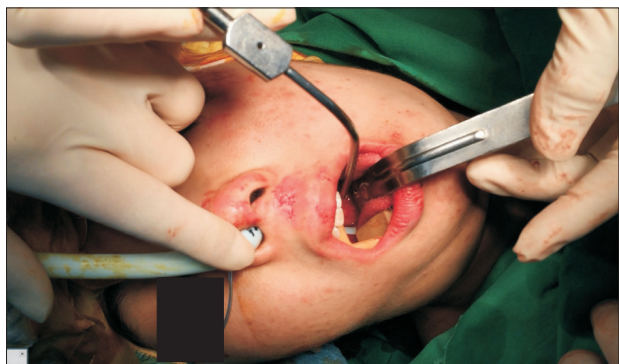

Fig. 1. Nasal endotracheal tube is placed. A long clamp was placed at the level of the tongue base.

Jin Yong Cho et al: A simple method of intraoperative intubation tube change. J Korean Assoc Oral Maxillofac Surg 2014

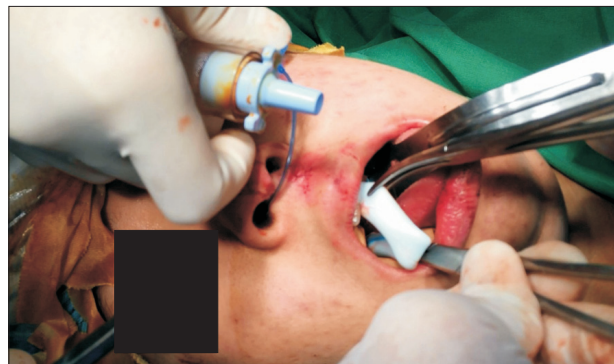

Fig. 3. Clinical photo showing the nasal tube being pulled and delivered orally. Notice the cuff inflation tube remains in the nose.

Jin Yong Cho et al: A simple method of intraoperative intubation tube change. J Korean Assoc Oral Maxillofac Surg 2014

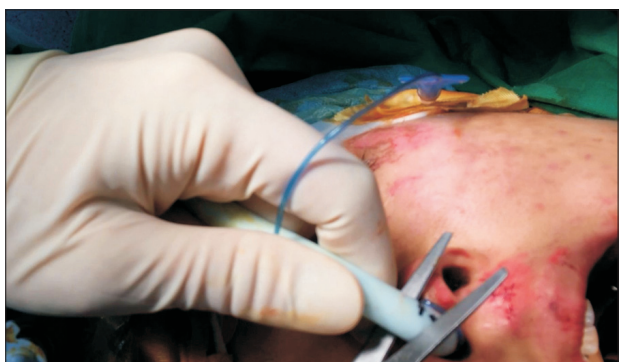

Fig. 2. Clinical photo showing the cutting of the nasal tube just outside of the naris.

Jin Yong Cho et al: A simple method of intraoperative intubation tube change. J Korean Assoc Oral Maxillofac Surg 2014

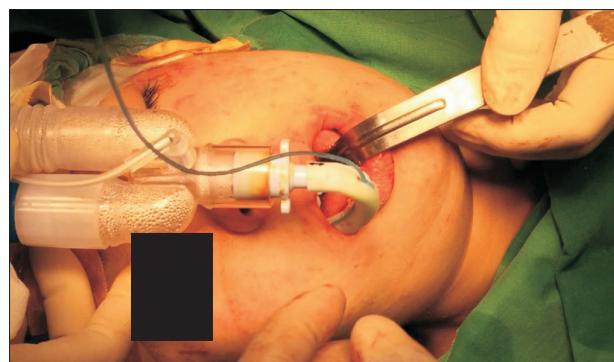


Fig. 4. Completion of the nasal tube switch to an oral endotracheal tube without extubation.

Jin Yong Cho et al: A simple method of intraoperative intubation tube change. J Korean Assoc Oral Maxillofac Surg 2014

connected to the cut end of the nasal tube before performing the switch to the oral position. At this time, cuff ballooning was maintained in order to prevent aspiration. Again, the tube connector was removed. By elevating the soft palate, more space was secured, and another long hemostat was positioned at the level of the uvula. Then, the tube was pushed from the external naris to the nasopharynx by one surgeon while another simultaneously pulled the tube from the oropharynx to the outside of the oral cavity using a long clamp.(Fig. 3) The tube connector was reconnected with the intubation tube that was now in the oral position. The cuff inflation tube was deflated and delivered to the oral cavity using the same method.

The lung sounds were assessed by an anesthesiologist. Because there was no problem, the endotracheal tube was fixed in the oral cavity with tape. This airway control method allowed the transition from a nasal endotracheal intubation to a standard oral endotracheal intubation.(Fig. 4) Using this method, an accurate and delicate operation of the nose was

possible without interference of the tube.

III. Discussion

Changing the intubation tube to the oral position from a nasal position is a very unusual situation and should be executed by oral and maxillofacial surgeons performing simultaneous maxillomandibular fixation and nasal surgery. To facilitate accuracy of dental occlusion and perform proper nasal surgery, a variety of ways to change the position of the tube have been introduced.

The traditional method is to remove the nasal endotracheal tube and reinsert it via the oral cavity. However, there is a risk of aspiration due to bleeding in the nasal and/or oral cavity during reintubation; thus, most anesthesiologists desire to avoid this method.

The alternative routes for maintaining an airway during an operation are tracheotomy and submental intubation. These

methods require additional surgery to form a space to insert the tube and can lead to complications including bleeding, injury to adjacent structures, emphysema, pneumothorax or pneumomediastinum, blockage or displacement of the cannula, tracheitis, cellulitis, tracheal stenosis, tracheoesophageal fistula, and major scarring⁴. Goldenberg et al.⁵ reported that incidences of complications in tracheotomies range between 5% and 40%, with the agreed risk approximated at 15%. Lee et al.⁶ mentioned that the complications of submental intubation included salivary fistula, submental tunnel contamination or infection, hemorrhage and submental scarring.

Retromolar intubation was first introduced as a useful method for intubation in Pierre-Robin children by Bonfils⁷. It is an effective method that does not interfere with the occlusion due to creation of a space in the retromolar site. Nevertheless, the problem with retromolar intubation is that the intubation tube is positioned in the operation field, and additional surgery, such as removal of the bone or extraction of the third molar, is necessary. If sufficient space is not secured, there is a risk of imprecise occlusion⁸.

We have been utilizing the explained method of converting from a nasal to an oral endotracheal tube in patients with nasal and jaw fractures and have produced desirable results. The tube switching method introduced in this paper is noninvasive and technically simple. The time required for the tube switching is approximately 30 seconds. However, in a situation where a nasal endotracheal tube is not likely to be used, such as with an accompanied cranial base fracture, other methods for keeping the airway open during surgery should be considered.

Although there have not been any reported complications with our tube switching method, some problems are possible. If the surgeon does not grasp the intubation tube firmly on the oral side, the intubation tube could migrate during the push and pull motion. With less careful manipulation, a portion of the tube could also be torn. Lastly, it is necessary to keep the

nasal and oral cavities clean before the tube change to reduce the possibility of aspiration due to excessive secretion or bleeding.

Tracheal tubes are composed of polyvinyl chloride (PVC), nylon, polytetrafluoroethylene, or silicone rubber. PVC tubes offer several advantages over other types of tubes and are therefore the most commonly used⁹. There is a difference in the flexibility of PVC tubes depending on the type used. The proposed technique is recommended for use with a soft and flexible PVC tube.

Conflict of Interest

No potential conflict of interest relevant to this article was reported.

References

1. Werther JR, Richardson G, McIlwain MR. Nasal tube switch: converting from a nasal to an oral endotracheal tube without extubation. *J Oral Maxillofac Surg* 1994;52:994-6.
2. Hernández Altemir F. The submental route for endotracheal intubation. A new technique. *J Maxillofac Surg* 1986;14:64-5.
3. Martínez-Lage JL, Eslava JM, Cebrecos AI, Marcos O. Retromolar intubation. *J Oral Maxillofac Surg* 1998;56:302-5.
4. Lima SM Jr, Asprino L, Moreira RW, de Moraes M. A retrospective analysis of submental intubation in maxillofacial trauma patients. *J Oral Maxillofac Surg* 2011;69:2001-5.
5. Goldenberg D, Ari EG, Golz A, Danino J, Netzer A, Joachims HZ. Tracheotomy complications: a retrospective study of 1130 cases. *Otolaryngol Head Neck Surg* 2000;123:495-500.
6. Lee SS, Huang SH, Wu SH, Sun IF, Chu KS, Lai CS, et al. A review of intraoperative airway management for midface facial bone fracture patients. *Ann Plast Surg* 2009;63:162-6.
7. Bonfils P. Difficult intubation in Pierre-Robin children, a new method: the retromolar route. *Anaesthetist* 1983;32:363-7.
8. Arora S, Rattan V, Bhardwaj N. An evaluation of the retromolar space for oral tracheal tube placement for maxillofacial surgery in children. *Anesth Analg* 2006;103:1122-5.
9. Kirby RR, Gravenstein N, Lobato EB, Gravenstein JS. Airway devices and their application. In: Kirby RR, et al., eds. *Clinical anesthesia practice*. 2nd ed. Philadelphia: W. B. Saunders; 2002:303-28.