

Case Report

Delayed Dural Arteriovenous Fistula after Microvascular Decompression for Hemifacial Spasm

Sung Han Kim, M.D., Won Seok Chang, M.D., Hyun Ho Jung, M.D., Jin Woo Chang, M.D., Ph.D.

Department of Neurosurgery, Yonsei University College of Medicine, Seoul, Korea

Dural arteriovenous fistula (AVF) is very rare, acquired lesion that may present with intracranial hemorrhage or neurological deficits. The etiology is not completely understood but dural AVF often has been associated with thrombosis of the involved dural sinuses. To our knowledge, this is the first well documented intracranial hemorrhage case caused by dural AVF following microvascular decompression for hemifacial spasm. A 49-year-old male patient had left microvascular decompression of anterior inferior cerebellar artery via retrosigmoid suboccipital craniotomy. The patient was in good condition without any residual spasm or surgery-related complications. However, after 10 months, he suffered sudden onset of amnesia and dysarthria. Computed tomography and magnetic resonance imaging revealed the presence of dural AVF around the left transverse-sigmoid sinus. The dural AVF was treated with Onyx[®] (ev3) embolization. At the one-year follow up visit, there were no evidence of recurrence and morbidity related to dural AVF and its treatment. This case confirms that the acquired etiology of dural AVF may be associated with retrosigmoid suboccipital craniotomy for hemifacial spasm, even though it is an extremely consequence of this procedure.

Key Words : Dural arteriovenous fistula · Hemifacial spasm · Microvascular decompression · Retrosigmoid suboccipital craniotomy.

INTRODUCTION

Hemifacial spasm (HFS) is a relatively rare movement disorder most commonly caused by vascular compression of the facial cranial nerve at its root exit zone from the brainstem. It is characterized as involuntary intermittent twitching of the muscles of the face. Microvascular decompression (MVD) was initially introduced by Gardner and Sava⁶⁾, and was popularized by Jannetta et al.⁹⁾. Since its introduction as a treatment for HFS, MVD via retrosigmoid suboccipital approach has become the treatment of choice due to its excellent results and low operative complications. Potential complications following MVD include hearing deficit, facial palsy, cerebrospinal fluid (CSF) leakage, low cranial nerve palsy, hemorrhage, cerebellar injury, meningitis, and death^{12,17)}. The delayed post-operative dural arteriovenous fistula (AVF) is very rare complication of this approach and has rarely been reported to date. In this report we present a case of delayed postoperative dural AVF occurring at the surgical site after retrosigmoid suboccipital craniotomy for MVD in a patient with HFS.

CASE REPORT

A 49-year-old man, ten months prior to his present admission, had been operated in our institution for left HFS caused by vascular compression of the facial nerve by the left anterior inferior cerebellar artery (AICA) (Fig. 1). There were no evidence of pathologic lesions such as hemorrhage, sinus thrombus, vascular malformation, tumors in preoperative imaging studies, including computed tomography (CT) and magnetic resonance imaging (MRI). A left retrosigmoid suboccipital craniotomy was performed to alleviate the spasm. The size of the craniotomy was relatively small and about twice the size of a quarter coin. At the time of the operation, we did not expose the transverse and sigmoid sinuses of the patient. At the end of the operation, we performed a watertight dural closure. The muscle and scalp were closed in the anatomical layers. The patient's hemifacial spasm completely disappeared postoperatively. Ten months after the operation, the patient complained of amnesia and dysarthria. The patient had no history of head trauma before and after operation. CT showed intracranial hemorrhage (ICH) on left temporoparietal subcortical area (Fig. 2A) and CT angiography (CTA) showed the abnormal enhanced vessels on left transverse-sigmoid sinus

• Received : May 19, 2014 • Revised : July 4, 2014 • Accepted : August 14, 2014

• Address for reprints : Jin Woo Chang, M.D., Ph.D.

Department of Neurosurgery, Yonsei University College of Medicine, 50-1 Yonsei-ro, Seodaemun-gu, Seoul 120-752, Korea
Tel : +82-2-2228-2150, Fax : +82-2-393-9979, E-mail : jchang@yuhs.ac

• This is an Open Access article distributed under the terms of the Creative Commons Attribution Non-Commercial License (<http://creativecommons.org/licenses/by-nc/3.0>) which permits unrestricted non-commercial use, distribution, and reproduction in any medium, provided the original work is properly cited.

(Fig. 2B). Magnetic resonance angiography (MRA) clearly showed a dural AVF at the site of the previous surgery (Fig. 2C, D). Digital subtraction angiography (DSA) demonstrated a dural AVF of the left transverse-sigmoid sinus fed by the left occipital artery (Fig. 3A). After superselective catheterization of the left occipital artery, which supplied the affected sinus of the dural AVE, embolization with Onyx[®] (total 3.5 cc; ev3, Irvine, CA, USA) was performed successfully (Fig. 3B). One year later, follow-up DSA did not show any recurrence of lesion (Fig. 3C). The patient's condition was in normal without recurrence of hemifacial spasm.

DISCUSSION

Dural AVF is low pressure, spontaneously occurring communications between vessels of internal and external carotid origin that supply the dura and a dural venous sinus. Dural AVFs are relatively rare, with a prevalence of 0.15 per 100000 people per year, and constitute 6–15% of all intracranial AVFs with most being located in the posterior fossa². Although the etiology of dural AVFs is still controversial, they are generally classified into congenital or acquired. Acquired dural AVFs have been reported to develop secondarily to sinus thrombosis^{8,19,21}, head injury⁴, cerebral infarction⁷, and craniotomy¹⁸. Among the variable causes, acquired dural AVF after craniotomy had rarely been reported^{18,21,22}. Although the time of occurrence, location, and type of surgery were variable according to the reports, sinus thrombosis, thrombophlebitis, and late intrasinus hypertension following sacrifice of the venous sinus were suggested as underlying mechanism of dural AVF¹⁹.

In our case, the dural AVF developed at the site of the previous craniotomy was not associated with sacrifice of the transverse-sigmoid sinus or trauma. Also, there were no evidence of dural sinus thrombosis in the preoperative imaging studies. There was one report which addressed the symptomatic dural AVF after craniotomy for the trigeminal neuralgia surgery¹⁸. Different from previous report, our case was unique in nature that the initial presentation of the AVF was intracranial hemorrhage, which was confirmed in the CT scan. Maybe our case

is the first report in which the dural AVF after craniotomy was initially presented as ICH. Besides, this initial presentation of

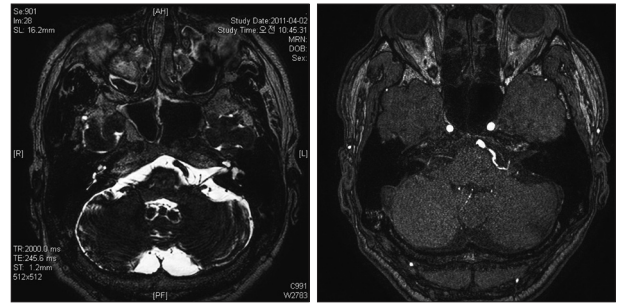


Fig. 1. Preoperative magnetic resonance image show that left anterior inferior cerebellar artery compressed left facial nerve at the root exit zone.

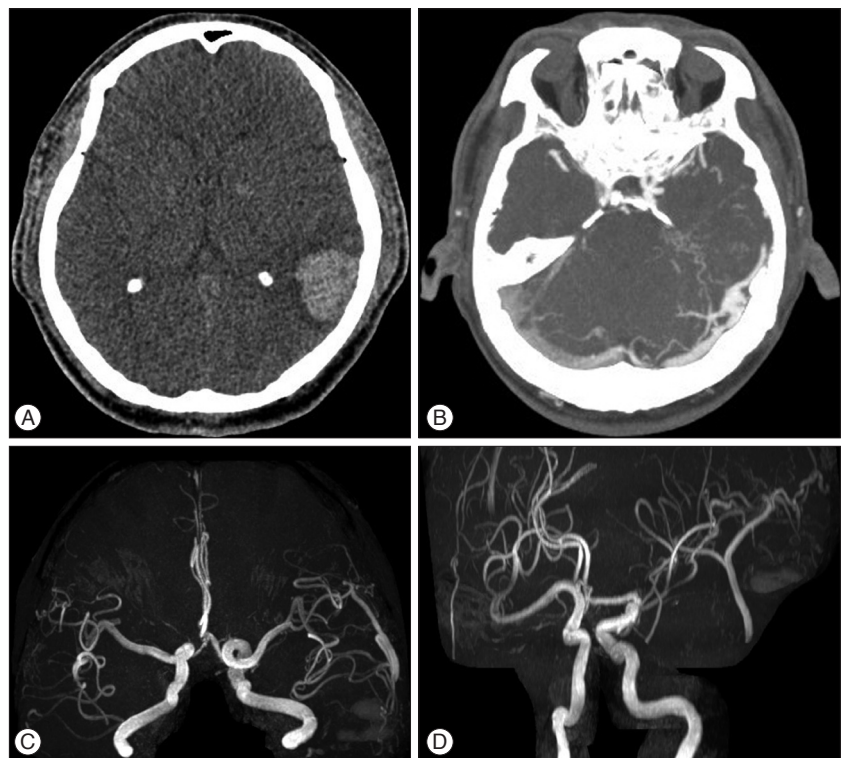


Fig. 2. A : Computed tomography (CT) shows the high density lesion on the left temporoparietal subcortical area. B : CT angiography shows the abnormal enhanced vessels on left transverse-sigmoid sinus. C and D : MRAs show dural arteriovenous fistula that has occipital artery as a feeder and draining transverse-sigmoid sinus.

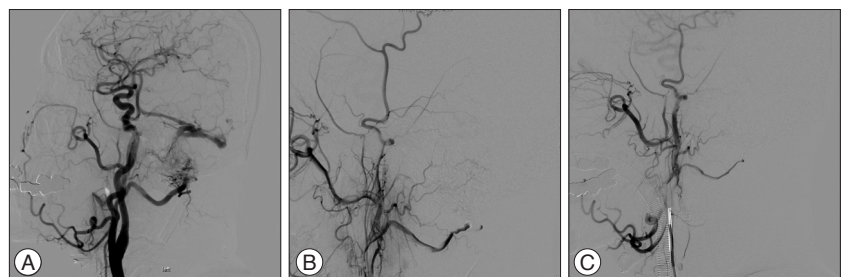


Fig. 3. A : Pre-embolization left external carotid artery angiographic image shows the dural AVF with feeders from left occipital artery. B : Post-embolization angiographic image shows nearly complete occlusion of left sigmoid sinus dural arteriovenous fistula (AVF). C : There is no residual dural AVF at the follow-up angiography obtained 12 months after embolization.

dural AVF would lead to difficulties in exact diagnosis. At this point, CTA and MRA was very effective tool which confirmed the dural AVF as a cause of ICH.

The first option of treatment for dural AVF is transarterial embolization^{1,10}. Although the coil embolization is an attractive option, transarterial Onyx[®] embolization has recently been recommended as a safe therapeutic alternative. It is very effective with type I and II dural AVF through the Cognard classification because it reduces the shunted blood flow and facilitates subsequent transvenous embolization or surgery. However, Onyx[®] embolizations¹⁵ have limitations and risks, including cardiac Onyx[®] embolization⁵, reflexive bradyarrhythmia^{16,20}, visual hallucination, and cranial nerve palsy³. If the transarterial or transvenous embolization failed, we considered the next treatment option to be surgical interruption of the fistulas^{13,21} or radiosurgery^{11,14}. In our case, the dural AVF was completely obstructed during initial procedure and there were no leakage or evidence of complication in the immediate and late (12 months) follow-up angiography. Therefore, no further surgeries were needed and the patient was benefitted from this minimally-invasive procedure.

CONCLUSION

The dural AVF is rare complication after retrosigmoid suboccipital craniotomy and intensive monitoring for the complication would be warranted after microvascular decompression.

References

1. Bink A, Berkefeld J, Kraus L, Senft C, Ziemann U, du Mesnil de Rochemont R : Long-term outcome in patients treated for benign dural arteriovenous fistulas of the posterior fossa. *Neuroradiology* 53 : 493-500, 2011
2. Brown RD Jr, Wiebers DO, Nichols DA : Intracranial dural arteriovenous fistulae : angiographic predictors of intracranial hemorrhage and clinical outcome in nonsurgical patients. *J Neurosurg* 81 : 531-538, 1994
3. Caragine LP, Halbach VV, Dowd CF, Ng PP, Higashida RT : Parallel venous channel as the recipient pouch in transverse/sigmoid sinus dural fistulae. *Neurosurgery* 53 : 1261-1266 ; discussion 1266-1267, 2003
4. Chaudhary MY, Sachdev VP, Cho SH, Weitzner I Jr, Puljic S, Huang YP : Dural arteriovenous malformation of the major venous sinuses : an acquired lesion. *AJNR Am J Neuroradiol* 3 : 13-19, 1982
5. Cognard C, Gobin YP, Pierot L, Bailly AL, Houdart E, Casasco A, et al. : Cerebral dural arteriovenous fistulas : clinical and angiographic correlation with a revised classification of venous drainage. *Radiology* 194 : 671-680, 1995
6. Gardner WJ, Sava GA : Hemifacial spasm-a reversible pathophysiologic state. *J Neurosurgery* 19 : 240-247, 1962
7. Hanaoka M, Matsubara S, Satoh K, Nagahiro S : Dural arteriovenous fistulae after cerebral infarction : report of two cases. *Neurosurgery* 68 : E575-E579 ; discussion E580, 2011
8. Houser OW, Baker HL Jr, Rhoton AL Jr, Okazaki H : Intracranial dural arteriovenous malformations. *Radiology* 105 : 55-64, 1972
9. Jannetta PJ, Abbasy M, Maroon JC, Ramos FM, Albin MS : Etiology and definitive microsurgical treatment of hemifacial spasm. Operative techniques and results in 47 patients. *J Neurosurg* 47 : 321-328, 1977
10. Jiang C, Lv X, Li Y, Wu Z : Transarterial Onyx packing of the transverse-sigmoid sinus for dural arteriovenous fistulas. *Eur J Radiol* 80 : 767-770, 2011
11. Kida Y : Radiosurgery for dural arteriovenous fistula. *Prog Neurol Surg* 22 : 38-44, 2009
12. Kim JB, Chung JC, Chang WS, Chung SS, Chang JW : Outcomes of surgical treatment for hemifacial spasm associated with the vertebral artery : severity of compression, indentation, and color change. *Acta Neurochir (Wien)* 154 : 501-508, 2012
13. Kimura T, Shojima M, Koizumi T, Fukaya S, Ichikawa Y, Morita A : Surgical treatment of a dural arteriovenous fistula in the superior petrosal sinus of an elderly patient with minimal suboccipital craniotomy : case report. *Neurol Med Chir (Tokyo)* 49 : 465-467, 2009
14. Loumiotis I, Lanzino G, Daniels D, Sheehan J, Link M : Radiosurgery for intracranial dural arteriovenous fistulas (DAVFs) : a review. *Neurosurg Rev* 34 : 305-315 ; discussion 315, 2011
15. Lv X, Jiang C, Li Y, Liu L, Liu J, Wu Z : The limitations and risks of transarterial Onyx injections in the treatment of grade I and II DAVFs. *Eur J Radiol* 80 : e385-e388, 2011
16. Lv X, Jiang C, Li Y, Wu Z : Embolization of intracranial dural arteriovenous fistulas with Onyx-18. *Eur J Radiol* 73 : 664-671, 2010
17. Miller LE, Miller VM : Safety and effectiveness of microvascular decompression for treatment of hemifacial spasm : a systematic review. *Br J Neurosurg* 26 : 438-444, 2012
18. Nabors MW, Azzam CJ, Albanna FJ, Gulya AJ, Davis DO, Kobrine AI : Delayed postoperative dural arteriovenous malformations. Report of two cases. *J Neurosurg* 66 : 768-772, 1987
19. Sakaki T, Morimoto T, Nakase H, Kakizaki T, Nagata K : Dural arteriovenous fistula of the posterior fossa developing after surgical occlusion of the sigmoid sinus. Report of five cases. *J Neurosurg* 84 : 113-118, 1996
20. Schaller B : Trigemino-cardiac reflex. A clinical phenomenon or a new physiological entity? *J Neurol* 251 : 658-665, 2004
21. Sundt TM Jr, Piepgras DG : The surgical approach to arteriovenous malformations of the lateral and sigmoid dural sinuses. *J Neurosurg* 59 : 32-39, 1983
22. Watanabe A, Takahara Y, Ibuchi Y, Mizukami K : Two cases of dural arteriovenous malformation occurring after intracranial surgery. *Neuroradiology* 26 : 375-380, 1984