

## Case Report

# Subdural Hemorrhage Mimicking Peripheral Neuropathy

Hye Ihn Kim, M.D., Yeo Jin Oh, M.D., Yu Na Cho, M.D., Young-Chul Choi, M.D., Ph.D.

Department of Neurology, Yonsei University College of Medicine, Seoul, Korea

Subdural hemorrhage (SDH) can manifest various neurologic symptoms. However, SDH presenting with only hand weakness has rarely been reported. We report two SDH cases with only hand weakness mimicking peripheral neuropathy. Since SDH can present with hand weakness only, we suggest the clinicians to do a careful history taking and recommend a CT scan in the elderly patients.

**Key Words** : Subdural hemorrhage · Monoparesis · Peripheral neuropathyIntroduction.

## INTRODUCTION

Subdural hemorrhage (SDH) occurs from tearing of the bridging and cortical veins, often in the elderly after mild trauma. Chronic SDH usually occurs after 3 weeks to 4 months after head trauma, but SDH developed 9 months after the head trauma has been reported<sup>3)</sup>. Absent history of direct head injury was also reported<sup>1)</sup>.

SDH can manifest with various neurologic symptoms such as altered mental status, focal neurologic deficit, headache, and seizures. Common neurological deficits include hemiparesis, bilateral oculomotor nerve palsies, nystagmus, ataxia, and aphasia<sup>4)</sup>. However, the evaluation of SDH in hand weakness has rarely been reported. We have reported two cases of SDH with only hand weakness mimicking peripheral neuropathy.

## CASE REPORT

### Case 1

An 89-year-old male visited with left hand weakness for 2 months. He had no past medical and surgical history other than hypertension. He did sustain an injury on his left shoulder without direct head trauma 2 months prior to the visit.

A neurologic examination showed motor weakness in the left abductor digiti quinti muscle and first dorsal interosseous muscles. There were no sensory deficits to light touch, pain, position, and vibration sense. Deep tendon reflexes were normoactive and

symmetric. There were no pathologic reflexes such as Babinski's sign and ankle clonus.

A nerve conduction study and needle electromyography was done in a local physical medicine and rehabilitation clinic. The left ulnar sensory responses were of low amplitude and increased proportion of polyphasic motor unit potentials were observed in the left biceps brachii, brachioradialis, anconeus, triceps, flexor digiti indicis, abductor digiti quinti, and left C5, 6, and 8 paravertebral muscles, suggestive of left C5, 6, and 8 radiculopathy. First impressions were the left ulnar neuropathy and left brachial plexopathy. However, this could not explain the focal hand weakness without any sensory change.

A brain MRI was done to the patient due to his old age and a history of hypertension and slipping down. SDH was found in the right frontal and parietal convexity and along the falx (Fig. 1A, B). He was admitted to the neurosurgery department and underwent burr hole drainage. He was discharged with improved motor weakness.

### Case 2

A 83-year-old female visited with a tingling sensation in her right hand and weakness for 3 days. She had hypertension and cervical multiple spondylosis and had fallen backwards, hitting the occiput with no loss of consciousness, 3 days before the symptom started.

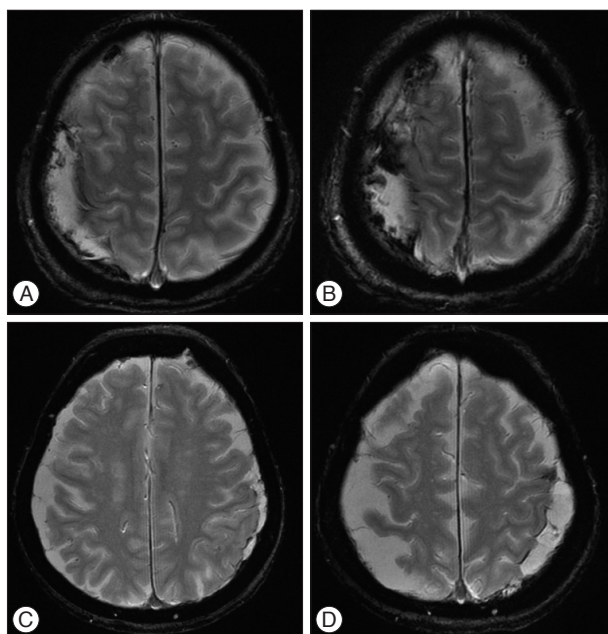
Initial neurologic examination only showed motor weakness in right hand grip. There were no sensory deficits to light touch,

• Received : April 1, 2014 • Revised : July 24, 2014 • Accepted : August 14, 2014

• Address for reprints : Young-Chul Choi, M.D., Ph.D.

Department of Neurology, Gangnam Severance Hospital, Yonsei University College of Medicine, 211 Eonju-ro, Gangnam-gu, Seoul 135-720, Korea  
Tel : +82-2-2019-3323, Fax : +82-2-3462-5904, E-mail : ycchoi@yuhs.ac

• This is an Open Access article distributed under the terms of the Creative Commons Attribution Non-Commercial License (<http://creativecommons.org/licenses/by-nc/3.0>) which permits unrestricted non-commercial use, distribution, and reproduction in any medium, provided the original work is properly cited.



**Fig. 1.** Brain magnetic resonance image shows subdural hemorrhage in the right frontal and parietal convexity (A and B). Brain magnetic resonance image shows subdural hemorrhage in the left temporal and parietal convexity (C and D).

pain, position, and vibration sense. Biceps jerk and brachioradialis jerk were mildly hypoactive on the right side. There were no pathologic reflexes such as Babinski's sign and ankle clonus. Initial impressions included cervical radiculopathy. She refused to be admitted and was discharged against the advice of the doctors.

Two days later, the patient revisited the hospital with aggravated hand weakness and newly developed motor aphasia. Brain MRI showed SDH in the left temporal and parietal convexity (Fig. 1C, D). Symptoms gradually improved with conservative treatment with antihypertensive medication.

## DISCUSSION

In the first patient, the motor deficit was limited to the left abductor quinti and first dorsal interosseous muscles, both innervated by the ulnar nerve. Despite the absence of sensory change, the nerve conduction study revealed low amplitude sensory nerve action potential suggestive of left ulnar neuropathy. Also, in addition to the shoulder trauma history, the needle electromyography showed abnormalities in various other muscles, suggestive of left brachial plexopathy. However, neither of these diagnoses was compatible with the focal hand weakness without any sensory change.

In the second patient, the history of multiple cervical spondylosis and hand weakness with mild hypoactive deep tendon reflex were suggestive findings of cervical radiculopathy. However, the diagnosis of cervical radiculopathy with no sensory symptoms was

insufficient. However, since the patient was initially discharged against the advice of the hospital, we did not have time for further studies.

As mentioned previously, when a possible diagnosis does not exactly fit the neurologic examination in elderly patients with the recent history of trauma, subdural hemorrhage should always be suspected.

There have been previous reports on interhemispheric subdural hematoma presented with one leg paresis or a hemiparesis worse in the leg than the arm, also known as 'falx syndrome'<sup>3)</sup>. This may be due to the cortical distribution of the primary motor cortex. However, evaluations of SDH on hand weakness only have rarely been reported.

The cases with only hand weakness mimicking peripheral nerve lesion were reported in ischemic stroke. Castaldo et al.<sup>2)</sup> reported a series of 35 stroke patients with isolated distal arm or hand weakness with small cortical infarction involving precentral and/or postcentral gyrus and often the parietal lobe. Timsit et al.<sup>6)</sup> reported of six patients showing evolving isolated hand palsy with infarction of the angular gyrus of the inferior parietal lobe.

In our cases, SDH was shown along the contralateral frontoparietal cortices and temporoparietal cortices, respectively. Although the parietal lobe is known as sensory cortex, motor fibers and subcortical association fibers are known to be interconnected in the parietal lobe. Thus, the cause of weakness in our cases may be due to the compression of the contralateral parietal lobe.

## CONCLUSION

Since subdural hemorrhage can present with only hand weakness and mimic peripheral neuropathy, we suggest that the clinicians be more careful in recording patients' history and recommend a CT or MR scan in the elderly patients.

## References

1. Adhiyaman V, Asghar M, Ganeshram KN, Bhowmick BK : Chronic subdural haematoma in the elderly. *Postgrad Med J* 78 : 71-75, 2002
2. Castaldo J, Rodgers J, Rae-Grant A, Barbour P, Jenny D : Diagnosis and neuroimaging of acute stroke producing distal arm monoparesis. *J Stroke Cerebrovasc Dis* 12 : 253-258, 2003
3. Fruin AH, Juhl GL, Taylon C : Interhemispheric subdural hematoma. Case report. *J Neurosurg* 60 : 1300-1302, 1984
4. Luxon LM, Harrison MJ : Chronic subdural haematoma. *Q J Med* 48 : 43-53, 1979
5. Sato M, Nakano M, Sasanuma J, Asari J, Watanabe K : Very late onset of chronic subdural hematoma. Case report. *Neurol Med Chir (Tokyo)* 45 : 41-43, 2005
6. Timsit S, Logak M, Manai R, Rancurel G : Evolving isolated hand palsy : a parietal lobe syndrome associated with carotid artery disease. *Brain* 120 (Pt 12) : 2251-2257, 1997