

Comparison of Absorbable Mesh Plate versus Titanium-Dynamic Mesh Plate in Reconstruction of Blow-Out Fracture: An Analysis of Long-Term Outcomes

Woon Il Baek, Han Koo Kim, Woo Seob Kim, Tae Hui Bae

Department of Plastic and Reconstructive Surgery, Chung-Ang University Hospital, Chung-Ang University College of Medicine, Seoul, Korea

Background A blow-out fracture is one of the most common facial injuries in midface trauma. Orbital wall reconstruction is extremely important because it can cause various functional and aesthetic sequelae. Although many materials are available, there are no uniformly accepted guidelines regarding material selection for orbital wall reconstruction.

Methods From January 2007 to August 2012, a total of 78 patients with blow-out fractures were analyzed. 36 patients received absorbable mesh plates, and 42 patients received titanium-dynamic mesh plates. Both groups were retrospectively evaluated for therapeutic efficacy and safety according to the incidence of three different complications: enophthalmos, extraocular movement impairment, and diplopia.

Results For all groups (inferior wall fracture group, medial wall fracture group, and combined inferomedial wall fracture group), there were improvements in the incidence of each complication regardless of implant types. Moreover, a significant improvement of enophthalmos occurred for both types of implants in group 1 (inferior wall fracture group). However, we found no statistically significant differences of efficacy or complication rate in every groups between both implant types.

Conclusions Both types of implants showed good results without significant differences in long-term follow up, even though we expected the higher recurrent enophthalmos rate in patients with absorbable plate. In conclusion, both types seem to be equally effective and safe for orbital wall reconstruction. In particular, both implant types significantly improve the incidence of enophthalmos in cases of inferior orbital wall fractures.

Keywords Orbital fractures / Orbital implants / Absorbable implants / Titanium

Correspondence: Han Koo Kim
Department of Plastic and Reconstructive Surgery, Chung-Ang University Hospital, Chung-Ang University College of Medicine, 102 Heuksuk-ro, Dongjak-gu, Seoul 156-755, Korea
Tel: +82-2-6299-1615
Fax: +82-2-825-9880
E-mail: hkkim@cau.ac.kr

No potential conflict of interest relevant to this article was reported.

Received: 12 Feb 2014 • Revised: 31 Mar 2014 • Accepted: 1 Apr 2014

pISSN: 2234-6163 • eISSN: 2234-6171 • <http://dx.doi.org/10.5999/aps.2014.41.4.355> • Arch Plast Surg 2014;41:355-361

INTRODUCTION

Orbital wall fractures, especially medial orbital fractures and inferior orbital fractures, are among the most common facial injuries

in patients with midface trauma [1]. These injuries can lead to various functional and aesthetic complications later on, such as enophthalmos, extraocular movement impairment, and diplopia. Diagnosing these types of traumas has been difficult in the

past, so the diagnosis rate has been low. With the development of new diagnostic modalities, it is now relatively easy to diagnose and confirm orbital wall fractures [2-5]. Accordingly, orbital fracture reconstruction has become a common procedure for plastic surgeons to perform. The goals of blow-out fracture reconstruction are to free incarcerated soft tissue from the orbital wall defect and to span the defect with an implant to restore correct anatomy and return the orbital space to its pre-trauma volume [6]. Consequently, inserted implants play a crucial role in restoring the functional and normal anatomic structure of the orbital cavity.

Three types of materials are available for orbital wall reconstruction: autologous, allogenic, or alloplastic materials. Autologous materials include periosteum [7], nasoseptal cartilage [8], rib bone [9], and mandibular bone. Allogenic materials are either lyophilized dura [10] or lyophilized cartilage. Alloplastic materials can be further subdivided into absorbable mesh plates and non-absorbable titanium-dynamic mesh plates.

The purpose of this study is to compare the long-term effectiveness and injury-related complications associated with either absorbable mesh plate or titanium-dynamic mesh plate implantation in terms of isolated inferior orbital wall fracture, isolated medial orbital wall fracture, and the combined inferomedial orbital wall fracture.

METHODS

Study design

We performed a retrospective analysis of long-term follow-up patients with blow-out fractures from January 2007 to August 2012 in the Department of Plastic and Reconstructive Surgery at Chung-Ang University Hospital. The total number of enrolled patients was 78. We defined long-term follow-up as at least 12 months; the range of follow-up period in the study sample was 12 to 81 months. To ensure accurate diagnosis, patients routinely underwent preoperative axial, coronal, sagittal plane, and 3-dimensional computed tomography (CT) imaging, in addition to plane radiographs and physical examination.

Indications for surgical intervention included significant enophthalmos (> 2 mm), extraocular movement impairment, persistent diplopia, and large defect size (> 2.5 cm²). All of the enrolled patients showed complete reduction of herniated periorbital tissue on postoperative CT. Patients with complicated orbital wall fractures, such as zygomaticomaxillary fractures, and blind patients who could not experience diplopia were excluded.

We categorized the final 78 enrolled patients into 3 groups: group 1 (isolated inferior orbital wall fractures) = 34 patients, group 2 (isolated medial orbital wall fractures) = 27 patients,

and group 3 (inferomedial orbital wall combined fractures) = 17 patients.

Surgical procedures

All surgical procedures were performed with the patient under general anesthesia. Regardless of fracture site, we used the subciliary muscle-splitting incision approach for all surgeries. Once we reached the fracture site, we shaped the mesh plate by cutting with scissors and molding it to fit the patient's anatomical shape.

For inserted molding materials, we used either an absorbable 85:15 poly (L-lactide-co-glycolide) mesh plate (RAPIDSORB Rapid Resorbable Fixation System, Synthes, Oberdorf, Switzerland) or a titanium-dynamic mesh plate (MatrixMIDFACE Orbital plates, Synthes). We placed the mesh plate 0.5 cm posterior to the orbital rim so that it would not be palpable; we fixed it with at least two screws to prevent implant displacement.

Surgeries were completed with a skin closure and confirmation of periorbital soft tissue release with the forced duction test. Postoperatively, we evaluated the patients' physical appearance and checked for the presence of enophthalmos, extraocular movement impairment, or diplopia.

Long-term evaluation

The mean follow-up period was 25.4 ± 22.5 months after surgery with absorbable mesh plate, and 32.5 ± 25.2 months after surgery with titanium-dynamic mesh plate. To determine surgical effectiveness, over the course of long-term follow-up, we checked for the existence of postoperative enophthalmos (> 2 mm), sustained extraocular movement impairment, and persistent diplopia.

Statistical analyses

All results are expressed as mean \pm standard deviation. Data analyses were conducted in SPSS ver. 19 (IBM Corp. Armonk, NY, USA). Statistical tests include the chi-square test, Fisher's exact test, and McNemar's test. A P-value < 0.05 was considered statistically significant.

RESULTS

Among the 78 patients in our study, the proportion of patients receiving either the absorbable mesh plate or the titanium-dynamic mesh plate varied by fracture group. In group 1, 15 patients received absorbable mesh plates (19.2%) and 19 received titanium-dynamic mesh plates (24.4%). In group 2, 14 patients received absorbable mesh plates (17.9%) and 13 received titanium-dynamic mesh plates (16.7%). In group 3, 7 patients received absorbable mesh plates (9.0%) and 10 received titanium-

dynamic mesh plates (12.8%). In total, absorbable mesh plates were used in 36 patients (46.1%) and titanium-dynamic mesh plates were used in 42 patients (53.8%).

The mean ages for each implant group were 31.9 ± 14.9 and 29.4 ± 12.2 , respectively, with no statistically significant difference between them ($P=0.53$). Among patients who received absorbable mesh plates, 31 were male (86.1%) and 5 were female (13.9%). Similarly, 38 male patients (90.5%) and 4 female patients (9.5%) received titanium-dynamic mesh plates; showing a male dominance in both groups. However, the gender differences were not significant ($P=0.12$). The mean follow-up periods (25.4 ± 22.5 months for the absorbable mesh plate group and 32.5 ± 25.2 months for the titanium-dynamic mesh plate group) were also not significantly different between the groups ($P=0.33$) (Table 1).

Group 1 (inferior wall)

Among the 15 patients who received absorbable mesh plates, preoperative enophthalmos was found in 8 patients (53.3%), extraocular movement impairment was found in 2 patients (13.3%), and diplopia was found in 3 patients (20.0%). After long-term follow-up, 3 patients (20.0%) still had postoperative enophthalmos, none of the patients presented with postoperative extraocular movement impairment, and 1 patient (6.7%) still had postoperative diplopia.

Characteristic	Absorbable mesh plate (%)	Titanium-dynamic mesh plate (%)	P-value
Group 1 (inferior)	15 (19.2)	19 (24.4)	-
Group 2 (medial)	14 (17.9)	13 (16.7)	-
Group 3 (combined)	7 (9.0)	10 (12.8)	-
Total number	36 (46.1)	42 (53.8)	-
Age (yr)	31.9 ± 14.9	29.4 ± 12.2	0.53
Gender (M:F)	31:5	38:4	0.12
Follow-up (mo)	25.4 ± 22.5	32.5 ± 25.2	0.33

Group 1 (inferior)	Preoperative (%)	Postoperative (%)
Absorbable mesh plate (15)		
Enophthalmos	8 (53.3)	3 (20.0)
EOM impairment	2 (13.3)	0
Diplopia	3 (20.0)	1 (6.7)
Titanium-dynamic mesh plate (19)		
Enophthalmos	11 (57.9)	1 (5.3)
EOM impairment	3 (15.8)	0
Diplopia	3 (15.8)	1 (5.3)

EOM, extraocular movement.

Among the 19 patients in fracture group 1 who received titanium-dynamic mesh plates, 11 patients (57.9%), 3 patients (15.8%), and 3 patients (15.8%) presented with preoperative enophthalmos, extraocular movement impairment, and diplopia, respectively. After long-term follow-up, 1 patient (5.3%) still had postoperative enophthalmos. Extraocular movement impairment was fully resolved in all patients, and 1 patient (5.3%) still had diplopia in his upper gaze (Table 2).

Group 2 (medial wall)

Among the 14 patients in fracture group 2 who received absorbable mesh plates, there were 2 patients (14.3%) with enophthalmos, 2 patients (14.3%) with extraocular movement impairment, and 3 patients (21.4%) with diplopia, preoperatively. After surgical reduction and long-term follow-up, 1 patient (7.1%) still had postoperative enophthalmos, and none of the patients presented with postoperative extraocular movement impairment or clinically detectable diplopia.

Among the 13 patients who received titanium-dynamic mesh plate, 1 patient (7.7%) had enophthalmos and 2 patients (15.4%) had extraocular movement impairment preoperatively, all of which resolved during the follow-up period. Preoperative diplopia was detected in 3 patients (23.1%), and 1 patient (7.7%) had sustained postoperative diplopia during extreme lateral gaze (Table 3).

Group 3 (combined inferomedial wall)

Among the 7 patients who received an absorbable mesh plate, preoperative enophthalmos was found in 4 patients (57.1%). After long-term follow-up, 2 patients (28.6%) still had postoperative enophthalmos. One patient (14.3%) had preoperative extraocular movement impairment, and 2 patients (28.6%) had preoperative diplopia, all of which were resolved after surgical repair.

Among the 10 patients who received titanium-dynamic mesh plates, 5 patients (50.0%) presented with preoperative enophthalmos, 2 patients (20.0%) had symptoms of the preoperative

Group 2 (medial)	Preoperative (%)	Postoperative (%)
Absorbable mesh plate (14)		
Enophthalmos	2 (14.3)	1 (7.1)
EOM impairment	2 (14.3)	0
Diplopia	3 (21.4)	0
Titanium-dynamic mesh plate (13)		
Enophthalmos	1 (7.7)	0
EOM impairment	2 (15.4)	0
Diplopia	3 (23.1)	1 (7.7)

EOM, extraocular movement.

Table 4. Preoperative and postoperative complications between two implant types in group 3

Group 3 (combined)	Preoperative (%)	Postoperative (%)
Absorbable mesh plate (7)		
Enophthalmos	4 (57.1)	2 (28.6)
EOM impairment	1 (14.3)	0
Diplopia	2 (28.6)	0
Titanium-dynamic mesh plate (10)		
Enophthalmos	5 (50.0)	1 (10.0)
EOM impairment	2 (20.0)	1 (10.0)
Diplopia	3 (30.0)	1 (10.0)

EOM, extraocular movement.

extraocular movement impairment, and 3 patients (30.0%) had preoperative diplopia. After long-term follow-up, 1 patient (10.0%) had postoperative enophthalmos, 1 patient (10.0%) had extraocular movement impairment, and 1 patient (10.0%) still had diplopia (Table 4).

Comparative analysis

In every fracture group, the results of all chi-square tests and Fisher's exact tests indicated that there was no significant difference between the absorbable mesh plate and titanium-dynamic mesh plate with respect to the preoperative incidence of enophthalmos, extraocular movement impairment, or diplopia. The preoperative defect size of each group, measured by 3-dimensional computed tomography, were $2.72 \pm 0.21 \text{ cm}^2$ in group 1, $2.67 \pm 0.14 \text{ cm}^2$ in group 2, and $2.81 \pm 0.20 \text{ cm}^2$ in group 3, without statistically significant difference, too ($P = 0.65$).

After surgical repair, there were improvements in each complication in every group (group 1, 2, and 3). Among them, however, enophthalmos in group 1 showed statistical significance only, regardless of implant types.

In group 1, the difference in preoperative and postoperative incidence of enophthalmos was 8 to 3 patients ($P = 0.03$) for the absorbable mesh plate group and 11 to 1 patient ($P = 0.002$) for the titanium-dynamic mesh plate group, respectively (Fig. 1); these differences mark statistically significant improvements in enophthalmos incidence for both implants. In group 2 and 3, although there were also improvements in incidence of enophthalmos in both implants, the result was not statistically significant.

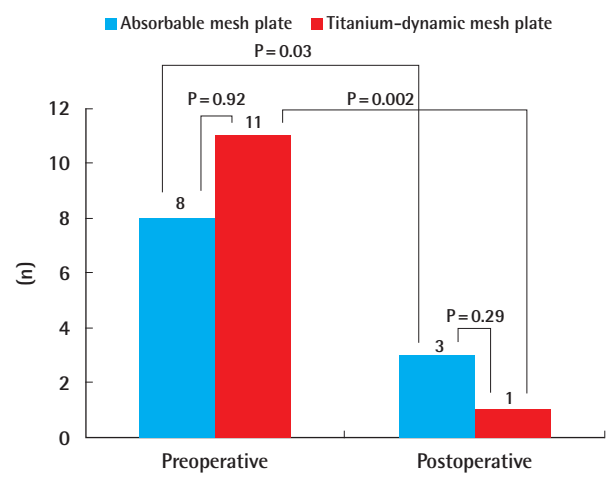
Comparing extraocular movement impairment and diplopia, even though the incidences decreased in every groups, the improvements were not statistically significant either.

DISCUSSION

The orbital wall is one of the most frequently damaged parts of the maxillofacial skeleton after midfacial trauma. Regardless of

Fig. 1. Difference of enophthalmos incidence in group 1

Significant improvements in enophthalmos are observable after surgical repair in both implant types within group 1 ($P < 0.05$). However, both implant types showed no significant difference between themselves.



the fracture site, blow-out fractures can cause various functional and aesthetic sequelae. Preventing these complications from becoming long-term problems is very important, and it depends strongly on the materials used for bridging the orbital wall defects [11].

The prerequisites of an ideal material are good biocompatibility, easy to manipulate, and strong mechanical strength to support the orbital structure [12-15]. Remarkably, however, there are no uniformly accepted guidelines for selecting material for orbital reconstruction [16].

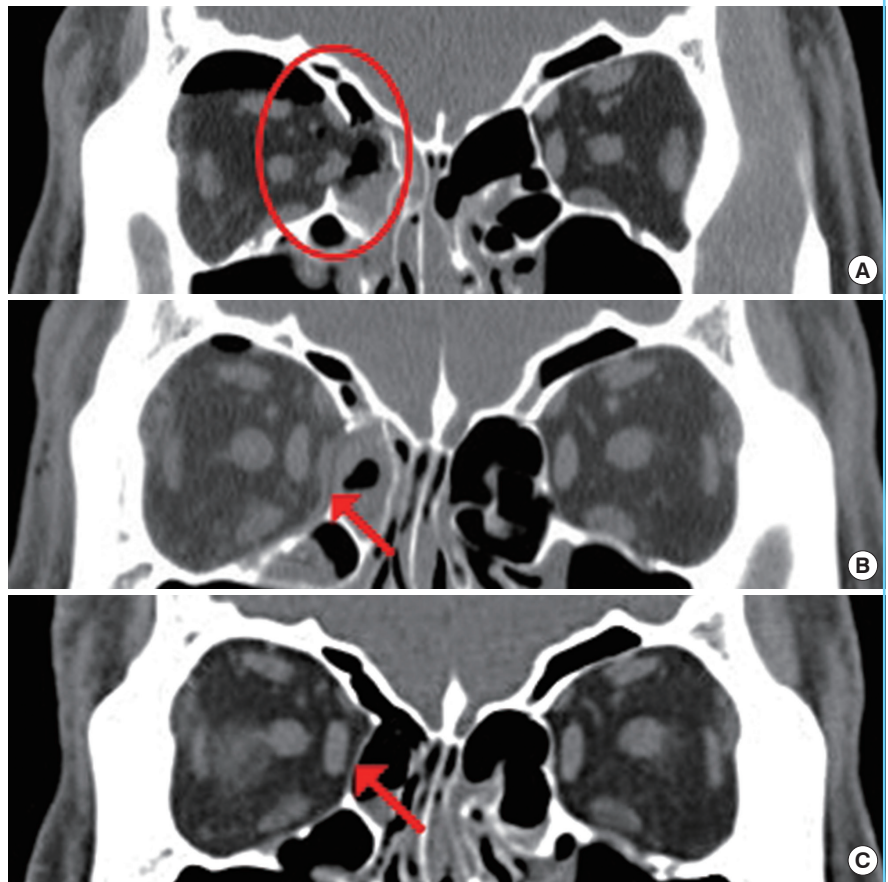
Various materials have been introduced for orbital wall reconstruction, each with its own advantages and disadvantages. Autologous materials, including periosteum [7], nasoseptal cartilage [8], rib bone [9], and calvarium, have the advantages of resistance to infection, incorporation by the host into new bone, lack of host response against the graft, and little concern for late extrusion [17]. Autologous materials also have several disadvantages, including high risk of nerve and blood vessel injury, donor site morbidity, cosmetic disturbance, and an unpredictable degree of absorption [18,19].

Allogenic materials, such as lyophilized dura and lyophilized cartilage, showed good results during postoperative follow-up in some studies; however, it should not be used any more due to the risk of slow viral infections [20].

Recently, alloplastic materials have become the most widely used materials. Alloplastic materials are subdivided into absorbable and non-absorbable mesh plates. Some surgeons prefer absorbable mesh plates due to their ease of use and complete resorption, leaving no foreign material in human body [17]. How-

Fig. 2. Coronal image of 3-dimensional computed tomography

(A) Preoperative view of medial wall defect. Note on the herniated soft tissue through lamina papyracea (red circle). (B) Immediate postoperative view. Note on the absorbable plate and well-reduced soft tissue (red arrow). (C) 13 months after orbital wall reconstruction, the absorbable plate was fully resorbed, and the fibrous tissue substituted the medial orbital wall (red arrow).



ever, some studies have reported that the connective tissues around the absorbable mesh plate cannot replace the original bony structures completely after the thorough resorption of the plate, mainly in the center of the defect, which may result in progressive enophthalmos [21]. Also, replacement by fibrosis may not support the orbital structure and can lead to persistent enophthalmos [22].

Titanium-dynamic mesh plates have also been used widely for various craniofacial fractures and are known to be biocompatible. It can be adopted to complex structures easily, and it can also be cut to shape as well [16]. However titanium plates are permanent foreign bodies. Several late-onset complications related to the titanium-dynamic mesh plate have been reported, such as infection, extrusion, implant migration, residual diplopia, etc. [23]. Therefore, choosing an appropriate material to reconstruct the orbital wall remains difficult and controversial.

Recently, various absorbable materials with different degradation rates are introduced. The degradation rate depends on the proportion of monomers. According to some literatures and data about 85:15 poly (L-lactide-co-glycolide) mesh plate (RAPIDSORB Rapid Resorbable Fixation System, Synthes,

Oberdorf, Switzerland) in our study, it readily resorbs within 12 months. Therefore, we supposed at least 12 months as a long-term follow up. Moreover, we also found full absorption of the plate by 3-dimensional computed tomography during the long-term follow up (Fig. 2).

In our study, the preoperative incidence of enophthalmos was higher in group 1 than in the other groups, and regardless of implant type, most enophthalmos cases were relatively well corrected after orbital wall reconstruction. The reason of high incidence of preoperative enophthalmos for inferior orbital wall fracture cases, we suspect, might be due to the weight and increased tension of the globe to the orbital wall, especially the inferior orbital wall. The internal orbital contents include the weight of the globe, the extraocular musculature, orbital fat, neurovascular structures, the lacrimal apparatus, and even the musculocutaneous lids. According to the literature, the mean weight of the combined contents of the exenterated orbit, including the structures mentioned above, was found to be 42.97 ± 4.05 g, with a range of 37.80 to 51.03 g [24]. The normal direct orbital tension is 4 mm Hg, and the direct orbital tension after reconstruction of an orbital floor fracture usually in-

creases to about 9.3 ± 3.1 mm Hg [25]. These factors might explain the high incidence of preoperative enophthalmos in group 1 (inferior wall).

These factors also might be the reason of higher recurrence rate of enophthalmos after orbital wall reconstruction in the absorbable mesh plate group compared to the titanium-dynamic mesh plate group. According to the results of our retrospective study, besides the obvious improvements in each complication type in every group (groups 1, 2, and 3) after orbital wall reconstruction, there was an overall tendency toward a lower recurrence rate of enophthalmos in titanium-dynamic mesh plate recipients than in those who received an absorbable mesh plate as well; however, in long-term follow-up, the difference was not significant.

The significant difference in our study was the dramatic decrease of enophthalmos incidence among the patients in group 1 after reconstruction, for both implant types. Furthermore, although the results from group 3 (combined wall) showed no statistically significant differences in our study, some similar results are expected with a study of large number of patients, because these injuries might lead to even larger orbital wall defects than isolated inferior orbital wall fractures do; which can cause higher incidence of preoperative enophthalmos.

Among the postoperative complicated patients, there was no patient who consistently complained of the problems, except for only one patient with persistent diplopia in group 2. The patient had underwent medial orbital wall reconstruction with titanium-dynamic mesh plate and complained of postoperative diplopia. However, we did not undergo reoperation, because the patient was accompanied with objective restriction beyond 40 degrees of abduction from primary gaze, which means there was no diplopia in usual life except for extreme lateral gaze. Finally, we had no patient who had severe problem which required reoperation, fortunately.

A shortcoming of this study is the small number of patients in each group, especially in group 3 (combined wall). As we continue to collect more medical data over several more years, we will have more statistical power to identify more significant differences.

Finally, our study does not suggest that one or the other of these implants is the best option for reconstructing orbital anatomy after blow-out fractures. Even though we expected the significantly higher recurrent enophthalmos rate in patients with absorbable plate through complete absorption, both types showed good results without significant differences in long-term follow up. We can use both types of implants safely. Regarding extraocular movement impairment and diplopia, both implants showed no significant differences either. This results

suggest that other factors, such as surgeon's preference, patients' request, or cost-effectiveness, can also be legitimate deciding points for choosing the implant as well.

In conclusion, both types of implants seem to be equally effective and safe for orbital wall reconstruction, and they are both particularly effective with regard to improving enophthalmos in cases of inferior orbital wall fractures.

REFERENCES

1. Jank S, Emshoff R, Schuchter B, et al. Orbital floor reconstruction with flexible Ethisorb patches: a retrospective long-term follow-up study. *Oral Surg Oral Med Oral Pathol Oral Radiol Endod* 2003;95:16-22.
2. Kim IT, Choi JB. Normal range of exophthalmos values on orbit computerized tomography in Koreans. *Ophthalmologica* 2001;215:156-62.
3. Tanaka T, Morimoto Y, Kito S, et al. Evaluation of coronal CT findings of rare cases of isolated medial orbital wall blow-out fractures. *Dentomaxillofac Radiol* 2003;32:300-3.
4. Caranci F, Cicala D, Cappabianca S, et al. Orbital fractures: role of imaging. *Semin Ultrasound CT MR* 2012;33:385-91.
5. You JP, Kim DW, Jeon BJ, et al. Two-year follow-up on the use of absorbable mesh plates in the treatment of medial orbital wall fractures. *Arch Plast Surg* 2013;40:728-34.
6. Buchel P, Rahal A, Seto I, et al. Reconstruction of orbital floor fracture with polyglactin 910/polydioxanone patch (ethisorb): a retrospective study. *J Oral Maxillofac Surg* 2005;63:646-50.
7. Dost P. Orbital floor reconstruction with autologous periosteum transplant. *Laryngorhinotologie* 1996;75:57-8.
8. Lai A, Gliklich RE, Rubin PA. Repair of orbital blow-out fractures with nasoseptal cartilage. *Laryngoscope* 1998;108:645-50.
9. Johnson PE, Raftopoulos I. In situ splitting of a rib graft for reconstruction of the orbital floor. *Plast Reconstr Surg* 1999;103:1709-11.
10. Guerra MF, Perez JS, Rodriguez-Campo FJ, et al. Reconstruction of orbital fractures with dehydrated human dura mater. *J Oral Maxillofac Surg* 2000;58:1361-6.
11. Gierloff M, Seeck NG, Springer I, et al. Orbital floor reconstruction with resorbable polydioxanone implants. *J Craniofac Surg* 2012;23:161-4.
12. Courtney DJ, Thomas S, Whitfield PH. Isolated orbital blowout fractures: survey and review. *Br J Oral Maxillofac Surg* 2000;38:496-504.
13. Enislidis G. Treatment of orbital fractures: the case for treatment with resorbable materials. *J Oral Maxillofac Surg* 2004;

- 62:869-72.
14. Kontio R. Treatment of orbital fractures: the case for reconstruction with autogenous bone. *J Oral Maxillofac Surg* 2004;62:863-8.
 15. Potter JK, Ellis E. Biomaterials for reconstruction of the internal orbit. *J Oral Maxillofac Surg* 2004;62:1280-97.
 16. Dietz A, Ziegler CM, Dacho A, et al. Effectiveness of a new perforated 0.15 mm poly-p-dioxanon-foil versus titanium-dynamic mesh in reconstruction of the orbital floor. *J Craniomaxillofac Surg* 2001;29:82-8.
 17. Al-Sukhun J, Lindqvist C. A comparative study of 2 implants used to repair inferior orbital wall bony defects: autogenous bone graft versus bioresorbable poly-L/DL-Lactide [P(L/DL)LA 70/30] plate. *J Oral Maxillofac Surg* 2006;64:1038-48.
 18. Banwart JC, Asher MA, Hassanein RS. Iliac crest bone graft harvest donor site morbidity. A statistical evaluation. *Spine (Phila Pa 1976)* 1995;20:1055-60.
 19. Ahlmann E, Patzakis M, Roidis N, et al. Comparison of anterior and posterior iliac crest bone grafts in terms of harvest-site morbidity and functional outcomes. *J Bone Joint Surg Am* 2002;84:716-20.
 20. Takashima S, Tateishi J, Taguchi Y, et al. Creutzfeldt-Jakob disease with florid plaques after cadaveric dural graft in a Japanese woman. *Lancet* 1997;350:865-6.
 21. Merten HA, Luhr HG. Resorbable synthetics (PDS foils) for bridging extensive orbital wall defects in an animal experiment comparison. *Fortschr Kiefer Gesichtschir* 1994;39:186-90.
 22. Tuncer S, Yavuzer R, Kandal S, et al. Reconstruction of traumatic orbital floor fractures with resorbable mesh plate. *J Craniofac Surg* 2007;18:598-605.
 23. Hwang K, Kim DH. Comparison of the supporting strength of a poly-L-lactic acid sheet and porous polyethylene (Medpor) for the reconstruction of orbital floor fractures. *J Craniofac Surg* 2010;21:847-53.
 24. Haug RH, Nuveen E, Bredbenner T. An evaluation of the support provided by common internal orbital reconstruction materials. *J Oral Maxillofac Surg* 1999;57:564-70.
 25. Zhou H, Fan X, Xiao C. Direct orbital manometry in normal and fractured orbits of Chinese patients. *J Oral Maxillofac Surg* 2007;65:2282-7.