

Case Report

Asymptomatic Penetration of the Oculomotor Nerve by a *De Novo* Aneurysm Associated with Severe Atherosclerotic Stenosis of the Supraclinoid Internal Carotid Artery

Hee Sup Shin, M.D., Seung Hwan Lee, M.D., Jun Seok Koh, M.D.

Department of Neurosurgery, Stroke and Neurological Disorders Centre, Kyung Hee University Hospital at Gangdong, Kyung Hee University School of Medicine, Seoul, Korea

A 70-year-old woman presented with headaches and recurrent stroke symptoms. During five years, the patient has been treated for cerebral infarction associated with severe atherosclerotic stenosis of the internal carotid artery. Three-year follow-up magnetic resonance angiography showed a tiny *de novo* aneurysm arising from the distal part of atherosclerotic internal carotid artery. And 5-year follow-up three-dimensional CT angiogram demonstrated a definite aneurysm enlargement as large as requiring treatment. During dissection of aneurysm, the oculomotor nerve was found to be penetrated with the growing *de novo* aneurysm. The authors report a case of a *de novo* aneurysm, which resulted from atherosclerotic stenosis of the internal carotid artery at the supraclinoid portion, that was found to be penetrating the oculomotor nerve with no ocular palsy.

Key Words : Aneurysm · Atherosclerosis · *De novo* · Oculomotor nerve · Penetration.

INTRODUCTION

Cranial nerve splitting and penetration by an intracranial aneurysm has been described in the literature, often with optic apparatus involvement by the ophthalmic artery or anterior communicating artery (ACoM) aneurysm⁵⁾. Penetration of the oculomotor nerve by an intracranial aneurysm is rare and has been reported in only 3 cases elsewhere^{2,4,8)}. *De novo* aneurysm refers the development of a new aneurysm in a location previously observed to be normal by an angiography or direct microsurgical exploration. The main pathophysiology of a *de novo* aneurysm involves changes in the vascular connective tissue resulting from the presence of hemodynamic stress or change after surgery, and rarely, the formation of a defect in the arterial wall associated with atherosclerotic degeneration could be a causative factor⁶⁾. Herein, we present an unusual case of penetration of the oculomotor nerve due to evolution of a *de novo* aneu-

rysm associated with atherosclerotic stenosis of the internal carotid artery (ICA) at the supraclinoid portion.

CASE REPORT

A 70-year-old female presented with a relapsing headache and recurrent right-sided clumsiness related to an intracranial atherosclerosis and hypertension. Stroke symptoms have been bothering her since 5 years prior, and she was medicated with a dual antiplatelet and antihypertensive regimen indefinitely. A brain magnetic resonance (MR) image and MR angiogram (Fig. 1A) in 2006 showed a small infarction in the left periventricular white matter and severe atherosclerotic stenosis of the left ICA at the supraclinoid portion. A three-year follow-up MR angiogram (Fig. 1B) in 2009 revealed a tiny aneurysm in the distal part of the atherosclerotic ICA. This aneurysm was thought to be a *de novo* one associated with severe atherosclerotic stenosis

• Received : November 1, 2013 • Revised : February 14, 2014 • Accepted : September 15, 2014

• Address for reprints : Seung Hwan Lee, M.D.

Department of Neurosurgery, Stroke and Neurological Disorders Centre, Kyung Hee University Hospital at Gangdong, Kyung Hee University School of Medicine, 892 Dongnam-ro, Gangdong-gu, Seoul 134-727, Korea

Tel : +82-2-440-6286, Fax : +82-2-440-8404, E-mail : toast2000@hanmail.net

• This is an Open Access article distributed under the terms of the Creative Commons Attribution Non-Commercial License (<http://creativecommons.org/licenses/by-nc/3.0>) which permits unrestricted non-commercial use, distribution, and reproduction in any medium, provided the original work is properly cited.

of the ICA and was observed without treatment mainly due to its small size. However, a two-year follow-up three-dimensional (3D) CT angiogram showed a definite aneurysm enlargement, and thus, a transfemoral cerebral angiogram was strongly recommended to the patient. Digital subtraction angiogram (Fig. 1C) and reconstruction of 3D rotational angiogram demonstrated a 6 mm-sized, elongated aneurysm arising from the posterior communicating segment of the atherosclerotic ICA. Surgical intervention, rather than endovascular treatment, was chosen for treatment. A pterional craniotomy was performed, and the aneurysm was found and finally exposed after partial removal of the anterior clinoid process due to the low-lying nature of the aneurysm and tortuousness of the supraclinoid ICA. During neck clipping, the aneurysm was observed with the dome projecting posterolaterally into and penetrating the oculomotor nerve, and neither posterior communicating artery (PCoMA) nor its remnant was confirmed. After careful neck dissection, the aneurysm clip was placed. The dome of the aneurysm was embedded within the oculomotor nerve (Fig. 1E) but left untouched to prevent any unnecessary injury. The patient tolerated clipping well and was discharged with no postoperative neurologic deficits.

DISCUSSION

Hemodynamic changes have been regarded as one of the main reasons for *de novo* aneurysm. Agenesis or hypoplasia of the ICA, as well as therapeutic occlusion, is known to promote hemodynamic stress and subsequent aneurysm development frequently in the ACoMA or in the contralateral ICA⁶. Few patients exist in whom atherosclerotic stenosis or occlusion has been considered related to *de novo* aneurysm. Atherosclerosis induces degenerative breakdown of the vascular wall and promotes the formation of fibrous atheroma and resultant luminal stenosis. The narrowed ICA lumen by atherosclerotic plaques might provoke the weakening of the flow and subsequent turbulent effects, resulting in large variations in the wall shear stress that lead to the formation of *de novo* aneurysms⁶.

Oculomotor nerve palsy is one of the presenting signs of an internal carotid (IC) PComA aneurysm. Local compression of the oculomotor nerve during IC-PCoMA aneurysm enlargement is usual, and the fundus of the aneurysm can sometimes adhere to the nerve. However, splitting and penetration of the oculomotor nerve is rare (Table 1)^{2,4,8}. The

intracranial oculomotor nerve is divided into proximal (interpeduncular), middle, and distal (intracavernous) parts. Cahill et al.³ confirmed that the proximal part of the oculomotor nerve was frequently penetrated by thalamoperforating arteries and branches of brainstem vessels, but the middle part (from the point where the oculomotor nerve exits the interpeduncular cistern to where the nerve enters the cavernous sinus) usually did not have any penetration by extraneural vessels. Three explanations for a penetrated cranial nerve by intracranial aneurysm were proposed by Beatty¹: 1) the aneurysm enlarging along congenital splitting of the nerve, 2) the aneurysm originating from a vessel already penetrating the nerve, and 3) the aneurysm actually penetrating the nerve.

In the present case, several notable findings were given: 1) with no doubt a *de novo* aneurysm had developed and enlarged over at least a 5-year period associated with symptomatic atherosclerotic stenosis of the ICA; 2) this *de novo* aneurysm was relatively low-lying compared to usual IC-PCoMA aneurysms, and no PCoMA or its remnant were noted; and 3) neither congenital nerve splitting related to the aberrant vessels nor prior subtle subarachnoid leakage was observed intraoperatively and clinically. Given that the described oculomotor nerve anatomy which is relevant to neurovascular relationship and there was confirmation of no PCoMA during surgery, there is little possibility of congenital oculomotor nerve splitting by intracranial vessels. Instead, we theorize that initially the atherosclerotic ICA was in close contact with the very distal portion of the middle part of the oculomotor nerve, just before entering the cavernous

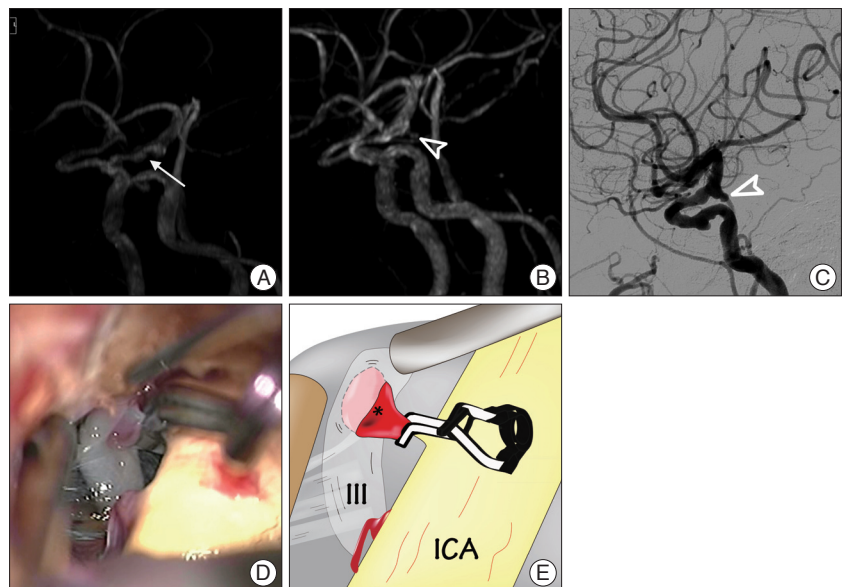


Fig. 1. Brain magnetic resonance (MR) angiogram (A) in 2006 showing a severe atherosclerotic stenosis of the internal carotid artery (ICA) at the supraclinoid portion (arrow). Three-year follow-up MR angiogram (B) in 2009 revealing a tiny *de novo* aneurysm (open arrowhead) in the distal part of the ICA. Subtracted lateral view (C) angiogram in 2011 demonstrating a wide necked, elongated shape aneurysm (open arrowhead) in the communicating segment of atherosclerotic ICA. Intraoperative photographs during clip placement (D) and illustration (E) showing the aneurysm, which is proximal to the anterior choroidal artery, projecting posterolaterally and penetrating into the oculomotor nerve. III : oculomotor nerve, asterisk : aneurysm.

Table 1. Summary for previously published cases of oculomotor nerve penetration by intracranial aneurysms

Series	Age/sex	Presentation	CN III-traversing structure/ proposed mechanism	Surgery	Postoperative deficits
Yaşargil, ⁸⁾ 1984	NM	NM (no CNP III)	Rt. IC-PCoM A An/NM	Neck clipping and fundus resection	NM
Horiuchi et al., ⁴⁾ 1997	48/F	Headache, Rt. CNP III (diplopia 10 Y ago, Lt. MCA ruptured An clipping 20 Y ago)	Rt. IC-PCoM A An/rent by de novo An subtle leak and enlargement	CN III partial sacrifice and neck clipping	CNP III (severe and permanent)
Binning and Couldwell, ³⁾ 2009	63/M	Subarachnoid hemorrhage (no CNP III)	Rt. duplicated PCA & PCA An/gap by aberrant vessels and An formation	CN III freeing up and neck clipping	CNP III (partial and transient)
Present case, 2014	70/F	Headache, recurrent CBI, enlarging Lt. distal ICA An (no CNP III)	Lt. supraclinoid ICA An/rent by de novo An evolution a/w atherosclerotic stenosis	Partial ACP resection and neck clipping	No

CNP III : third cranial nerve palsy, CN : cranial nerve, NM : not mentioned, IC-PCoM A An : internal carotid-posterior communicating artery aneurysm, Y : year, MCA : middle cerebral artery, PCA : posterior cerebral artery, CBI : cerebral infarction, a/w : associated with, ACP : anterior clinoid process, AN : aneurysm, ICA : internal carotid artery

sinus, which is less movable and in a relatively fixed area. Subsequently, a *de novo* aneurysm associated with atherosclerotic stenosis of the ICA may have made a rent on the nerve bundles after close contact over a long period rather than compressing or displacing the oculomotor nerve, as is the usual case.

As for the absence of cranial nerve symptom in a *de novo* fenestration, Wang et al.⁷⁾ theorized that with a gradual parting of the nerve to its fiber, while the stretch is within physiological limits, nerve integrity could remain in no disruption. The absence of ocular symptoms in the described case was considered to be in line with Wang's theory. For the best outcomes with operative treatment in this unfamiliar condition, where already the oculomotor nerve is traumatically pierced and penetrated by the pulsatile aneurysm, every effort to preserve the nerve function should be made by avoiding any unnecessary manipulation around the aneurysm dome that is embedded between the nerve bundles in jeopardy^{2,4)}.

CONCLUSION

Herein, the authors present a case of a *de novo* aneurysm, which resulted from atherosclerotic stenosis of the supraclinoid ICA that was found to be penetrating the oculomotor nerve with no ocular palsy. Close and careful radiologic follow-up over a

long period in patients with intracranial atherosclerotic stenosis might be justified regardless of symptoms to verify the possibility of *de novo* aneurysm.

References

1. Beatty RA : Splitting of the optic nerve by a carotid-ophthalmic artery aneurysm. Case report. *J Neurosurg* 65 : 560-562, 1986
2. Binning MJ, Couldwell WT : Fenestration of the oculomotor nerve by a duplicated posterior cerebral artery and aneurysm. Case report. *J Neurosurg* 111 : 84-86, 2009
3. Cahill M, Bannigan J, Eustace P : Anatomy of the extraneural blood supply to the intracranial oculomotor nerve. *Br J Ophthalmol* 80 : 177-181, 1996
4. Horiuchi T, Kyoshima K, Oya F, Kobayashi S : Fenestrated oculomotor nerve caused by internal carotid-posterior communicating artery aneurysm : case report. *Neurosurgery* 40 : 397-398; discussion 398-399, 1997
5. Lee SH, Koh JS, Lee CY, Kwon GY, Ryu CW : Penetration and splitting of the optic apparatus by intrasaccular coils within an anterior communicating artery aneurysm. *Clin Neurol Neurosurg* 113 : 578-581, 2011
6. Sámano A, Ishikawa T, Moroi J, Yamashita S, Suzuki A, Yasui N : Ruptured de novo posterior communicating artery aneurysm associated with arteriosclerotic stenosis of the internal carotid artery at the supraclinoid portion. *Surg Neurol Int* 2 : 35, 2011
7. Wang YY, Thani NB, Han TF : Optic nerve penetration by a carotico-ophthalmic artery aneurysm. *J Clin Neurosci* 17 : 931-933, 2010
8. Yaşargil MG : *Microneurosurgery* : in 4 volumes. New York, NY : Thieme Stratton, 1984, Vol 2