



Atypical teratoid rhabdoid brain tumor in an infant with ring chromosome 22

Eun Hae Cho, MD¹, Jae Bok Park, MD², Jin Kyung Kim, MD, PhD³

¹Green Cross Genome, Seoul, Departments of ²Pathology and ³Pediatrics, Catholic University of Daegu School of Medicine, Daegu, Korea

Reports of constitutional ring chromosome 22, r(22) are rare. Individuals with r(22) present similar features as those with the 22q13 deletion syndrome. The instability in the ring chromosome contributes to the development of variable phenotypes. Central nervous system (CNS) atypical teratoid rhabdoid tumors (ATRTs) are rare, highly malignant tumors, primarily occurring in young children below 3 years of age. The majority of ATRT cases display genetic alterations of *SMARCB1* (*INI1/hSNF5*), a tumor suppressor gene located on 22q11.2. The coexistence of a CNS ATRT in a child with a r(22) is rare. We present a case of a 4-month-old boy with 46,XY,r(22)(p13q13.3), generalized hypotonia and delayed development. High-resolution microarray analysis revealed a 3.5-Mb deletion at 22q13.31q13.33. At 11 months, the patient had an ATRT (5.6 cm×5.0 cm×7.6 cm) in the cerebellar vermis, which was detected in the brain via magnetic resonance imaging.

Key words: Ring chromosome, 22q13.3 Deletion syndrome, Rhabdoid tumor

Corresponding author: Jin Kyung Kim, MD, PhD
Department of Pediatrics, Catholic University of Daegu School of Medicine, 33 Duryugongwon-ro 17-gil, Nam-gu, Daegu 705-718, Korea
Tel: +82-53-650-4240
Fax: +82-53-622-4240
E-mail: kimjk@cu.ac.kr

Received: 16 November, 2013

Revised: 4 April, 2014

Accepted: 8 May, 2014

Introduction

Reports of constitutional ring chromosome 22, r(22) are rare. The majority of cases with r(22) are formed *de novo*, but there are a few reports of familial transmission¹. A breakpoint resulting in the loss of the short arm and satellite material has few clinical consequences, whereas a breakpoint on the long arm, which can vary in size, can affect phenotypic expression depending on the size of the deletion². Individuals with r(22) present with most features common to 22q13 deletion syndrome^{2,3}. The phenotypes of individuals with r(22) can further be affected by the continuously evolving mosaicism, caused by the mitotic instability of the ring chromosome. Sister chromatid exchanges during mitosis can lead to the formation of dicentric or interlocked rings and subsequent aneuploidy or rearrangements within the chromosome^{4,5}. However, mitotic instability in r(22) is a rare occurrence^{2,3}. Central nervous system (CNS) atypical teratoid/rhabdoid tumors (ATRT) are rare, highly malignant tumors primarily occurring in young children under 3 years of age. The majority of ATRT cases display genetic alterations of *SMARCB1* (*INI1/hSNF5*), a tumor suppressor gene located on 22q11.2, resulting in loss of INI1 protein. INI1 protein is ubiquitously expressed in the nuclei of all normal cells and can be identified using immunohistochemistry. Subsequent loss of INI1 protein expression comprises a relatively specific and sensitive diagnostic marker for ATRT⁶.

Here we present a 4 month-old-boy with 46,XY,r(22)(p13q13.3). High-resolution microarray analysis revealed a 3.5-Mb deletion at 22q13.31q13.33. At 11 months of age, an ATRT in the cerebellar vermis was detected after brain magnetic resonance imaging (MRI). To our knowledge, this is the first reported case of a patient with an ATRT and r(22) in Korea.

Copyright © 2014 by The Korean Pediatric Society

This is an open-access article distributed under the terms of the Creative Commons Attribution Non-Commercial License (<http://creativecommons.org/licenses/by-nc/3.0/>) which permits unrestricted non-commercial use, distribution, and reproduction in any medium, provided the original work is properly cited.

Case report

A 4-month-old boy was referred to Department of Pediatrics, Daegu Catholic University of Medicine Center because of delayed development. He was the first child of healthy, unrelated Korean parents without any known disorders in their family histories. The mother was 22 years old and the father was 27 years old at the patient's birth. The pregnancy was uneventful with no evidence of teratogenic agent exposure. The patient was born at 37 weeks of gestational age by uncomplicated spontaneous vaginal delivery, and he weighed 2,500 g. The physical examination revealed unremarkable findings, except generalized hypotonia with decreased deep tendon reflexes of both knee joint was found. Primitive reflexes could not be elicited. He could not maintain his head well a majority of the time. The patient weighed 7.4 kg (50th percentile), and was 65 cm tall (50th percentile). Results of the brain and abdominal ultrasound and the echocardiography revealed nonspecific findings. Cytogenetic analysis on peripheral blood lymphocytes revealed an r(22) in all analyzed cells, specifically 46,XY,r(22)(p13q13.3) (Fig. 1). To specify the breakpoint, high-resolution microarray analysis was performed. Upon analyses of the genomic DNA using an Affymetrix Cytoscan 750K array analysis (Santa Clara, CA, USA), a 3.5-Mb deletion at 22q13.31q13.33 was revealed (Fig 2). However, the *SMARCB1* (*INI1/hSNF5*) gene at 22q11.2, which lies proximal to the break point, was not deleted. Both parents had normal karyotypes. Thus, this chromosomal alteration of the proband was possibly de novo. At 11 months

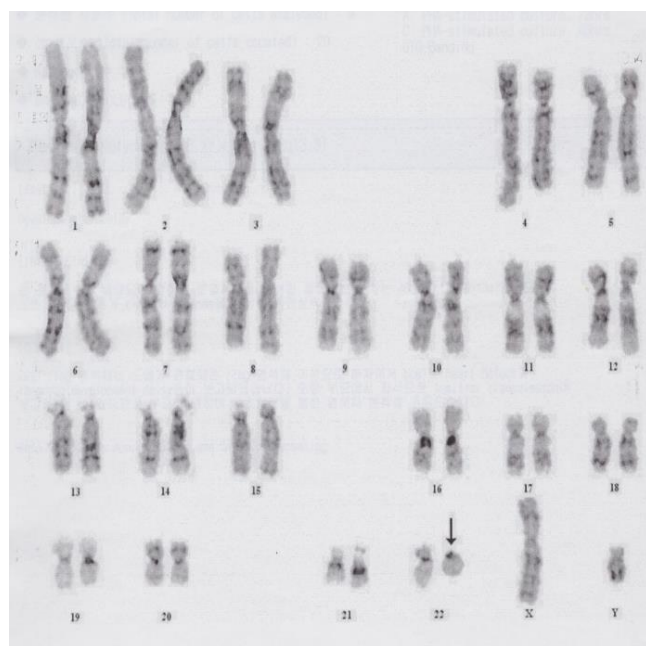


Fig. 1. Karyotype of the described patient. The arrow indicates the ring chromosome 22.

of age, the patient was brought to the Emergency Department with altered consciousness after falling out of his bed at home. Results of brain MRI revealed a 5.6-cm×5.0-cm×7.6-cm mass in the cerebellar vermis (Fig. 3). Results of the abdominal MRI

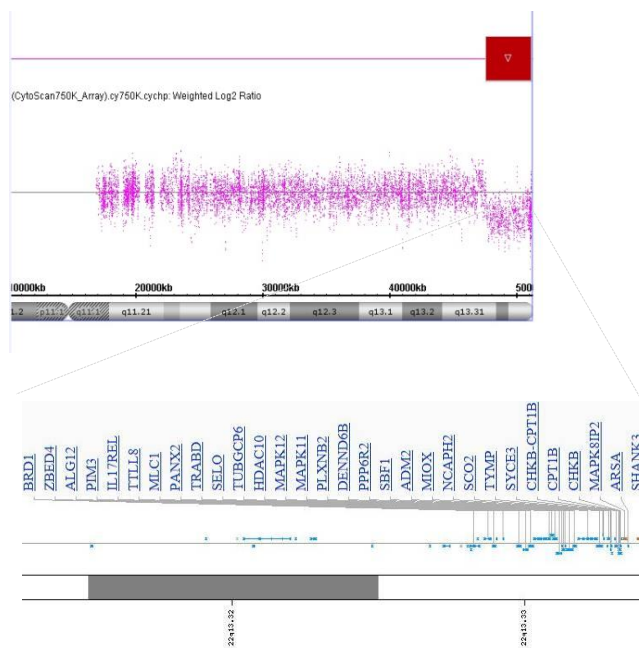


Fig. 2. Physical map of the Xq13-qterminal region: High-resolution microarray analysis revealed a 3.5-Mb deletion at 22q13.31q13.33 resulting absence of genes from *LINC00898* to qter.

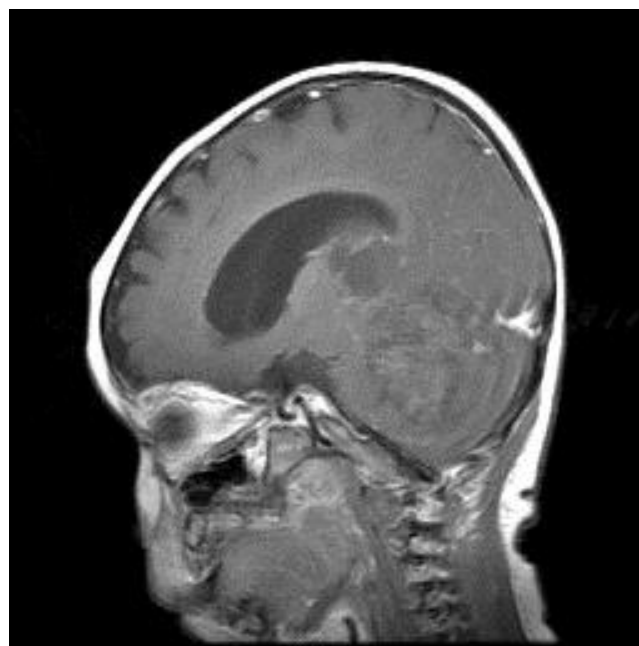

Fig. 3. A contrast-enhanced T1-weighted magnetic resonance image showing a 5.6-cm×5.0-cm×7.6-cm heterogeneous mass with intratumoral hemorrhage in the cerebellar vermis and associated hydrocephalus.

revealed nonspecific findings. The operation was performed via transvermian approach by midline suboccipital craniotomy. The mass, extending the 4th ventricle and the quadrigeminal cistern, was resected. However, it's unfortunate that we obtained small biopsy specimens. On histopathologic examination, most tumor was exclusively composed of small cell component (Fig. 4A). The tumor cells, which had some cytoplasm and vesicular nuclei, were larger than cells of medulloblastoma. The typical rhabdoid tumor cells with eosinophilic cytoplasm were not appeared, and there were no organoid arrangements such as rosette or palisading pattern in the obtained tumor tissue. Immunohistochemical staining for expression of the INI1 protein, showed loss of nuclear expression in the tumor cells (Fig. 4B). After operation, the patient's condition deteriorated with status epilepticus. A ventriculoperitoneal shunt for hydrocephalus underwent in the referred hospital. The chemotherapy (vincristine, cisplatin, doxorubicin, and cyclophosphamide) has been done until now.

Discussion

Ring chromosomes are usually resulted from two terminal breaks in both chromosome arms, followed by fusion of the broken ends, or from the union of one broken chromosome end with the opposite telomere region, leading to the loss of genetic material. They can also be formed by fusion of subtelomeric sequences or telomere-telomere fusion with no deletion⁴. In a ring chromosome, the primary deletion associated with ring formation may be accompanied by a secondary loss or gain of material, and the instability in the ring chromosome contributes

to the variable phenotypes observed⁴.

Although the phenotypic spectrum of r(22) is broad and can range from mild to severe^{2,7,8}, carriers of r(22) present with most features of 22q13.3 deletion syndrome^{2,3}. In both r(22) and 22q13.3 deletion syndrome, *SHANK3* is suggested to be the most likely candidate gene influencing neurobehavioral features³. *SHANK3* codes for a scaffolding protein that lies at the core of the postsynaptic density in glutamatergic synapses.

The 22q13.3 deletion syndrome (or Phelan-McDermid syndrome) typically results from the loss of the distal long arm of chromosome 22. This may result from simple deletions, an unbalanced translocation, or other structural rearrangements involving chromosome 22⁹. Major clinical features include neonatal hypotonia, moderate to severe intellectual impairment, severe delayed or absent expressive language, normal to accelerated growth, autism-associated characteristics, and minor dysmorphic features⁹. Generally speaking, individuals with the 22q13.3 deletion syndrome have no life threatening organic malformations.

Carriers of r(22) may also present with the features of neurofibromatosis type 2-associated tumors such as vestibular schwannomas, multiple meningiomas, and neurofibromas. In these cases, the pathogenesis of these tumors was explained by the loss of both alleles of the *NF2* gene (neurofibromin 2), a tumor suppressor gene located on chromosome 22q12.2^{10,11}. Although the *NF2* gene was usually intact within the ring, the ring itself was prone to loss during somatic mitosis, and a pathogenic mutation at the *NF2* gene on the remaining chromosome was thought to result in tumor development^{10,11}.

SMARCB1 (*INI1/hSNF5*) is a tumor suppressor gene located on 22q11.2, proximal to the *NF2* gene. In the majority of AT/RT cases, genetic alterations affecting the *SMARCB1* (*INI1*/

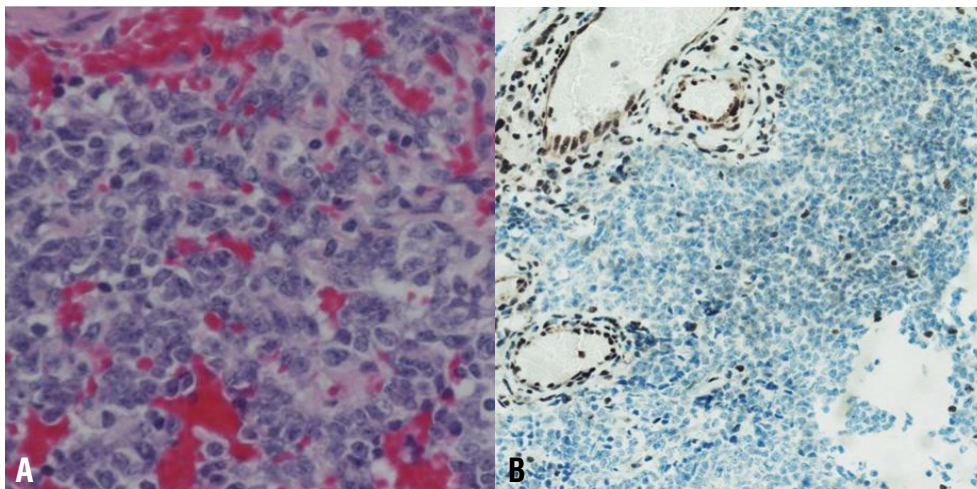


Fig. 4. (A) Histologic picture showing small cells with some cytoplasm and vesicular nuclei (H&E, $\times 400$). (B) Results of immunohistochemical staining indicating the loss of *SMARCB1* (*INI1/hSNF5*) expression in neoplastic cells (IHC, $\times 100$).

hSNF5) include homozygous deletions, heterozygous deletions as well as copy-number neutral loss of heterozygosity and mutations affecting each of all nine exons of *SMARCB1*⁶. Immunohistochemistry using an antibody directed against *SMARCB1* has evolved as a convenient first line diagnostic tool for the diagnosis of ATRT. This is especially relevant in small biopsy specimens, where rhabdoid tumor cells can be missed⁶.

In the past, CNS ATRTs were often misclassified as a medulloblastoma, primitive neuroectodermal tumors, or a different malignant brain tumor, because of their clinical, histological, and radiographic similarities^{6,12,13}. However, they are separated from other embryonal tumors by the presence of rhabdoid cells and specific immunohistochemistry^{6,13}.

The coexistence of a CNS ATRT in a child with an r(22) is rare. A previous case reported a CNS ATRT in a 4-year-old girl with r(22)¹⁴. In addition, a 2-year-old girl with 22q13.3 deletion syndrome and a CNS ATRT was reported¹⁵. In this case, although the array comparative genomic hybridization analysis of the patient's blood revealed only a *de novo* subtelomeric 7.2-Mb deletion of chromosome 22q13.2-q13.33, the results from the frozen tumor tissue demonstrated an acquired somatic frameshift mutation of the *INI1* gene and the loss of the *de novo* germline 22q13 deleted chromosome¹⁵. The net effect was the homogeneous inactivation of the *INI1* gene, leading to the development of the ATRT¹⁵.

Although we could not perform a genetic analysis of the tumor in our patient, we think that the ATRT may have resulted from the combined loss of the r(22) and a pathogenic *INI1* mutation on the remaining chromosome 22. Therefore, monitoring for not only neurofibromatosis type 2-associated tumors, but also for ATRTs should be performed in all carriers with an r(22).

The familial transmission of r(22) from a normal woman to her clinically affected daughter was also reported. The benign r(22) in a parent may undergo further rearrangements not only during mitosis, but also during meiosis to produce an unbalanced chromosome associated with developmental abnormalities². Therefore, both the gene deletion associated with ring formation, and the secondary genetic imbalance, should be considered.

Conflict of interest

No potential conflict of interest relevant to this article was reported.

References

1. Jobanputra V, Ash E, Anyane-Yeboah K, Warburton D, Levy B. Changes in an inherited ring (22) due to meiotic recombination? Implications for genetic counseling. *Am J Med Genet A* 2009; 149A:1310-4.
2. Jeffries AR, Curran S, Elmslie F, Sharma A, Wenger S, Hummel M, et al. Molecular and phenotypic characterization of ring chromosome 22. *Am J Med Genet A* 2005;137:139-47.
3. Luciani JJ, de Mas P, Depetris D, Mignon-Ravix C, Bottani A, Prieur M, et al. Telomeric 22q13 deletions resulting from rings, simple deletions, and translocations: cytogenetic, molecular, and clinical analyses of 32 new observations. *J Med Genet* 2003;40:690-6.
4. Guilherme RS, Meloni VF, Kim CA, Pellegrino R, Takeno SS, Spinner NB, et al. Mechanisms of ring chromosome formation, ring instability and clinical consequences. *BMC Med Genet* 2011;12:171.
5. Tommerup N, Lothe R. Constitutional ring chromosomes and tumour suppressor genes. *J Med Genet* 1992;29:879-82.
6. Pfister SM, Korshunov A, Kool M, Hasselblatt M, Eberhart C, Taylor MD. Molecular diagnostics of CNS embryonal tumors. *Acta Neuropathol* 2010;120:553-66.
7. Hannachi H, Mougou S, Benabdallah I, Soayh N, Kahloul N, Gaddour N, et al. Molecular and phenotypic characterization of ring chromosome 22 in two unrelated patients. *Cytogenet Genome Res* 2013;140:1-11.
8. Zuccarello D, Dallapiccola B, Novelli A, Foresta C. Azoospermia in a man with a constitutional ring 22 chromosome. *Eur J Med Genet* 2010;53:389-91.
9. Phelan K, McDermid HE. The 22q13.3 Deletion Syndrome (Phelan-McDermid Syndrome). *Mol Syndromol* 2012;2:186-201.
10. Denayer E, Brems H, de Cock P, Evans GD, Van Calenberg F, Bowers N, et al. Pathogenesis of vestibular schwannoma in ring chromosome 22. *BMC Med Genet* 2009;10:97.
11. Zirn B, Arning L, Bartels I, Shoukier M, Hoffjan S, Neubauer B, et al. Ring chromosome 22 and neurofibromatosis type II: proof of two-hit model for the loss of the NF2 gene in the development of meningioma. *Clin Genet* 2012;81:82-7.
12. Burger PC, Yu IT, Tihan T, Friedman HS, Strother DR, Kepner JL, et al. Atypical teratoid/rhabdoid tumor of the central nervous system: a highly malignant tumor of infancy and childhood frequently mistaken for medulloblastoma: a Pediatric Oncology Group study. *Am J Surg Pathol* 1998;22:1083-92.
13. Ginn KF, Gajjar A. Atypical teratoid rhabdoid tumor: current therapy and future directions. *Front Oncol* 2012;2:114.
14. Rubio A. March 1997: 4 year old girl with ring chromosome 22 and brain tumor. *Brain Pathol* 1997;7:1027-8.
15. Sathyamoorthi S, Morales J, Bermudez J, McBride L, Luquette M, McGoe R, et al. Array analysis and molecular studies of INI1 in an infant with deletion 22q13 (Phelan-McDermid syndrome) and atypical teratoid/rhabdoid tumor. *Am J Med Genet A* 2009; 149A:1067-9.