

## RESEARCH ARTICLE

# Histopathological Diversity in Parotidectomy Materials in Turkish Population: Clinicopathologic Analysis and Demographic Features of 136 Cases in a Tertiary Care Hospital

Serdar Altınay<sup>1\*</sup>, Umit Taskın<sup>2</sup>, Mehmet Sar<sup>3</sup>, Salih Aydın<sup>2</sup>, Mehmet Faruk Oktay<sup>2</sup>

### Abstract

**Background:** Salivary gland tumours, which account for approximately 3% of head-neck cancers, are a heterogeneous group and thus it is difficult to identify their epidemiological characteristics. The aim of this study is to determine demographic features and histopathologic distribution of parotid neoplasms in a large sample from Turkey. **Materials and Methods:** This study was conducted retrospectively on 136 parotidectomy materials from operations between May 2009-May 2013. Age, gender, tumor diameter, histopathological diagnosis and surgical margin status were recorded. **Results:** The benign cases were 112 (82.4%), while the malignancies were 24 (17.6%). The accuracy rate of FNAC was 91%. There were 46 (33.8%) male and 90 (66.2%) female patients. Female/male ratio (M/F=0.5) was two, the Warthin (WT) tumor being more apparent in males ( $p < 0.05$ ). Pleomorphic adenoma (PA) was detected most frequently among benign pathologies at 61.6% (69/112), while the Warthin Tumor (WT) was detected as the second most frequent tumor at 20.5% (23/112). Mucoepidermoid carcinoma (MEC) and carcinoma ex pleomorphic adenoma (Ca ex PA) were detected at equal frequency at 20.8% (5/24) among malign tumors. These were followed by acinic cell carcinoma at 16.7% (4/24). While the surgical margin was positive in ten patients with malignant tumors (41.7%), all of the benign tumors were negative ( $p < 0.01$ ). No significant difference was detected in the age-gender of patients, tumor size and distribution of sites among benign and malignant groups ( $p > 0.05$ ). **Conclusions:** Pleomorphic adenoma is the most frequently reported benign tumor almost in all global literature. Yet, the distribution of malignant tumors displays geographical differences. Based on these data, we believe that our findings will provide a significant contribution to future epidemiological studies. We think that it will be beneficial to generate awareness on parotid tumors and ensure a fight against smoking as with all head-neck cancers.

**Keywords:** Salivary gland - parotid - tumors - epidemiology - Turkish population

*Asian Pac J Cancer Prev*, 15 (14), 5701-5707

### Introduction

Salivary gland tumors constitute 3-10% of neoplasms in the head & neck region. The largest share of 80% is held by the tumors localized at the parotid. About 80-85% of parotid tumors, which display a wide histopathological variety, are benign and the most prevalent type of neoplasia is pleomorphic adenoma (PA) with 60-80%, followed immediately by the Warthin tumor (WT) with 10-20%. Mucoepidermoid carcinoma (MEC) is the most prevalent malignant tumor histology (Spiro, 1986; Barnes et al., 2005; Ellis and Auclair, 2008). Although the etiological factors in the cancers of the head-neck region are not clearly known, ionized radiation, sunlight, smoking, alcohol intake and chemotherapy are highlighted (Maasland et al., 2014).

These tumors have similar histological characteristics

leading to difficulties in diagnosis but also have different biological behavior which results in a therapeutic challenge. More extensive information can be obtained about parotid gland masses via assessment techniques such as fine needle aspiration biopsy (FNAB) which began to be utilized on a routine basis recently, computerized tomography (CT) and magnetic resonance imaging (MRI), and thus therapeutic methods may be determined more appropriately (Salgarelli et al., 2009).

The distribution of parotid tumors differs according to the centers and various geographical regions within the same country. Histopathological subtypes in the studies relating to the epidemiology of parotid tumors in our country were reported at various rates (Sungur et al., 2002; Gunizi and Guney, 2013; Kizil et al., 2013). In this study, we aimed to share and discuss the defining characteristics of parotid masses operated in the Ear-Nose-Throat and

<sup>1</sup>Department of Pathology, <sup>2</sup>Department of Ear-Nose-Throat Surgery, Bağcılar Training and Research Hospital, <sup>3</sup>Department of Pathology, Bakırköy Dr. Sadi Konuk Training and Research Hospital, Istanbul, Turkey \*For correspondence: drserdara@yahoo.com

Head & Neck Surgery Clinic of our hospital and evaluated in the Pathology laboratory, along with national and international literature data.

### Materials and Methods

This study was conducted on 136 patients assessed and operated in the ENT Clinic of the Training and Research Hospital of Bağcılar between May 2009 - May 2013 and evaluated in the pathology laboratory. Our institution is one of the biggest reference center and largest population centers located in Istanbul. Written informed consent was received prior to the operation from all patients.

Following the Physical Examination (PE), Ultrasonography (USG), Magnetic Resonance Imaging (MRI) or Computerized Tomography (CT) and Fine Needle Aspiration Biopsy (FNAB) was applied on patients with mass complaints. Superficial parotidectomy was applied on pathologies involving the superficial lobe, while total parotidectomy operation was performed on pathologies involving the deep lobe. All operations were conducted by the same surgical team. Radical parotidectomy+neck dissection was performed in malignant lesions and/or lesions suspected to be malignant. The histopathologic analyses of all cases were meticulously evaluated by expert pathologists. Reporting of malignant tumors was made in accordance with the 2005 classification of the World Health Organization (WHO). Those reported as histopathologically malignant were referred to the oncology and radiation oncology departments for treatment. The age, gender, type of surgery, tumor size, pathological diagnosis were analyzed retrospectively from the archive records.

#### Statistical analysis

The statistical analysis was performed in the SPSS 21.0 program. The distribution of data was assessed with the Kolmogorov-Smirnov test and median, standard deviation, rate and frequency values were used in descriptive statistics. The independent Samples T-Test and the Mann-Whitney U Test were utilized in the analysis of quantitative data. The Chi-Square Test and the Fischer Test were used in the qualitative data. The value  $p < 0.05$  was regarded significant.

### Results

Out of the 136 patients we evaluated in total, 124 (91%) resulted to be compliant with the FNAC diagnosis. The accuracy rate of FNAC was 91%. According to the preoperative cytology results, superficial parotidectomy was performed on 108 patients (79.4%), while total parotidectomy was performed on 18 patients (13.2%) and total parotidectomy+neck dissection was conducted on 10 patients (7.4%). Forty-six patients were male (33.8%), while 90 patients were female (66.2%). The mean age was  $48 \pm 15$  (8-83), while the mean lesion diameter was  $2.7 \pm 1.2$  (1.3-13 cm). Twenty-four (17.6%) malignant and 112 (82.4%) benign pathologies were detected in the histopathological assessment. About 79.5% of benign lesions were localized in the superficial lobe, while

only 29.2% of malignant tumors were localized in the superficial lobe. Likewise, 20.5% of benign pathologies were localized in the deep lobe, while 70.8% of malignant tumors were localized in the deep lobe ( $p=0.355$ ). The descriptive characteristics pertaining to groups were summarized in Table 1 and Figure 1. The most frequently reported finding in the clinical anamnesis was asymptomatic painless swelling.

Facial paralysis developed preoperatively in three patients; two were Grade II in House-Brackman, while one was Grade III intraoperative surgical repair was not performed on these patients. The surgical margin in 10 patients (41.7%) among malignant tumors was positive, while it was negative in 14 patients (58.3%). The surgical margin was negative in all patients among benign tumors ( $p=0.000$ ). In the assessment of the right-left localization of tumors, left-sided localization was higher in the malignant group ( $p=0.031$ ) (Table 1 and Figure 2). Patients' age-gender, tumor size and localization site distribution did not differ significantly between the benign and malignant groups ( $p > 0.05$ ).

#### Benign pathologies

In benign pathologies the ratio of female to male was M/F=0.55 (40/72), mean age was 48 years (8-83) and the mean lesion diameter was 2.6 cm (1.7-4). Most prevalent neoplasm among benign pathologies was Pleomorphic adenoma (61.6%), whereas Warthin tumor was the second

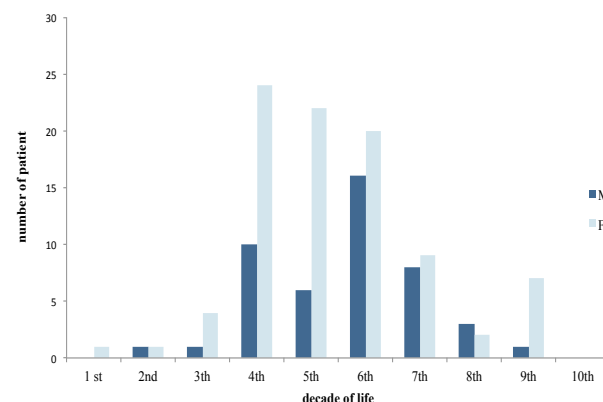


Figure 1. Age Distribution of Parotidectomy Materials in Turkish Population

Table 1. Distribution of Benign and Malign Pathologies According to Age, Gender, Tumor Diameter, Place, Location and Surgical Margin

		Pathology		p
		Benign No. %	Malign No. %	
Gender	Male	40 (32.8%)	6 (25.0%)	0.314
	Female	72 (59.0%)	18 (75.0%)	
Age (Mean±SD)/Med (Min-Max)		48.1±14.9/49 (8-83)	51.4±15.6/47 (31-82)	0.324
Tumor diameter (Mean±SD)/Med (Min-Max)		2.6±0.4/2.5 (1.7-4)	3.6±2.5/2.9 (1.3-13)	0.115
Place	Superficial	89 (79.5%)	17 (70.8%)	0.355
	Deep	23 (20.5%)	7 (29.2%)	
Location	Right	50 (44.6%)	5 (20.8%)	0.031
	Left	62 (55.4%)	19 (79.2%)	
Margin	Negative	112 (100.0%)	14 (58.3%)	0.000
	Positive	0 (0.0%)	10 (41.7%)	

most prevalent (20.5%).

*i) Pleomorphic adenoma:* Pleomorphic adenoma was the most prevalent tumor in both genders and occurred at a rate of 50% and 68%, in male and female respectively (M/F=0.4). The mean age of male was 45.9 years, while it was 44.6 years in female; the mean tumor diameter was 2.6 cm in male, while it was 2.5 cm in female.

*ii) Warthin tumor:* Warthin tumor was 2<sup>nd</sup> most prevalent tumor in both genders (20.5%); it was 37.5% in male and 11.1% in female (M/F=1.9). It was significantly higher in male compared to female ( $p<0.05$ ). Its mean incidence was 52.2 in male, while it was 45.9 in female. The mean tumor diameter was 2.6 cm in male and 2.7 cm in female.

Consequently, the number of basal cell adenomas was 5 (4.4%), the number of reactive hyperplasia was 4 (3.6%), the number of lymphoepithelial cysts was 3 (2.7%), the number of myoepitheliomas was 2 (1.8%), the number of lipomas was 2 (1.8%), the number of sialadenitis was 2 (1.8%), the number of oncocytomas was 1 (0.9%) and the number of granulomatous lymphadenitis was 1 (0.9%). The distribution of benign pathologies was provided in detail in Table 2.

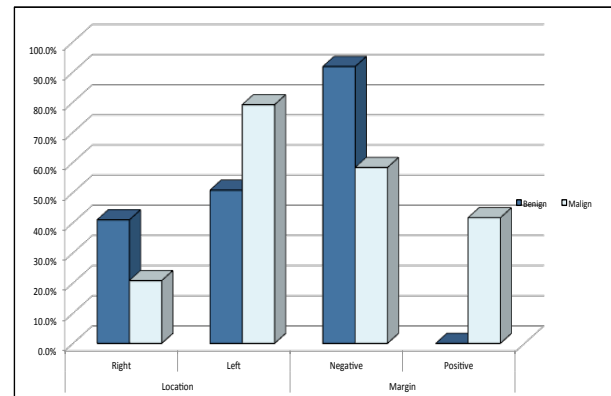
#### Malignant pathologies

The ratio of female to male was M/F=0.33 (6/18) in malignant tumors, the mean age was 51.4 years (31-82), while the mean tumor diameter was 3.6 cm (1.3-13). The incidence of mucoepidermoid carcinoma (MEC) and

Carcinoma ex pleomorphic adenoma (CXPA) was equal among the malignant tumors in both genders (20.83%). This was immediately followed by Acinic cell carcinoma (ACC; 16.7%).

Within the distribution of malignant tumors, MEC (22.2%) was most frequent, followed by CXPA (16.6%) and ACC (16.6%) among female. The mean age of prevalence and tumor diameter was 36.5/2.2 cm for MEC, 38.6/3 cm CXPA and 60.7/3.7 cm for ACC.

CXPA (33.3%) and Squamous cell carcinoma (SqCC); 33.3%) had an equal incidence in the distribution of malignant tumors among male. MEC (16.7%) and ACC



**Figure 2. Distribution of Benign and Malign Pathologies According to Tumor Location and Status of Surgical Margin**

**Table 2. Distribution of Benign Parotid Pathologies According to Age and Tumor Diameter in Both Genders**

Histopathology (Benign)	N		%	Age range	Mean age±SD	Tumor size (cm)	Mean size±SD
	Female	Male					
Pleomorphic adenoma	49	20	61.6	8-83	44.98±14.64	2.0-4	2.51±0.45
Whartin's tumor	8	15	20.5	27-66	50.04±12.19	2.0-3.5	2.61±0.44
Bazal cell adenoma	5		4.4	46-81	73.6±15.43	2.3-3	2.86±0.31
Reactive lymphoid hyperplasia	3	1	3.6	45-53	47.5±3.59	2.3-2.8	2.5±0.21
Lymphoepithelial cyst	2	1	2.7	47-66	59.0±10.44	2.0-2.7	2.4±0.36
Lipoma		2	1.8	33-79	56.0±32.52	1.7-2.2	1.95±0.35
Sialadenitis	2		1.8	48-83	50.5±3.53	2.5-3	2.75±0.35
Myoepithelioma	2		1.8	45-50	47.50±3.53	2.0-2.5	2.25±0.35
Oncosytoma		1	0.9	42	42.0±0	2.7	2.7±0
Granulomatous lymphadenitis	1		0.9	49	49.0±0	2.5	2.5±0
Total (112)	72	40	100	8-83	48.07±14.90	1.7-4	2.53±0.43

**Table 3. Distribution of Malign Parotid Pathologies According to Age and Tumor Diameter in Both Genders**

Histopathology (Malign)	N		%	Age range	Mean age±SD	Tumor size (cm)	Mean size±SD
	Female	Male					
Mucoepidermoid carcinoma	4	1	20.83	31-68	42.8±14.73	1.3-3.5	2.16±0.88
Carcinoma ex pleomorphic adenoma	3	2	20.83	37-61	46.0±10.53	1.4-5	3.48±1.49
Asinic cell carcinoma	3	1	16.66	33-80	53.75±21.42	2.0-4.5	3.3±1.38
Epithelial-myoepithelial carcinoma	2		8.33	45-59	52.0±9.89	2.1-4.3	3.2±1.55
Squamous cell carcinoma		2	8.33	72-82	77.0±7.07	4.0-6.5	5.25±1.76
Diffuse large cell lymphoma	2		8.33	38-64	51.0±18.38	2.8-13	7.9±7.21
Myoepithelial carcinoma	1		4.16	51	51.0±0	2.3	2.3±0
Adenoid cystic carcinoma	1		4.16	49	49.0±0	3	3.0±0
Salivary duct carcinoma	1		4.16	73	73.0±0	6.5	6.5±0
Small cell carcinoma	1		4.16	42	42.0±0	1.5	1.5±0
Total (24)	18	6	100	31-82	51.41±15.58	1.3-13	3.64±2.49

**Table 4. Examples of Previous Studies from Different Countries**

Study	Country	Patient Number	M/F	M/B (%)	Most benign (%)	Most malign (%)
Sungur et al., 2002	Turkey	230	-	17.0/83	PA (79,1)	AdCC (44,7)
Kızıl et al., 2013	Turkey	372	1.16	21.5/78.5	PA (60,3)	MEC (20)
Günizi and Güney, 2013	Turkey	130	0.94	20.5/79.5	WT (30,8)	Adeno ca NOS (15)
					PA (58,5)	MEC (21,8)
					WT (30,5)	Sq.CC (21,8)
Present	Turkey	136	0.51	17.6/82.4	PA (61,6)	Lymphoma (21,8)
					WT (20,5)	MECK (20,8)
						CXPA (20,8)
Wargas et al., 2002	Brazil	88	-	17.0/83	PA (79,4)	ACC(16,7)
					WT (17,8)	MEC (60)
Ali et al., 2010	Pakistani	112	1.15	26.0/74	PA (78)	CXPA (20)
					WT (12)	MEC (60)
						AdCC (10)
Lee et al., 2012	Korea	171	1.25	11.7/88.3	PA (61,6)	ACC (10)
					WT (13,2)	Sq.CC (30)
Lima et al., 2005**	Brazil	126				MEC (25)
						MEK (31,7)
						Adeno ca NOS (14,3)
						ACC (14,3)
Kawata et al., 2012***	Japan	300	1.06		PA (49)	
					WT (37)	

\*M/B; Malign/Benign; \*\*Only including malignant parotid tumors; \*\*\*Only including benign parotid tumors

(16.7%) were at the same rate. The mean age of prevalence and tumor diameter was 57/4.3 cm for CXPA, 77/5.3 cm for SqCC, 68/2 cm for MEC and 33/2.2 cm for ACC (The detailed of malignant pathologies is provided in Table 3).

## Discussion

This paper describes the most demographic characteristics of 136 parotid neoplasms from Turkey to date in English literature. In our study, in which we assessed 136 patients, 82.4% of parotid tumors were benign while 17.6% were malignant. These rates were in line with 83% benign and 17% malignant rates reported from Turkey in a wide series comprising 230 cases in our country (Sungur et al., 2002). The benign/malign ratios were reported as 78.5/21.5 (Kızıl et al., 2013) and 79.5/20.5 (Gunizi and Güney, 2013) in the previous studies. On the other hand the results of researchers outside our country were as follows: in the salivary gland series where 88 had parotid within the Brazilian population (Vargas et al., 2002), they detected 83% benign and 17% malignant parotid tumors. In the 271-patient study conducted in Taiwan (Lin et al., 2008), 85% were benign and 12% were malignant and 3% constituted chronic inflammatory pathologies. In a 112-patient series in Pakistan (Ali et al., 2010), 74% were benign and 26% were malignant, while in a 171-patient series in Korea (Lee et al., 2012), 88.3% were benign 11.7% were malignant (Table 4). The Benign/Malignant (B/M) ratio in our series was 4.7. In the recently conducted salivary gland study comprising 210 patients, they identified that the Benign/Malignant ratio was B/M=4 and recorded that this ratio was 1.1 in Africa, while it increased up to 5.6 in Europe among salivary gland tumors (Jaafari-Ashkavandi et al., 2013).

There is no marked gender prevalence in parotid tumors. In addition to the study displaying a ratio of female to male as M/F=0,9 among 963 cases (Guintinas-Lichius et al., 2006), there is also a publication reporting a ratio of

female to male as M/F=1.4 among 237 patients in literature (Upton et al., 2007). We observed a predominance of female both in benign (M/F=0,6) and malignant (M/F=0,3) parotid masses in our study (in total; M/F=0.5). While the number of female patients was higher (M/F=0.94) in some studies (Gunizi and Güney, 2013), the number of male patients was prevalent in others (Sungur et al., 2002; Kızıl et al., 2013). Likewise the number of male patients was higher (M/F=1.25) compared to that of female patients in Korea (Lee et al., 2012) and (M/F=1.15) in Pakistan (Ali et al., 2012). There were marked differences in the distribution of malignant tumors according to gender. The investigators noted a prevalence of men in Brazil, Finland, India and Iran, while there was a prevalence of women in Jordan and Sri Lanka (Jaafari-Ashkavandi et al., 2013).

It is known that parotid tumors occur mostly between the ages 30-70 years, with a mean age of 46 years in benign tumors and of 47 years in malignant tumors (Ellis and Auclair, 2008). In the assessment of the histopathological diagnoses in our study, we noticed that the mean age for benign tumors was 49 years, while the mean age for malignant tumors was 51 years. The age interval in both genders was 8-83 years, while the mean age was 48 years. Similarly, authors reported the age interval as 15-81 years and the mean age was 47.2 years (Gunizi and Güney, 2013) and 47.6 years (Kızıl et al., 2013). We noted that malignant tumors occurred in women at a mean age of 48 years, while they occurred at a more advanced age as 62 years in men. Maybe this was due to the higher smoking rate among our male patients.

It was demonstrated that 70-78.8% of parotid masses were localized in the superficial lobe, while 19.1-22.2% were localized in the deep lobe (Lin et al., 2008). We detected the superficial lobe, localization at 77.9% and the deep lobe localization at 22.1% in our study, in line with literature values. About 79.5% of benign pathologies were superficial lobe localized, while 29.2% of malignant pathologies were deep and 70.8% were superficial lobe

localized.

In the cytological assessment, 8 among benign lesions were reported as false negative, while 4 lesions among malignant lesions were reported as false positive. The accuracy rate of FNAC was 91%. The accuracy rates for parotid lesions the cytological assessment of which are slightly more challenging were reported to be up to 97% (Salgarelli et al., 2009; Ali et al., 2012; Nguansangiam et al., 2012).

Pleomorphic adenoma is the most prevalent benign tumor in major and minor salivary glands and is mostly positioned in the 5th decade (Spiro, 1986; Barnes et al., 2005; Ellis and Auclair, 2008). We observed in our study that pleomorphic adenomas occurred at a mean age of 45.9 years in male and 44.6 years in female. The mean age in both genders was 45 years, and consistent with the literature. About 60-90% of benign parotid tumors is composed of pleomorphic adenomas. Considering the studies conducted in our country, the PA rate was reported as 79.1% (Sungur et al., 2002), 60.3% (Kizil et al., 2013) and as 58.5% (Gunizi and Guney, 2013). The PA rates; reported from Brazil (Vargas et al., 2002) was 79.4%, from Taiwan (Lin et al., 2008) was 51%, from Pakistan (Ali et al., 2010) was 78%, from Korea (Lee et al., 2012) was 61.6%, from Japan (Kawata et al., 2012) was 49%. In our study, 68.5% of benign pathologies in female and 50% in male was PA. We detected a PA rate of 61.6% in both genders.

Warthin tumor is reported as the 2<sup>nd</sup> most prevalent among benign tumors in the parotid. Although it appears at varying rates in almost all national and international studies, Warthin tumor is ranked in the second position. The rate of Warthin tumor was reported as 30.8% (Kizil et al., 2013) and 30.5% (Gunizi and Guney, 2013) by Turkish researchers. The rate of WT was reported as 12% (Ali et al., 2010), 13.2% (Lee et al., 2012), 17.8% (Vargas et al., 2002) and 37% (Kawata et al., 2012) by other authors. We detected a WT rate of 37.5% in male and 11.1% in female. This rate could be related to smoking habits, which are the mean etiological factor for this particular neoplasia. In line with Brazil literature (Vargas et al., 2002), we detected a WT rate of 20.5% ranked in the second position in terms of prevalence in both genders. Although a bilaterality of 20% were reported, we did not encounter any.

Basal cell adenomas (BCAs) included into the monomorphic adenoma group, constitute 2% of salivary gland tumors (Ellis and Auclair, 2008). BCAs ranked in the 3<sup>rd</sup> position with 4.4% among our patients, were reported as the 3<sup>rd</sup> most prevalent with 1.4% from Brazil (Vargas et al., 2002).

Painful swellings with sudden onset in the parotid gland generally indicate inflammatory pathologies. However, the increase in the size of a long-existing mass may also be due to inflammation and cystic degeneration. Considering reactive hyperplasia, chronic sialadenitis and granulomatous inflammation among our subjects, there were 7 patients in total. All of our patients resorted to the ENT clinic with the complaint of rapidly growing swelling. Surgery was applied on subjects not responding to medical therapy.

Approximately 15-30% of parotid gland tumors are

composed of malignant tumors (Spiro, 1986; Barnes et al., 2005; Ellis and Auclair, 2008). This rate varies between 17-21.5% in the studies conducted in our country. The malignancy rates were reported as 17% (Sungur et al., 2002), 21.5% (Kizil et al., 2013), 20.5% (Gunizi and Guney, 2013) and by Turkish authors. The malignancy rates were reported as 17%, 12%, 26% and 11.7% by other authors (respectively; Vargas et al., 2002; Lin et al., 2008; Ali et al., 2010; Lee et al., 2012). In our study, we detected a malignancy rate of 17.6% among all parotid tumors.

Mucoepidermoid carcinoma (MEC) is the most prevalent type of tumor among malignant tumors. This is followed by adenocarcinoma (NOS), acinic cell carcinoma (ACC) and Adenoid cystic carcinoma (AdCC) (Spiro, 1986; Wahlberg et al., 2002; Barnes et al., 2005; Ellis and Auclair, 2008). In our series, MEC was the most prevalent type of tumor among women (22.2%), while it ranked in the second position among men (16.7%). MEC and CXPA had an equal prevalence in both genders (20.8%). In addition to studies demonstrating MEC as the most prevalent tumor in literature there were also investigators who found different results. The rates reporting MEC as the 1<sup>st</sup> most prevalent tumor among series were 60% (Vargas et al., 2002), 31.7% (Lima et al., 2005), 60% (Ali et al., 2010), and 20% (Kizil et al., 2013), and 43% (Iqbal et al., 2014). Some authors (Gunizi and Guney, 2013) reported the MEC frequency at an equal rate with SqCC (21.8%), while other authors (Lee et al., 2012) reported it as the 2<sup>nd</sup> most prevalent tumor with 25% after SqCCa. MEC was the tumor most frequently reported in the Brazilian, Libyan and Chinese populations, while adenoid cystic carcinoma was the 2<sup>nd</sup> most frequently reported tumor after MEC in India, Africa and Bratislava (Jaafari-Ashkavandi et al., 2013).

Carcinoma ex Pleomorphic Adenoma (CXPA) is distinguished from malignant mixed tumors due to its malignant epithelial component and occurs at a prevalence of 1.5-12% among salivary gland tumors (Lima et al., 2005; Ellis and Auclair, 2008). Adenocarcinoma was detected as a malignant component in all of our patients. The researchers indicated that 25% of 28 patients with CXPA were previously operated due to PA (Nouraei et al., 2005). PA had not developed previously in any of our cases.

In our series in which we could make a FNAB diagnosis in two patients, it had an equal prevalence with malignant parotid tumors; there were 5 CXPA cases (20.8%) in total where 3 were in female and 2 were in male. Brazilian authors published a total of 3 patients (20%) among all malignancies in their series of 88 patients (Vargas et al., 2002). Likewise, Pakistani authors reported 3 patients (10%) among all malignancies in their series of 112 patients (Ali et al., 2010).

Acinic cell carcinoma (ACC) constitutes nearly 3% of all parotid tumors (Spiro, 1986; Ellis and Auclair, 2008). This tumor group claimed to derive from the acinar cells of the salivary gland or the reserve cells of intercalary ducts. We could not diagnose in only one patient in FNAB materials. In our study, 4 patients in total, 3 female (aged 40, 62, 80 years) and one male (33 years) with ACC were confirmed in the parotidectomy material. This number

corresponded to 16.7% within 2.9% in 136 patients. The rate of ACC was detected as 13.6% (Yılmaz et al., 2000) and 8.7% by Turkish authors (Gunizi and Guney, 2013). Whereas this rate was detected as 14.3% in Brazil study (Lima et al., 2005).

Epithelial myoepithelial carcinomas (EMC) constitute 2% of parotid tumors; F/M=2/1 and they are mostly prevalent in the 6th and 7th decades (Spiro, 1986; Ellis and Auclair, 2008). In our study we detected EMC in only two female patients (aged 45 and 59 years). This constituted 1.5% of all parotid tumors and 8.3% of malignant tumors. There was one patient in the series from Brazil (Vargas et al., 2002) and it constituted 6.7% of malignant tumors.

Primary squamous cell carcinomas (SqCCs) are rarely seen in the parotid gland. They constitute 0.1-3.4% of all parotid tumors (Flynn et al., 1999). It should be ensured that there is no association with the skin in order to exclude the possibility of metastasis. We detected SqCC not associated with the skin in two male patients (aged 72 and 82 years). This corresponded to 1.5% of all parotid tumors and 8.3% of malignant tumors. Interestingly, authors from Turkey (Gunizi and Guney, 2013) published that they detected SqCC at a rate of 21.8% among malignant tumors, while this rate was detected as 30% by Korean authors (Lee et al., 2012).

Lymphoma is a tumor rarely prevalent in the parotid gland, mostly seen in men in the form of Non-Hodgkin Lymphoma (NHL). It constitutes 0.2-0.8% of all parotid tumors. Researchers from Netherlands indicated that they detected lymphoma (38%) in 7 patients among 18 malignant parotid tumors (von Strizky et al., 1998). We detected diffuse large B-cell lymphoma in two patients aged 38 and 64 years. This rate was 1.5% among all tumors and 8.3% among malignant tumors. Similarly Pakistani authors reported only one (3.3%) case of lymphoma among 30 malignant parotid tumors (Ali et al., 2010).

There was one Myoepithelial carcinoma, one Ad CC, one salivary duct carcinoma and one small cell carcinoma among more rarely observed parotid tumors. Interestingly, authors from Brazil reported ACC as the 4th most prevalent among malignant parotid tumors (Lima et al., 2005). Yet, Turkish authors published ACC as the most prevalent among malignant tumors with 44.7% (Sungur et al., 2002).

Parotid surgery may lead to severe complications due to the facial nerves involved. Therefore, it necessitates a rather meticulous preoperative preparation both from the clinical and radiological perspectives. The most conservative approach in benign tumors involving the superficial section of parotid is superficial parotidectomy, while this is total parotidectomy in tumors involving the deep lobe. We applied superficial parotidectomy in 79.4% (108), total parotidectomy in 13.2% (18) and total parotidectomy+neck dissection in 7.4% (10) of our patients. Preoperative facial paralysis developed in 3 patients (12.5%) diagnosed with malignant tumors. Authors reported the rate of facial paralysis among malignant tumors as 12-14% (Spiro, 1986) and 18.7% (Ali et al., 2010), 21.7% (Gunizi and Guney, 2013).

We did not find a meaningful correlation between the tumor size diameter distribution of benign and malignant

tumors. However, we noted that the tumor diameters in two of our three patients with facial paralysis were 4 cm and 6.5 cm and that all three were localized in the deep lobe. Researchers demonstrated that there was an increase in facial paralysis development incidence in tumors of 4 cm or larger. Likewise, they also published that the facial paralysis development incidence in tumors localized in the deep lobe was higher than tumors localized in the superficial lobe (Watanabe et al., 1993). Another point which drew our attention was the fact that malignant tumors were localized mostly in the left lobe. We may state that this condition for which we found no correspondence in literature, maybe a malignancy potential in patients with left parotid masses in our country.

In conclusion, we have seen in our study that the distribution of benign tumors was compliant with literature comprising Eastern and Western countries according to age and gender. PA was invariably ranked first among benign parotid tumors, while WT was ranked as the 2<sup>nd</sup> most prevalent. However, the distribution of malignant tumors was highly variable both in the studies conducted in our country and in international publications. MEC was ranked as the first most prevalent tumor in some publications, while a few tumors shared the first position in other publications.

The characteristic features of parotid tumors display incompliance among countries. Maybe, geographic distribution and ethnic factors impact the clinicopathologic profile of ethnic factors. Certainly, some challenges may be faced in their typing and grading due to their mixed histopathological appearance. FNAB carries importance in preoperative assessment and in directing therapy and places a major responsibility of pathologists.

We believe that it will be beneficial to generate awareness on parotid tumors, in which patients mostly complain of painless swelling and which may give rise to facial paralysis in future periods, and ensure a fight against smoking as with all head-neck cancers.

## Acknowledgements

It is not used any funding for the present work. We would like to thank Ertan Koc for his valuable contribution to the statistical assessment, and all the staff and personnel of ENT clinic and Pathology Laboratory.

## References

- Ali NS, Nawaz A, Rajput S, Ikram M (2012). Parotidectomy: a review of 112 patients treated at a teaching hospital in Pakistan. *Asian Pac J Cancer Prev*, **11**, 1111-3.
- Barnes L, Eveson JW, Reichart P, Sidransky D (2005). WHO Classification of Tumours. Pathology&Genetics of Head and Neck Tumours. In "Salivary Glands", eds Eveson JW, Auclair P, Gnepp DR, El-Naggar AK. IARC Press, Lyon, 209-281.
- Ellis GL, Auclair PL (2008). Tumors of the salivary glands. (AFIP Atlas of Tumor Pathology: Series 4) 4<sup>th</sup> ed. American Registry of Pathology, Washington.
- Flynn MB, Maguire S, Martinez S, Tesmer T (1999). Primary squamous cell carcinoma of the parotid gland: the importance of correct histological diagnosis. *Ann Surg Oncol*, **6**, 768-70.

- Guintinas-Lichius O, Klussmann JP, Wittekindt C, Stennert E (2006). Parotidectomy for benign parotid disease at a university teaching hospital: outcome of 963 operations. *Laryngoscope*, **116**, 534-40.
- Gunizi H, Guney K (2013). Our surgical approach to parotid masses: an analysis of 130 patients. *Kulak Burun Bogaz Ihtis Derg*, **23**, 85-9.
- Iqbal H, Bhatti AB, Hussain R, Jamshed A (2014). Ten year experience with surgery and radiation in the management of malignant major salivary gland tumors. *Asian Pac J Cancer Prev*, **15**, 2195-9.
- Jaafari-Ashkavandi Z, Ashraf MJ, Moshaverinia M (2013). Salivary gland tumors: a clinicopathologic study of 366 cases in southern Iran. *Asian Pac J Cancer Prev*, **14**, 27-30.
- Kawata R, Lee K, Yoshimura K, Nishimawa S, Araki M (2012). Review of 300 cases of parotidectomy for benign parotid tumors. *Nihon Jibiinkoka Gakkai Kaiho*, **115**, 618-24.
- Kizil Y, Aydil U, Ekinci O, et al (2013). Salivary gland tumors in Turkey: demographic features and histopathological distribution of 510 patients. *Indian J Otolaryngol Head Neck Surg*, **65**, 112-20.
- Lee YM, Choi HJ, Kim JW, Kim JH (2012). Parotid gland tumors in a Korean population. *J Craniofac Surg*, **23**, 205-9.
- Lima RA, Tavares MR, Dias FL, et al (2005). Clinical prognostic factors in malignant parotid gland tumors. *Otolaryngol Head Neck Surg*, **133**, 702-8.
- Lin CC, Tsai MH, Huang CC, et al (2008). Parotid tumors: a 10-year experience. *Am J Otolaryngology-Head&Neck Med and Surg*, **29**, 94-100.
- Maasland DH, van den Brandt PA, Kremer B, Goldbohm RA, Schouten LJ (2014). Alcohol consumption, cigarette smoking and the risk of subtypes of head-neck cancer: results from the Netherlands Cohort Study. *BMC Cancer*, **14**, 187.
- Nouraei SA, Hope KL, Kelly CG, McLean NR, Soames JV (2005). Carcinoma ex benign pleomorphic adenoma of the parotid gland. *Plast Reconstr Surg*, **116**, 1206-13.
- Nguansangiam S, Jesdapatarakul S, Dhanarak N, Sosrisakorn K (2012). Accuracy of fine needle aspiration cytology of salivary gland lesions: routine diagnostic experience in Bangkok, Thailand. *Asian Pac J Cancer Prev*, **13**, 1583-8.
- Salgarelli AC, Cappare P, Bellini P, et al (2009). Usefulness of fine-needle aspiration in parotid diagnostics. *Oral Maxillofac Surg*, **13**, 185-90.
- Spiro RH (1986). Salivary neoplasms. Overview of a 35-year experience with 2807 patients. *Head Neck Surg*, **8**, 177-84.
- Sungur N, Akan IM, Ulusoy MG, et al (2002). Clinicopathological evaluation of parotid gland tumors: a retrospective study. *J Craniofac Surg*, **13**, 26-30.
- Upton DC, McNamar JP, Connor NP, Harari PM, Hartig GK (2007). Parotidectomy: ten-year review of 237 cases at a single institution. *Otolaryngol Head Neck Surg*, **136**, 788-92.
- Vargas PA, Gerhard R, Araújo Filho VJ, de Castro IV (2002). Salivary gland tumors in a Brazilian population: a retrospective study of 124 cases. *Rev Hosp Clin Fac Med Sao Paulo*, **57**, 271-6.
- von Stritzky M, Wereldsma JC, Pegels JG (1998). Parotid mass as first symptom of a malignant lymphoma. *J Surg Oncol*, **67**, 25-7.
- Wahlberg P, Anderson H, Biörklund A, Möller T, Perfekt R (2002). Carcinoma of the parotid and submandibular glands - a study of survival in 2465 patients. *Oral Oncol*, **38**, 706-13.
- Watanabe Y, Ishikawa M, Hojaku H, Mizukoshi K (1993). Facial nerve palsy as a complication of parotid gland surgery and its prevention. *Acta Otolaryngologica*, **504**, 137-9.