

## RESEARCH ARTICLE

# Utility of Nuclear Morphometry in Effusion Cytology

Marie Moses Ambroise\*, Prabhavati Jothilingam, Anita Ramdas

### Abstract

**Background:** The cytological analysis of serous effusions is a common investigation and yields important diagnostic information. However, the distinction of reactive mesothelial cells from malignant cells can sometimes be difficult for the cytopathologist. Hence cost-effective ancillary methods are essential to enhance the accuracy of cytological diagnosis. The aim of this study was to examine the utility of nuclear morphometry in differentiating reactive mesothelial cells from malignant cells in effusion smears. **Materials and Methods:** Sixty effusion smears consisting of 30 effusions cytologically classified as malignant (adenocarcinomas) and 30 benign effusions showing reactive mesothelial cells were included in the study. ImageJ was used to measure the nuclear area, perimeter, maximal feret diameter, minimal feret diameter and the circularity. A total of ten representative cells were studied in each case. **Results:** Significant differences were found between benign and malignant effusions for the nuclear area, perimeter, maximal feret diameter and minimal feret diameter. No significant difference was found for circularity, a shape descriptor. Receiver operating characteristic (ROC) curve analysis revealed that nuclear area, perimeter, maximal feret diameter, and minimal feret diameter are helpful in discriminating benign and malignant effusions. **Conclusions:** Computerised nuclear morphometry is a helpful ancillary technique to distinguish benign and malignant effusions. ImageJ is an excellent cost effective tool with potential diagnostic utility in effusion cytology.

**Keywords:** Image cytometry - Image processing - nucleus - morphometry - cytology

*Asian Pac J Cancer Prev*, **15** (16), 6919-6922

### Introduction

An effusion denotes pathological accumulation of fluids in the serous cavities resulting from several non-neoplastic and neoplastic causes. Cytological diagnosis of effusion fluids is an important investigation to determine the appropriate treatment. The distinction of reactive mesothelial cells from carcinoma cells can sometimes prove to be a diagnostic challenge even for the experienced cytopathologist. Hence there is an increasing need to develop cost-effective ancillary methods to enhance the accuracy of cytologic diagnosis (Murugan et al., 2009; Bunjhoo et al., 2012; Cheng et al., 2012; Liu et al., 2013; Yildirim et al., 2013; Wang et al., 2013; 2014). Image morphometry is one such ancillary technique and often requires expensive software and hardware for image acquisition and analysis. This limits its utility in routine practice. Hence a cost-effective alternative for image analysis is the need of the hour for pathologists and researchers in developing Asian countries. ImageJ is a freely available java-based public-domain image processing and analysis program developed at the National Institutes of Health (NIH), USA (Rasband, 1997-2014). ImageJ has proved to be an excellent cost effective tool and is being widely utilised for various research purposes. A number of nuclear morphometric and shape descriptors

can be evaluated as shown in this study.

The aim of the study is to examine the utility of nuclear morphometry in differentiating reactive mesothelial cells from malignant cells in effusion smears.

### Materials and Methods

Sixty effusion smears were selected from our archives. They included 30 effusions cytologically classified as malignant (adenocarcinomas) and 30 benign effusions showing reactive mesothelial cells. Clinical details, radiological investigations and/or histological confirmation were available in all the cases. Routine Leishman stained slides were photographed using an Olympus Bx 43 microscope (ocular lens 10× and objective 100×, oil immersion) equipped with an Olympus E-330 digital camera. Each image had a resolution of 4,190×3,096 pixels and was saved in a tagged image file format. A digital picture was obtained from ten different fields for each case. Ten representative nuclei (from ten different fields) were evaluated for each case. Only nuclei of non-overlapping well-preserved cells with sharp nuclear boundaries were chosen. An area or region of interest of the image can be selected using ImageJ. The representative nucleus in each image was outlined and analysed using ImageJ 1.46r.

Department of Pathology, Pondicherry Institute of Medical Sciences (PIMS), Ganapathichettikullam, Kalapet, Puducherry, India  
\*For correspondence: [drmosesa@yahoo.com](mailto:drmosesa@yahoo.com)

**Table 1. Mean, SD and Median Values for Nuclear Area, Perimeter, Maximal Feret Diameter, Minimal Feret Diameter and Circularity**

	Benign		Malignant		p value
	Mean±SD	Median	Mean±SD	Median	
Nuclear area ( $\mu\text{m}^2$ )	57.4±21.5	59.2	144.5±87.9	125.7	<0.001
Nuclear perimeter( $\mu\text{m}$ )	28.1±6.1	29.1	44.2±10.6	42.1	<0.001
Maximal feret Diameter( $\mu\text{m}$ )	9.6±2.1	9.9	15.2±3.5	14.6	<0.001
Minimal feret diameter ( $\mu\text{m}$ )	7.7±1.7	7.9	11.9±3.2	11.4	<0.001
Circularity	0.88±0.1	0.88	0.87±0.1	0.88	0.681

For each nucleus, ImageJ was used to measure the nuclear area, perimeter, maximal feret diameter, minimal feret diameter and the circularity. The nuclear area (the area of selection) was measured in calibrated square units ( $\mu\text{m}^2$ ). The perimeter denotes the length of the nuclear contour (the length of the outside boundary of the selection) and is expressed in  $\mu\text{m}$ . The maximal feret diameter also known as the maximum caliper diameter represents the maximum extension of the nucleus. It is the longest distance between any two points along the selection boundary. ImageJ uses the heading feret for maximal caliper diameter. The minimal feret diameter also known as the minimum caliper diameter (MinFeret in ImageJ) represents the minimum extension of the nucleus. Circularity is a shape descriptor. A value of 1.0 indicates a perfect circle and as the value approaches 0.0, it indicates an increasingly elongated shape. In ImageJ, the formula for circularity is  $4\pi \times [\text{Area}]/[\text{Perimeter}]^2$ .

#### Statistical analysis

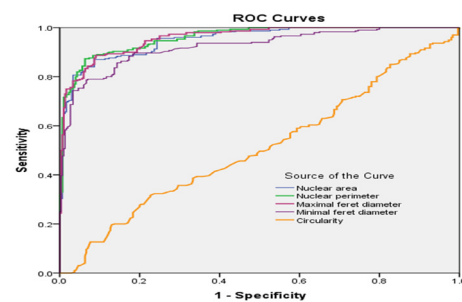
The mean, standard deviation (SD) and median of various parameters were analysed. Comparisons between two groups (benign and malignant effusions) were performed using the non-parametric Mann-Whitney's U-test. The diagnostic ability of various parameters to predict malignant effusion was assessed using Receiver Operating Characteristic (ROC) curves analysis. The ROC plots the true positive rate (sensitivity) against the false-positive rate (1-specificity). Overall diagnostic value is given by the area under the curve (AUC). A perfectly accurate test would yield a ROC of 1.0 and a ROC of 0.5 indicates a predictive efficacy no better than chance. A p value less than 0.05 was considered statistically significant for all tests. Data processing and analysis were performed using SPSS for Windows (Version 20.0.0).

## Results

The mean, SD and median values of nuclear area, perimeter, maximal feret diameter, minimal feret diameter and circularity are shown in Table 1. There were significant differences between the nuclear area, perimeter, maximal feret diameter and minimal feret diameter of benign and malignant effusions. No significant difference was found for circularity, a shape descriptor. The ROC curve analysis shown in Table 2 reveals that nuclear area, perimeter, maximal feret diameter, and minimal feret diameter are helpful in discriminating adenocarcinoma cells from reactive mesothelial cells. The ROC curves are shown in figure 1. The best cut-off point for nuclear area was found

**Table 2. ROC Curve Analysis of Nuclear Area, Perimeter, Maximal Feret Diameter, Minimal Feret Diameter and Circularity**

	Area under curve (AUC)	Standard error (SE)	p value	95%CI
Nuclear Area	0.95	0.01	<0.001	0.94-0.97
Nuclear perimeter	0.96	0.01	<0.001	0.95-0.97
Maximal feret diameter	0.96	0.01	<0.001	0.95-0.97
Minimal feret diameter	0.92	0.01	<0.001	0.90-0.94
Circularity	0.51	0.02	0.681	0.46-0.56

**Figure 1. ROC Curves of Nuclear Area, Nuclear Perimeter, Maximal Feret Diameter, Minimal Feret Diameter and Circularity for Identification of Malignant Effusion**

to be 76.1, with a sensitivity of 88.0% and a specificity of 86.0%. A cut-off point of 33.2 for nuclear perimeter provided a sensitivity of 89.3% and specificity of 88.0%. Similarly a cut-off point of 11.4 for maximal feret diameter yielded a sensitivity of 89.3% and specificity of 88.0%. A cut-off point of 8.9 for minimal feret diameter yielded a sensitivity of 88.0% and specificity of 82.7%.

## Discussion

The cytological analysis of serous effusions is a commonly performed investigation. Various types of cells like inflammatory cells, mesothelial cells and malignant cells accumulate in serous effusions depending upon the underlying pathology. One of the diagnostic challenges for a cytopathologist in evaluating body cavity fluids is to distinguish reactive mesothelial cells from metastatic adenocarcinoma cells. Reactive mesothelial cells are almost always found in serous effusions and can sometimes exhibit atypical features thereby mimicking malignant cells. Conversely carcinoma cells sometimes have a bland appearance.

It is not always possible for a cytopathologist to

accurately classify the nature of the cells solely based on conventional cytomorphological features. Hence various ancillary techniques like immunocytochemistry, tumor markers, image morphometry, flow cytometry and others are being evaluated (Murugan et al., 2009; Krishan et al., 2010; Bunjhoo et al., 2012; Cheng et al., 2012; Kundu et al., 2012; Liu et al., 2013; Yildirim et al., 2013; Wang et al., 2013; 2014). Computerised image analysis can estimate various parameters of the cells. However it has not gained popularity because it often requires complicated and costly hardware and software which are not user friendly for the cytopathologist in developing nations. In contrast ImageJ software, a public domain, Java-based image processing program developed at the National Institutes of Health (NIH) is freely downloadable, easy to install and can be handled with ease by pathologists and researchers. The present study shows the application of this cost-effective software in the morphometric diagnosis of serous effusions.

Previous studies have also evaluated the utility of image cytometry in differentiating reactive mesothelial cells and malignant cells in body fluids. Athanassiadou et al measured two nuclear morphometric variables (nuclear major axis length and nuclear area) by a computerized image analysis system (Athanassiadou et al., 2002). The results showed that image cytometry can provide important information to differentiate atypical mesothelial cells from malignant adenocarcinoma cells in effusion smears. Arora et al also analysed the role of computerized-interactive morphometric analysis and found mean nuclear area and Nuclear/Cytoplasmic ratio to be very useful parameters in differentiating various cells in effusion cytology (Arora et al., 2006).

In the present study we used nuclear area, nuclear perimeter, maximal feret diameter, minimal feret diameter and circularity to assess the utility of image analysis in effusion cytology. Nuclear area was found to be a useful parameter similar to previous studies. Nuclear perimeter, maximal feret diameter and minimal feret diameter were also found to be excellent parameters in effusion cytology. The shape descriptor circularity did not differ significantly between reactive mesothelial cells and malignant cells. ROC curve analysis demonstrated the practical utility of image analysis. These sensitive and specific parameters can be measured quickly and correlated with the overall cytological picture in routine practice.

Computerised image analysis has other applications in effusion cytology also. Studies have also evaluated the utility of fractal dimensions in effusion cytology (Bhatia et al., 2009; Sharma et al., 2010). Recently artificial neural network has been used to detect metastatic carcinoma cells in effusion cytology (Barwad et al., 2012).

Computerised nuclear morphometry is proving to be a useful ancillary diagnostic tool in evaluation of FNA cytology also. Abadalla et al showed that interactive computerized nuclear cytomorphometry is an effective tool in distinguishing between cases of benign and malignant breast disease. Five different size parameters and six shape factors were measured. The size parameters (especially mean nuclear area) showed significant differences between benign and malignant cases. Interestingly the shape

parameters did not help in the distinction (Abadalla et al., 2008). Kalhan et al showed that nuclear morphometry is a useful objective tool to differentiate between benign and malignant aspirates of breast lesions and also correlated significantly with cytologic grade (Kalhan et al., 2010). Mean nuclear area, long axis, short axis and total run length proved to be useful parameters in the study. Similar to the previous study by Abadalla et al, the nuclear shape parameter did not differ significantly. Shape parameters seem to be less useful in image cytometry. Another recent South Indian study used ImageJ software and showed that nuclear morphometry is a helpful tool in differentiating aspirates of benign and the malignant breast lesions (Narasimha et al., 2013).

Wen et al found nuclear area and perimeter to be useful diagnostic criteria in distinguishing hepatocytes with regenerative atypia from well differentiated hepatocellular carcinoma cells in liver fine needle aspiration cytology (Wen et al., 2009). Quantitative cytomorphometric analysis has also proved to be a useful tool in the cytological differentiation between benign and malignant parotid gland tumors (Obad-Kovacevic et al., 2013). Quantitative assessment of cytological nuclear features can play an important role in preoperative assessment and complement morphological features in thyroid lesions (Priya and Sundaram, 2011). Cytomorphometry in oral smears is proving to be a useful adjunct in the early diagnosis of oral cancer (Khandelwal et al., 2010).

In conclusion, computerised nuclear morphometry can serve as a sensitive and specific tool to distinguish reactive mesothelial cells from adenocarcinoma cells in effusion cytology. ImageJ is a powerful open-source software with potential diagnostic utility in effusion cytology.

## References

- Athanassiadou P, Kavantzias N, Davaris P, et al (2002). Diagnostic approach of effusion cytology using computerized image analysis. *J Exp Clin Cancer Res*, **21**, 49-56.
- Arora B, Setia S, Rekhi B (2006). Role of computerized morphometric analysis in diagnosis of effusion specimens. *Diagn Cytopathol*, **34**, 670-5.
- Abdalla F, Boder J, Buhmeida A, et al (2008). Nuclear morphometry in FNABs of breast disease in Libyans. *Anticancer Res*, **28**, 3985-9.
- Bhatia A, Eckka RS, Dey P (2009). Fractal dimensions of reactive mesothelial cells and malignant cells in ascitic fluid cytology. *Anal Quant Cytol Histol*, **31**, 353-4.
- Bunjhoo H, Wang ZY, Chen HL, et al (2012). Diagnostic value of interleukin 21 and carcinoembryonic antigen levels in malignant pleural effusions. *Asian Pac J Cancer Prev*, **13**, 3495-9.
- Barwad A, Dey P, Susheilia S (2012). Artificial neural network in diagnosis of metastatic carcinoma in effusion cytology. *Cytometry B Clin Cytom*, **82**, 107-11.
- Cheng D, Liang B, Li YH (2012). Application of MMP-7 and MMP-10 in assisting the diagnosis of malignant pleural effusion. *Asian Pac J Cancer Prev*, **13**, 505-9.
- Kalhan S, Dubey S, Sharma S, et al (2010). Significance of nuclear morphometry in cytological aspirates of breast masses. *J Cytol*, **27**, 16-21.
- Khandelwal S, Solomon MC (2010). Cytomorphological analysis of keratinocytes in oral smears from tobacco users

- and oral squamous cell carcinoma lesions-a histochemical approach. *Int J Oral Sci*, **2**, 45-52.
- Krishan A, Ganjei-Azar P, Hamelik R, et al (2010). Flow immunocytochemistry of marker expression in cells from body cavity fluids. *Cytometry A*, **77**, 132-43.
- Kundu R, Handa U, Mohan H (2012). Role of DNA flow cytometry and immunocytochemical analysis in diagnosis of malignant effusions. *Diagn Cytopathol*, **40**, 887-92.
- Liu YL, Jing LL, Guo QS (2013). Clinical impact and reliability of carbonic anhydrase XII in the differentiation of malignant and tuberculous pleural effusions. *Asian Pac J Cancer Prev*, **14**, 351-4.
- Murugan P, Siddaraju N, Habeebullah S, Basu D (2009). Immunohistochemical distinction between mesothelial and adenocarcinoma cells in serous effusions: a combination panel-based approach with a brief review of the literature. *Indian J Pathol Microbiol*, **52**, 175-81.
- NarasimhaA ,Vasavi B, Kumar HML (2013). Significance of nuclear morphometry in benign and malignant breast aspirates. *Int J Appl Basic Med Res*, **3**, 22-6.
- Obad-Kovacevic D, Kardum-Skelin I, Jelic-Puskaric B, Vidjak V, Blaskovic D (2013). Parotid gland tumors: correlation between routine cytology and cytomorphometry by digital image analysis using conventional and newly introduced cytomorphometric parameters. *Diagn Cytopathol*, **41**,776-84.
- Priya SS, Sundaram S (2011). Morphology to morphometry in cytological evaluation of thyroid lesions. *J Cytol*, **28**,98-102.
- Rasband WS. ImageJ. U. S. National Institutes of Health, Bethesda, Maryland, USA.
- Sharma N, Dey P (2010). Fractal dimension of cell clusters in effusion cytology. *Diagn Cytopathol*, **38**, 866-8.
- Wen CH, Huang MS, Wang SL, et al (2009). Diagnostic value of computerized nuclear morphometry for the prediction of malignancy in liver fine needle aspiration cytology. *Acta Cytol*, **53**, 77-82.
- Wang XF, Wu YH, Jiao J, et al (2013). Diagnostic value of superoxide dismutase in tuberculous and malignant pleural effusions. *Asian Pac J Cancer Prev*, **14**, 821-4.
- Wang XF, Wu YH, Wang MS, Wang YS (2014). CEA, AFP, CA125, CA153 and CA199 in malignant pleural effusions predict the cause. *Asian Pac J Cancer Prev*, **15**, 363-8.
- Yildirim M, Suren D, Yildiz M, et al (2013). Tumour markers in peritoneal washing fluid - contribution to cytology. *Asian Pac J Cancer Prev*, **14**, 1027-30.